

# SCRIPTA MEDICA

FACULTATIS MEDICAE UNIVERSITATIS BRUNENSIS MASARYKIANAE  
SPISY LÉKAŘSKÉ FAKULTY MASARYKOVY UNIVERZITY V BRNĚ

---

Tomus 80 (2007)

Fasciculus 1-2

---

**DEDICATED TO THE 20th ANNIVERSARY OF THE FOUNDATION OF  
THE DEPARTMENT OF PAEDIATRIC OPHTHALMOLOGY,  
FACULTY OF MEDICINE, MASARYK UNIVERSITY IN BRNO**

## C o n t e n t s

### O p h t h a l m o l o g y

- 3**            **Optic Neuritis in Paediatric Patiens – Clinical Manifestations, Etiology, Therapy, and Visual Outcomes in a Long-Term Follow-Up**  
Autrata R., Helmanová I., Pyrochtová S., Ošlejšková H.,  
Vondráček P., Skotáková J.
- 17**           **Trabeculectomy with Adjunctive Intraoperative Use of Mitomycin in the Treatment of Paediatric Glaucoma**  
Helmanová I., Autrata R., Pirochtová S., Řehůřek J.
- 29**           **Safety and Efficacy of Travoprost Adjunctive Treatment in Paediatric Glaucoma**  
Helmanová I., Autrata R., Šenková K., Řehůřek J.
- 37**           **Combination of Laser Photocoagulation and Cryotherapy for Threshold Retinopathy of Prematurity during One Surgical Procedure**  
Šenková K., Autrata R., Holoušová M., Řehůřek J.
- 45**           **Congenital Brown's Syndrome: Surgical Outcomes of Silicone Expanders for Superior Oblique *Tendon***  
Autrata R., Vodičková K., Šenková K., Pellarová H., Řehůřek J.
- 53**           **Long-Term Surgical Outcomes of the Secondary IOL Implantation in Children**  
Autrata R., Pyrochotová S., Helmanová I., Lokaj M., Řehůřek J.

- 63**            **AcrySof Intraocular Lens Primary Implantation in Children with Congenital and Developmental Cataract**  
Pyrochotvá S., Autrata R., Lokaj M., Řehůřek J.
- 71**            **Results of Surgery in Duane´s Retraction Syndrome: Comparison of Unilateral Recession and Resection versus Bilateral Medial Rectus Recession**  
Vodičková K., Autrata R., Šenková K., Řehůřek J., Pellarová H.

## OPTIC NEURITIS IN PAEDIATRIC PATIENTS – CLINICAL MANIFESTATIONS, ETIOLOGY, THERAPY, AND VISUAL OUTCOMES IN A LONG-TERM FOLLOW-UP

AUTRATA R.<sup>1</sup>, HELMANOVÁ I.<sup>1</sup>, PYROCHTOVÁ S.<sup>1</sup>, OŠLEJŠKOVÁ H.<sup>2</sup>,  
VONDŘÁČEK P.<sup>2</sup>, SKOTÁKOVÁ J.<sup>3</sup>

<sup>1</sup>Department of Paediatric Ophthalmology, Masaryk University Hospital, Brno

<sup>2</sup>Department of Paediatric Neurology, Masaryk University Hospital, Brno

<sup>3</sup>Department of Paediatric Radiology, Masaryk University Hospital, Brno

### Abstract

The aim of the study was to analyse the clinical manifestations, etiology, management, and long term visual results in children with optic neuritis. We evaluated the presenting features, associated systemic disease, cerebrospinal fluid abnormalities, neuroimaging findings, and visual outcome.

The retrospective study involved consecutive pediatric patients with optic neuritis treated in our university clinic during a 10-year period between January 1995 and January 2005. Forty-three pediatric patients (69 eyes) with the mean age 11.6 years (range: 4 to 18 years) were included in the study. The mean follow-up was 4.7 years. The degree of initial visual loss, defects of visual field and colour vision, abnormalities of visual evoked potentials, subsequent visual recovery, associated diseases and etiology, MRI and cerebrospinal fluid analysis were evaluated. The effects of high-dose methylprednisolone and/or intravenous immunoglobulin were reviewed.

Twenty-six patients (63 %) had bilateral optic neuritis, and 17 patients (37 %) had unilateral disease. Fifty-one of 69 eyes (74 %) had a visual acuity of 20/200 or less at the first clinical presentation. Thirty-eight of 43 patients (88 %) were given intravenous methylprednisolone (10 to 40 mg/kg/day). 48 of 69 eyes (70 %) recovered visual acuity 20/40 or better, Sixteen of 69 eyes (21 %) in a range of 20/50 to 20/125, and five of 69 eyes (7 %) recovered a vision of 20/200 or less. No etiology was found in 14 children (33 %), 29 patients had systemic disease (10 had acute disseminated encephalomyelitis (ADEM), 8 multiple sclerosis, 5 juvenile rheumatoid arthritis, and 6 sinusitis). All the patients underwent MRI of the brain. A normal MRI of the brain was associated with a visual recovery of 20/40 or better in 12 of 14 affected children. Thirty-one children were in the range of 8–18 years of age and 12 were younger at manifestation of optic neuritis. Fifteen of 31 (48 %) older children and 10 of 12 (83 %) younger patients had bilateral disease. Nine of 10 children ADEM-treated with intravenous steroids and immunoglobulin recovered with a visual acuity of 20/40 or better. Visual evoked potentials (VEP) in acute phase were abnormal in 47 of 52 (91 %) affected eyes in bilateral cases and 17 eyes (100 %) of monolateral ON. At the final follow-up, complete VEP recovery occurred in 41 of 64 eyes (64 %) with initially abnormal VEP.

Optic neuritis in our children was associated with a high recovery rate of all clinical parameters and good visual recovery, but 28 % of affected eyes remain visually disabled. Patients younger than 7 years of age are more likely to have bilateral disease and a more favourable visual outcome than older children. Intravenous corticosteroids followed by tapered oral steroids were the effective treatment.

Younger age at presentation and a normal-appearing MRI of the brain may be associated with a better visual prognosis.

## Key words

Optic neuritis, Children, Visual acuity, Visual evoked potentials

## Abbreviation used

VEP, visual evoked potential; ON, optic neuritis; VA, visual acuity; RAPD, relative afferent pupillary defect; MRI, magnetic resonance imaging; CSF, cerebrospinal fluid; MS, multiple sclerosis

## INTRODUCTION

Childhood optic neuritis (ON) is rare, but significant because of its presentation and the importance of differential diagnosis. It probably occurs throughout childhood, but is rarely recognized in toddlers because any visual defect has to be very profound and bilateral before the child is obviously abnormal for the parents. The most frequent age at presentation is 7 years; it probably occurs with equal sex distribution. Recovery of vision in childhood optic neuritis tends to be rapid, with a good visual prognosis. However, like in adults, visual recovery can continue for several months (1-7). *Brady et al.* (8), in a large series of pediatric patients with optic neuritis, reported the majority of cases associated with complete visual recovery; however, a significant number (22 %) remain visually disabled. Attacks are frequently bilateral, follow a viral prodrome, and respond to steroids, but some patients may have significant visual loss (9). The etiology of childhood optic neuritis may be different from adults, more frequently an infectious or parainfectious syndrome is involved (10).

The clinical diagnosis of ON in children can be made after a thorough history and clinical examination – reduced visual acuity, positive relative afferent pupillary defect (RAPD), edema or hyperemia of the optic disc, visual field and colour vision defects.

Visual evoked potential (VEP) changes have been intensively studied in adult ON but not in children. During the acute phase of the illness, VEP's are often absent or markedly diminished because of low visual acuity. VEP latency remains delayed in 90 % of the affected eyes after the acute phase of ON (11). In the majority of affected eyes in adults, VEP latency does not return to normal values, or, if it does, it takes months or even years (12). Studies on electrophysiological changes in childhood ON are rare. There are three follow-up studies of children with ON showing that, after the acute phase of ON, VEP in children returns to normal more often than in adults (3,11,13,14).

The aim of the present study was to evaluate the clinical characteristics, etiology, visual outcome, electrophysiological and neuroimaging findings, and the efficacy of intravenous steroids in pediatric patients with optic neuritis systematically monitored for a year.

## PATIENTS AND METHODS

The records of all children who came to the Department of Pediatric Ophthalmology of Masaryk University Hospital from 1995 to 2005 with a diagnosis of optic neuritis were retrospectively reviewed. The clinical diagnosis of optic neuritis was made on the basis of visual loss, an afferent pupillary defect, and colour vision and visual field defect with or without optic nerve swelling. Patients with hereditary optic neuropathy, traumatic optic neuropathy, systemic vasculitis, and malignancy were excluded from the study. Optic neuritis was classified as unilateral or bilateral. Bilateral simultaneous disease was defined as both eyes being affected within 1 month of each other, and bilateral recurrent disease was defined as 1 or both eyes being affected more than once. Forty-three pediatric patients (69 eyes) with a mean age of 11.6 years (range: 4 to 18 years) were included in the study. The mean follow-up was 4.7 years (range: 1.2–11 years). Information regarding age, sex, clinical parameters (initial and final visual acuity (VA), RAPD, visual field and colour vision, optic disc appearance), VEP (P100 latency and amplitude), therapy, cerebrospinal fluid (CSF) findings, magnetic resonance imaging (MRI), and associated systemic disease was obtained. In young children who could not comply with Allen, E game, or Snellen VA testing, acuity was evaluated by the central, steady, and maintained fixation method. (15) In all cases, the recovered VA was the final VA. This was measured at an interval of 4 weeks to 60 months, with a mean of 23 months. A thorough ophthalmological examination was performed in all children with special emphasis on funduscopy. Visual fields were tested with a Goldmann perimeter or a Tubinger-automatik-perimeter (TAP 2000, Oculus, Germany). Hartz and Farnsworth hue 15 tests were performed to detect colour vision defects. Pupillary reactions were tested using the alternating light test. A PC-based visual evoked potential system Viking 4D NICOLET (Biomedical Inc, USA) was used. The VEP stimulus was a black and white checker-board pattern reversing at 1.9 Hz. Normal limits for P 100 amplitude and latency were set according to the values of a group of 50 age- and sex-matched, healthy children (aged 5–18 years, mean age 10.7 years).

Most patients underwent MRI of the brain. A spinal tap was performed to evaluate CSF features.

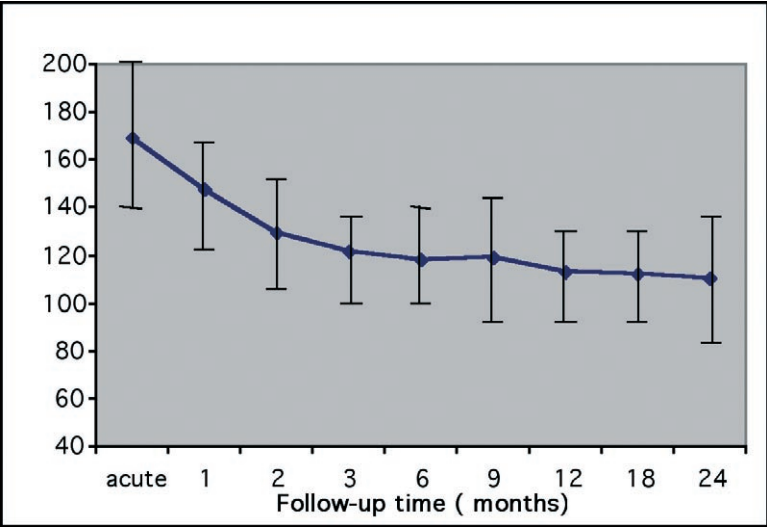
## RESULTS

Twenty-six patients (63 %) had bilateral optic neuritis, and 17 patients (37 %) had unilateral disease. Clinical parameters in both groups of our children with optic neuritis and statistical analysis are demonstrated in *Table 1*. The mean age at presentation was 8.9 years. There were 23 female patients (53 %) and 20 male patients (47 %). Sixty-nine eyes were affected in total, 26 of which belonged to the bilateral group and 17 to the unilateral group. Thirty-eight of 43 patients (88 %) underwent intravenous methylprednisolone therapy (10 to 40 mg/kg/day) for 3 to 8 days. This was followed by an oral taper over 1 month. The follow-up ranged from 1.2 to 11 years, with a mean of 4.7 years.

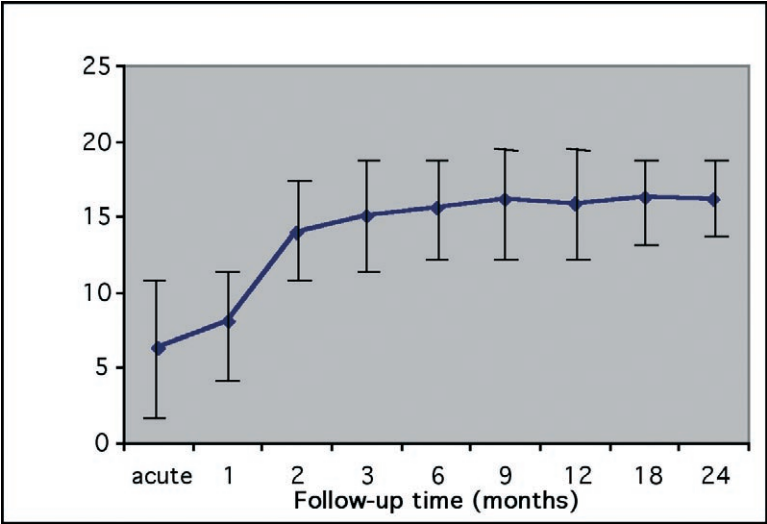
*Table 1*  
Clinical characteristics of 26 patients with bilateral optic neuritis (52 eyes)  
and 17 patients with monolateral optic neuritis

Parameters	Bilateral ON (n=52 eyes)	Monolateral ON (n=17 eyes)	P- Value
Mean age at presentation (range, years)	9.9 (4 – 16)	12.4 (5–18)	0.86 <sup>#</sup>
Gender (male/female)	11/15	9/8	
Mean follow-up (years)	5.3	4.2	0.913 <sup>*</sup>
<b>Initial visual acuity (number of eyes)</b>			
20/40 or better	0	0	
20/50 to 20/125	13	5	0.242 <sup>*</sup>
20/200 or worse	39	12	0.108 <sup>*</sup>
<b>Recovered visual acuity (number of eyes)</b>			
20/40 or better	36	12	0.151 <sup>*</sup>
20/50 to 20/125	12	4	0.217 <sup>*</sup>
20/200 or worse	4	1	0.364 <sup>*</sup>
<b>Therapy (number of patients)</b>			
Methylprednisolone (10–40 mg /kg/ day)	23	16	–
Antibiotics	11	9	–
<b>Electrophysiological findings (VEP) in acute phase (number of eyes)</b>			
Normal	5	0	0.978 <sup>#</sup>
Abnormal	47	17	0.615 <sup>#</sup>
<b>MRI findings (number of patients)</b>			
Optic nerve enhancement	7	4	0.832 <sup>#</sup>
White matter changes	22	8	0.243 <sup>#</sup>
Sinusitis	2	5	0.825 <sup>#</sup>
<b>CSF findings (number of patients)</b>			
Normal	11	5	0.879 <sup>#</sup>
Abnormal	15	7	0.641 <sup>#</sup>
<b>Optic neuritis classification (number of patients)</b>			
Bilateral simultaneous	19	–	–
Bilateral recurrent	7	–	–
<b>Systemic disease (number of patients)</b>			
None	9	5	–
ADEM	8	2	–
Devic disease	1	–	–
Multiple sclerosis	7	1	–
Sinusitis	1	7	–

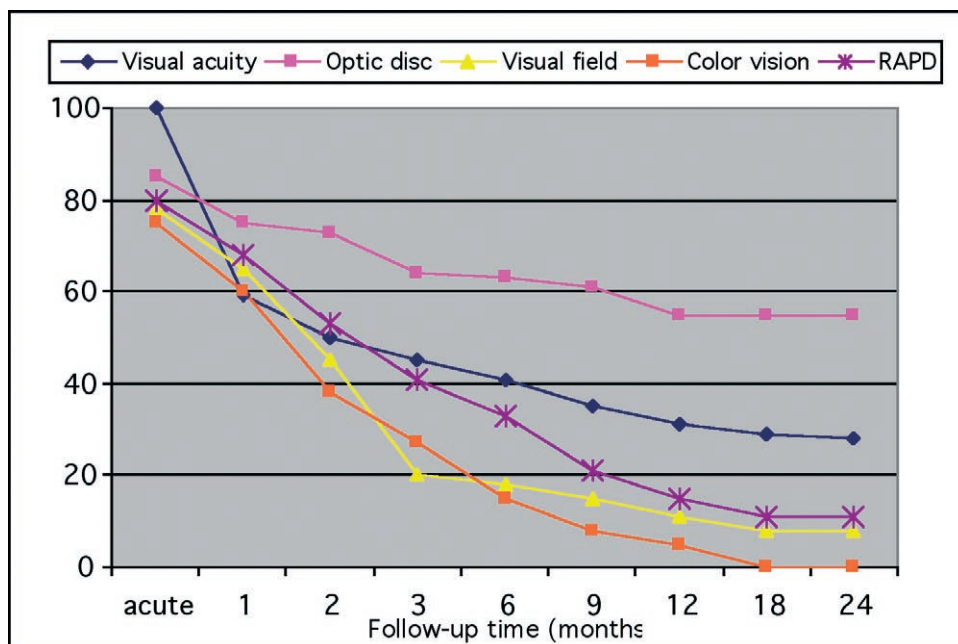
<sup>\*</sup> Chi-square test <sup>#</sup> Two-sample t test



*Fig. 1*  
Visual evoked potentials (VEP): P100 latency (ms) mean values  
at the acute phase and during follow-up.



*Fig. 2*  
Visual evoked potentials (VEP): P100 amplitude (µV) mean values  
at the acute phase and during follow-up.



*Fig. 3*  
Evaluation of changes in clinical parameters during 2 year follow-up after acute phase of optic neuritis in all 69 affected eyes (RAPD= relative afferent pupillary defect)

### ***Clinical findings and visual outcome***

Visual acuity was worse than 20/40 in all 69 affected eyes and 51 eyes (74 %) had VA of 20/200 or less in the initial examination during the acute phase of the illness. An abnormal appearance of the optic disc was present in 53 of 69 (76 %) affected eyes. The optic disc was mostly swollen and pale. Visual field defects and colour vision defects were present in 40 (75 %), and 46 (86 %) of 53 eyes, respectively, in the children who were able to perform the test. They were central or paracentral scotomas and non-specific large visual field defects. The relative afferent pupillary defect (RAPD) was positive in 57 of 69 (83 %) affected eyes.

At the final follow-up visual field and colour vision were normal in 92 % of eyes, pupillary reactions were normal in 89 % of the eyes. Optic disc appearance was abnormal in 38 eyes (55 %). Changes in clinical parameters during a 2-year follow-up after acute phase of optic neuritis in all 69 affected eyes are demonstrated in *Fig. 3*.

Patients with central, steady, and maintained fixation, who were too young to comply with Snellen VA testing, were included in the 20/40 or better group. Forty-eight of 69 affected eyes (72 %) achieved 20/40 VA or better. Sixteen of 69 eyes (21 %)



achieved VAs in the 20/50 to 20/100 range. Five of 69 eyes (7 %) attained 20/200 or less vision. *Table 1* demonstrates the conditions associated with optic neuritis. Of the 5 patients with poor visual outcome, 3 patients had multiple sclerosis (MS), 2 patients had optic neuritis with contiguous sinusitis.

Thirty-nine of 52 eyes (75 %) in the bilateral group achieved 20/40 VA or better. Twelve of 17 eyes (71 %) in the unilateral group achieved 20/40 VA or better. The visual outcome in unilateral versus bilateral optic neuritis using statistical analysis shows a result ( $X^2$ ,  $P=0.15$ ) that was not statistically significant.

### ***Electrophysiological parameters***

Electrophysiological examinations – visual evoked potentials (VEP) in the acute phase were abnormal in 47 of 52 (91 %) affected eyes in bilateral cases and 17 eyes (100 %) of monolateral ON. VEP abnormalities were seen as: absent P100 (28 % of eyes), P 100 attenuation (46 % of eyes), P 100 attenuation and delay (16 % of eyes), and P100 delay in 10 % of the affected eyes. At the final follow-up, complete VEP recovery occurred in 41 of 64 eyes (64 %) with initially abnormal VEP. In 23 eyes (36 %) VEP improvement is presented, but remained abnormal at the final follow-up. *Figs 1 and 2* document changes in the mean values of P100 latency and amplitude during a 2-year follow-up of all affected eyes.

### ***Age at presentation of optic neuritis***

A subgroup analysis was performed on the visual outcome in children 7 years of age or younger and those 7.1 years of age or older at presentation (*Table 2*). There were 12 patients who were 7 years of age or younger in the study. Ten (83 %) had bilateral disease, and 2 (17 %) had unilateral disease. Ten of these 12 patients (83 %) had ADEM. Nineteen of 22 affected eyes (86 %) achieved 20/40 VA or better. Thirty-one patients were 7.1 years of age or older. Sixteen of 31 (51 %) had bilateral disease, and 15 of 31 patients (49 %) had unilateral disease. Twenty-six of 47 affected eyes (55 %) achieved 20/40 VA or better. Statistical analysis between patient age and visual outcome demonstrated a trend towards improved visual outcome in patients younger than 7 years of age, and the result was statistically significant. ( $P=0.0349$ ).

*Table 2*  
Visual outcome and patient age at presentation

	≤7 years of age at presentation	≥7.1 years of age at presentation
No. of patients	12	31
Bilateral optic neuritis	10	16
Unilateral optic neuritis	2	15
Visual recovery of 20/40 or better	19 of 22 (86 %)	17 of 31 (55 %)

### ***Magnetic resonance imaging***

MRI of the brain was performed in 40 of 43 patients (93 %). Ten patients (25 %) had a normal-appearing MRI of the brain, and 11 patients had isolated optic nerve enhancement. Eight of 10 affected eyes (80 %) in patients with a normal-appearing MRI of the brain recovered 20/40 VA or better. Nine of 11 affected eyes (82 %) in patients with isolated optic nerve enhancement recovered 20/40 VA or better. Thirty patients (75 %) had abnormal MRI findings. These abnormalities included multiple white-matter changes, optic nerve enhancement if associated with white-matter changes, and sinusitis. Seven patients had optic neuritis associated with sphenothmoid sinusitis. One of 3 patients demonstrated enhancement of the posterior orbital contents on neuroimaging. Twenty-six of 48 affected eyes (54 %) in patients with abnormal MRI results achieved 20/40 VA or better. Statistical analysis of the final visual outcome between patients with abnormal MRI findings versus normal findings (including isolated optic nerve enhancement) using the  $X^2$  test demonstrated a better visual outcome in patients with a normal MRI of the brain, but no statistical significance ( $X^2 = 1.28$ ;  $.05 \geq P \leq .25$ ).

### ***Evaluation of CSF analysis***

CSF analysis was performed in 37 of 43 patients (86 %). Sixteen patients had normal CSF findings. Twenty-one of 29 affected eyes (72 %) achieved 20/40 VA or better. Twenty-one patients (32 affected eyes) had abnormal CSF findings. Twenty-five of 32 (78 %) affected eyes achieved 20/40 VA or better. Eleven specimens (30 %) had decreased protein. Fourteen specimens (38 %) were tested for oligoclonal bands. Five of the patients who were tested negative for oligoclonal bands had clinically definite MS. Seven patients had a positive CSF adenovirus culture associated with ADEM, and 2 patients demonstrated an Epstein-Barr virus nuclear antigen in the spinal fluid also in association with ADEM. Fourteen patients had a documented viral prodrome (8 with bilateral optic neuritis and 6 with unilateral optic neuritis). Seventeen of these 22 affected eyes (77 %) in this group achieved 20/40 VA or better. Twenty-nine patients did not have a documented viral prodrome, and 24 of 39 affected eyes (62 %) recovered 20/40 VA or better. Eight patients had clinically definite MS; 7 of these had bilateral optic neuritis. Nine of 15 affected eyes (60 %) had 20/40 VA or better.

## **DISCUSSION**

Optic neuritis in children is far less frequent than in adults. The mean age of onset is 9-10 years of age. Cases have been reported as young as 21 months, (8) though most are older than five years. There is no sex predilection in prepubescent children, and a 2: 1 female predominance after puberty. (7,8,18) Several studies have shown a seasonal predominance correlating with peak incidences in viral infections (7).

Parainfectious optic neuritis is the most common form and frequently associated with systemic infections such as adenovirus, measles, mumps, chickenpox, pertussis, mononucleosis, and Lyme disease. Morales et al. found that two thirds of patients had a history of antecedent viral illness prior to visual loss. (16) The virus is believed to activate a systemic autoimmune mechanism of demyelination. It may also occur following vaccinations, specifically measles, mumps, rubella, hepatitis B, tetanus, diphtheria, and smallpox. (17) A large case series found that patients younger than 14 years were more likely to have antecedent viral illnesses, whereas children older than 14 years often had a primary demyelinating optic neuritis related to underlying neurological disease, such as MS. (18)

#### VISUAL OUTCOME

Our paper represents a large group of patients with pediatric optic neuritis that describes clinical manifestations, electrophysiological findings, MRI of the brain, and therapy with intravenous methylprednisolone at doses comparable with those in the Optic Neuritis Treatment Trial (ONTT). (19) Profound initial vision loss has been reported to be more common in pediatric optic neuritis than in adult optic neuritis (7).

In our children, most of the eyes showed visual acuity decreased to 20/200 or less (74 % of affected eyes) at presentation. Brady et al., in their pediatric patients with ON, reported an initial visual acuity of 20/200 or worse in 85 % of affected eyes (8). In the majority of our children (72 % of eyes) visual acuity recovered completely, staying decreased in 28 % of the eyes at the final follow-up. Twenty-one eyes in our group of children had a poor visual outcome. Five of 69 affected eyes (7 %) achieved 20/200 VA or less. In addition, 16 of 69 eyes (21 %) achieved vision in the 20/50 to 20/125 range. Three of the patients with poor visual outcome had contiguous sinusitis and optic neuritis. This may represent a different disease entity with a different prognosis than idiopathic or demyelinating optic neuritis. Vascular compromise, compression, or inflammation of the optic nerve have all been implicated in optic neuritis associated with sinusitis (20,21).

The results are comparable with the study of Brady et al. (8) in which visual acuity did not return to normal in 22 % of affected eyes. Tekavčić-Pompe et al. (14) reported 14 % of affected eyes with markedly decreased visual acuity after a 1-year follow-up. Our visual results confirm the findings of previously published studies that optic neuritis in children generally has a relatively good visual prognosis (1-10).

Patients 7 years of age or younger appear to have a better visual prognosis than those older than 7 years of age. In our study in the younger age group, 19 of 22 affected eyes (86 %) achieved 20/40 VA or better versus 17 of 31 affected eyes (55 %) in children older than 7 years of age. Ten of 12 patients of 7 years of age or younger at presentation had bilateral optic neuritis, and 8 of 12 had ADEM in association with optic neuritis. This may indicate that the immature brain is more susceptible

to immune-mediated demyelination, or it may reflect that viral infections are more common in younger patients. Five of our patients with ADEM had biochemical evidence confirming the viral nature of the disease.

#### SWOLLEN OPTIC DISC

In this study the optic disc was swollen in most cases during the acute phase. After 24 months, all the abnormal optic disc appearances (55 %) were due to optic disc pallor. In the study of *Taylor and Cuendet*, the authors reported that the optic disc in their patients remained pale in 89 % of affected eyes approximately 4.6 years after the acute phase of the disease. (2) *Koraszewska-Matuszewska et al.* reported that children younger than 14 years of age tended to have anterior optic neuritis (i.e., acute disc swelling), but retrobulbar neuritis was more common in children over 14 years old. (18) Likewise, *Morales* reported that 57 % of children of 12 years or older had normal fundus findings, and 72 % of children younger than 12 years had optic nerve swelling. (16) Retinal hemorrhages and exudates, though rare, can be seen.

#### ABNORMAL RAPD

Most children (83 % of affected eyes) showed abnormal pupillary reactions at initial presentations, which is comparable with the other studies that demonstrated RAPD or APD present in 77 % and 67 % of affected eyes, respectively. (2,14) During the follow-up there was a significant decrease in RAPD/APD appearance in our group of children. After 2 years, there was positive RAPD only in 12 % of the affected eyes. *Tekavčić* in his study (14) reports no positive RAPD after a 6-month follow-up of 12 children with optic neuritis. (14) In the study of *Taylor and Cuendet*, positive RAPD remained present in 15 % of affected eyes 4.6 years after the acute phase of the illness. (2)

#### VISUAL FIELD AND COLOUR VISION DEFECTS

Most of the visual field defects found at the acute phase were central or paracentral scotomas, which is comparable to another study reporting central scotomas in the majority of affected eyes. (2) During the follow-up a rapid recovery of visual field defects was observed; however, after 2 years, 8 % of the affected eyes in our children documented residual defects. *Tekavčić et al.* (14) reported no visual field defects left after 6 months contrary to *Taylor's* study, in which residual field defects were present in 41 % of affected eyes approximately 4.6 years after the acute phase.

Forty children in our series also showed colour vision defects during initial presentation. Blue-green defects were present slightly more often than red-green defects. The majority of the eyes with colour vision defects recovered within 2 years. In the studies of adults with optic neuritis, residual colour vision defects were reported in 20 % to 36 % of the affected eyes after a 12-month follow-up. (22,23)

VEP findings in childhood optic neuritis were described in the literature in only a few cases. (13,14) Completely unrecordable, delayed and attenuated VEP were associated with the acute phase of the disease. VEP findings in our group of children were similar. There were 91 % of affected eyes in bilateral cases and 100 % eyes with monolateral ON showed VEP abnormalities. During a 4.7-year follow-up in our study, complete VEP recovery occurred in 64 % of eyes with initially abnormal VEP. However, after improvement of VEP parameters, 36 % of the eyes still remained abnormal at the final follow-up. Two studies found normal VEP in 55 % of children approximately 8.8 years after the acute phase, 45 % showed delayed P100. Tekavčić's study documented a complete VEP recovery rate of 42 % of children during a 1-year follow-up. (14)

#### THERAPY

optic neuritis who were treated with oral steroids. Nineteen of 21 patients (90 %) recovered 20/20 VA, and 2 of 21 (10 %) were "practically blind". (5)

A more recent series by *Kriss et al.* (3) reports that 78 % of the affected eyes (39 patients) achieved 20/20 VA, but the use of intravenous steroid therapy was not presented.

*Brady et al.* (8) reported that 21 of 25 patients (84 %) underwent intravenous Several previously reported series address visual outcome after pediatric optic neuritis.

*Kennedy and Carroll* (6) reported on 30 children with idiopathic optic neuritis and stated that 19 of 27 patients (70 %) had moderate or marked visual improvement. Only sixteen per cent of the patients in this series underwent intravenous steroid therapy. (6)

*Riikonen et al.* (5) reported 21 pediatric patients with methylprednisolone therapy (10 to 30 mg/kg/day) and 30 of 39 affected eyes (76 %) achieved 20/40 VA or better in their group of pediatric patients.

In our study, there were 38 of 43 patients (88 %) treated by intravenous methylprednisolone (10 to 40 mg/kg/day) for 3 to 8 days, followed by oral steroids. The side effects of this therapy were minimal including a mild weight gain and facial fullness, which resolved after withdrawing the treatment. Forty-eight of 69 affected eyes (72 %) achieved 20/40 VA or better.

To date, there are no definite guidelines for the treatment of optic neuritis in children. There has been no prospective randomized controlled study of the treatment of pediatric optic neuritis with intravenous steroids. In children, systemic corticosteroid therapy is indicated when visual acuity decreases significantly. (24) *Hwang et al.* (25) in their retrospective study compared the final visual acuity of two groups of children: treated and untreated cases with intravenous corticosteroids. They reported a much better final visual acuity in the treated group of children. (25)

Many clinicians note that this therapy is associated with dramatic visual recovery and are reluctant to withhold treatment, especially in bilaterally affected cases. The

ONTT noted that intravenous methylprednisolone speeds visual recovery in adults. (19) Although this study did not include any pediatric patients, many neurologists and neuro-ophthalmologists are offering their patients intravenous steroids at doses comparable with those in the ONTT. Because our series was not controlled, it is unknown whether the use of intravenous steroids had an effect on ultimate visual outcome.

The treatment of pediatric optic neuritis with corticosteroids is logical due to the autoimmune mechanism of pathogenesis. However, it still remains controversial considering that the visual prognosis is good even regardless of laterality or localization (papillitis vs. retrobulbar). In most cases, intravenous methylprednisolone (10–30 mg/kg/ day x 3–7 days) is recommended to improve and to recover visual loss, and to treat other neurological deficits that the patient manifests. (10) *Farris et al.* demonstrated children with bilateral optic neuritis with an initial visual acuity worse than 10/800, who were treated with intravenous steroids and documented a rapid recovery of vision to the 20/25 level or better. (7)

High rates of relapses have been seen after steroids are tapered too quickly, especially in children with anterior optic neuritis. It is recommended that children should be tapered from oral steroids over a longer period of time than adults, at least 4 to 8 weeks. (7) Considering the relatively benign nature of steroid therapy, most clinicians recommended it for optic neuritis in children, despite the fact that no clear benefit on the final visual outcome has been established through a randomized placebo control study.

## MRI

MRI is the imaging study of choice in optic neuritis. A normal-appearing MRI of the brain has been shown to be a powerful tool in predicting outcomes in adult patients with clinical syndromes that are suggestive of MS, including optic neuritis. (28) Several studies have confirmed that white-matter lesions are more readily identified on MRI than on computed tomographic scans of the brain in pediatric patients. (29–31) In our study a normal-appearing MRI scan of the brain was associated with an excellent visual prognosis in 80 % of the affected eyes. A statistical analysis of our data demonstrated a trend towards improved visual outcome in patients with a normal-appearing MRI of the brain. *Brady et al.* (8) reported excellent visual outcome in 100 % of the eyes in children with normal MRI of the brain, and they suggested that a normal-appearing MRI of the brain may be a predictor of better visual outcome.

## MULTIPLE SCLEROSIS

Eight of our patients had clinically definite MS. Although optic neuritis is associated with the eventual development of MS in many adult patients, our follow-up period was short, and no definite conclusions could be made about any association between optic neuritis and the eventual development of MS in our patients. Seven



of the 8 patients with MS had recurrent bilateral optic neuritis; this finding supports the previous observation that bilateral recurrent optic neuritis is more often associated with MS than unilateral or bilateral simultaneous optic neuritis. (32) The risk of MS following an episode of ON in children is much lower than in adults. The reported risk of MS was estimated to be 13 % after 10 years and 19 % after 20 years. (35) In the other reported series 1 of 13 patients developed MS after 4 years of follow-up. (34) Morales demonstrated that in 26 % of patients MS occurred after 2 years of follow-up. (16) The risk of MS in children based on the presence or absence of demyelinating plaques on MRI is not well established. Three recent studies reported a wide range of incidence of patients with demyelinating lesions on baseline MRI. (5,7,16)

Morales et al. noted that the age of onset and laterality influenced the risk of MS. Patients who develop MS were older at the onset with a mean age of 12 years, compared to 9 years in children who did not develop MS. Children with recurrent optic neuritis are at greater risk for developing MS than those with single isolated episodes. (16)

Today there are immunomodulating drugs available which have been shown to reduce the development and severity of clinically definite MS. Immunomodulators include interferon beta-1a, interferon beta-1b, and glatiramer acetate (Copaxone). The interferons work through several different mechanisms, including reduced antigen presentation, inhibition of proinflammatory cytokines and autoreactive T-cells, induction of immunosuppressive cytokines, and decreased migration of cells in the CNS. Glatiramer acetate blocks antigen binding to major histocompatibility complex (MHC) class II, inhibits chemokine production, stimulates immunosuppressive cytokines, and interferes with sensitization of pathogenic T-cells. These drugs are all FDA-approved for the management of relapsing-remitting MS. (10)

In conclusion, the findings of our study showed a high recovery rate of all clinical parameters except optic disc appearance. They suggest that pediatric optic neuritis is typically associated with a successful visual recovery but may result in visual disability in a significant number of affected eyes. Younger age at presentation and a normal-appearing MRI of the brain may be associated with a better visual prognosis.

## REFERENCES

1. *Parkin PJ, Hierons R, McDonald WI.* Bilateral optic neuritis. *Brain* 1984;107: 951-964.
2. *Taylor D, Cuendet F.* Optic neuritis in childhood. In: Hess RF, Plant GT, Eds. *Optic neuritis.* Cambridge: Cambridge University Press; 1986:73-85.
3. *Kriss A, Francis DA, Cuendet F, Batchelor JR, McDonald WI.* Recovery after optic neuritis in childhood. *J Neurol Neurosurg Psychiatry* 1988;51:1253-1258.
4. *Meadows SP.* Retrobulbar and optic neuritis in childhood and adolescence. *Trans Ophthalmol Soc UK* 1969;89:603-638.
5. *Riikonen R, Donner M, Erkkila H.* Optic neuritis in children and its relationship to multiple sclerosis: a clinical study of 21 children. *Dev Med Child Neurol* 1988;30:349-359.

6. Kennedy C, Carroll F. Optic neuritis in children. *Arch Ophthalmol* 1960;63:747-755.
7. Farris BK, Packard DJ. Bilateral postinfectious optic neuritis and intravenous steroid therapy in children. *Ophthalmology* 1990; 97: 339-345.
8. Brady KM, Brar AS, et al. Optic neuritis in children: clinical features and visual outcome. *JAAPOS* 1999; 3:98-103.
9. Good WV, Muci-Mendoza R, Berg BO, Frederick DR, Hoyt CS. Optic neuritis in children with poor recovery of vision. *Aust NZ J Ophthalmol* 1992;20:319-323.
10. Boomer JA, Siatkowski RM. Optic neuritis in adults and children. *Seminars in Ophthalmology* 2003; 18: 174-180.
11. Halliday AM, McDonald WI, Mushin J. Delayed visual evoked response in optic neuritis. *Lancet* 1972; 11: 982-985.
12. Halliday AM. Evoked potentials in clinical testing. New York: Churchill Livingstone, 1993: 195-278.
13. Halliday AM, Kriss A, Cuendet F, et al. Childhood optic neuritis: a study of pattern and flash evoked potentials. In: Gallai V, ed. *Maturation of the CNS and evoked potentials*. Amsterdam: Elsevier, 1986: 41-50.
14. Tekavčić-Pompe M, Stirn-Kranjc B, Brecelj J. Optic neuritis in children-clinical and electrophysiological follow-up. *Documenta Ophthalmologica* 2003; 107: 261-270.
15. Bradford GM, Kutschke PJ, Scott WE. Results of amblyopia therapy in eyes with unilateral structural abnormalities. *Ophthalmology* 1992;99:1616-1621.
16. Morales DS., Siatkowski RM et al. Optic neuritis in children. *J Pediatr Ophthalmol Strabismus* 2000; 37: 254-259.
17. Beck RW. Optic neuritis. In: Miller NR, Newman NJ, Walsh and Hoyt's Clinical Neuroophthalmology, 5th ed. Williams and Wilkins, 1998; chap 12: 632-634.
18. Koraszewska-Matuszewska B, Samochowiec-Donocik E, et al. Optic neuritis in children and adolescents. *Klin Oczna* 1995; 97: 207-210.
19. Beck RW, Cleary PA, Anderson MM, Keltner JL, Shults WT, Kaufman DI, et al. A randomized controlled trial of corticosteroids in the treatment of acute optic neuritis. *N Engl J Med* 1992;326:581-588.
20. Awerbuch G, Labadie EL, Van Dalen JT. Reversible optic neuritis secondary to paranasal sinusitis. *Eur Neurol* 1989;29:189-193.
21. Kountakis SE, Maillard AA, Stiernberg CM. Optic neuritis secondary to sphenothmoiditis: surgical treatment. *Am J Otolaryngol* 1995;16:422-427.
22. Trobe JD, Beck RW, Moke PS, et al. Contrast sensitivity and other vision tests in the optic neuritis treatment trial. *Am J Ophthalmol* 1996; 121: 547-553.
23. Beck RW, Cleary PA, Trobe JD, et al. The effect of corticosteroids for acute optic neuritis on the subsequent development of multiple sclerosis. *New Engl J Med* 1993; 329: 1764-1769.
24. Taylor D, et al. *Pediatric ophthalmology*. 2nd ed. Oxford: Blackwell Scientific Publications, 1997: 473-488.
25. Hwang JM, Lee YJ, Kim MK. Optic neuritis in Asian children. *J Pediatr Ophthalmol Strabismus* 2002;39:26-32.
26. Riikonen R, Ketonen L, Sipponen J. Magnetic resonance imaging, evoked responses and cerebrospinal fluid findings in a follow-up study of children with optic neuritis. *Acta Neurol Scand* 1988;77:44-49.
27. Rush JA. Idiopathic optic neuritis of childhood. *J Pediatr Ophthalmol Strabismus* 1981;18:1253-1258.
28. Morrissey SP, Miller DH, Kendall BE, et al. The significance of brain magnetic resonance imaging abnormalities at presentation with clinically isolated syndromes suggestive of multiple sclerosis. *Brain* 1993;116:135-146.
29. Miller DH, Robb SA, Ormerod IE, et al. Magnetic resonance imaging of inflammatory and demyelinating white-matter diseases of childhood. *Dev Med Child Neurol* 1990;32:97-107.
30. Nowell MA, Grossman RI, Hackney DB, et al. MR imaging of white matter disease in children. *AJNR Am J Neuroradiol* 1988;9:503-509.
31. Dunn V, Bale JF, Zimmerman RA, et al. MRI in children with postinfectious disseminated encephalomyelitis. *Magn Reson Imaging* 1986;4:25-32.
32. Lucchinetti CF, Kiers L, O'Duffy A, et al. Risk factors for developing multiple sclerosis after childhood optic neuritis. *Neurology* 1997;49:1413-1418.
33. Kennedy C, Carroll FD. Optic neuritis in children. *Arch Ophthalmol* 1960; 63: 747-755.
34. Hierons R, Lyle TK. Bilateral retrobulbar optic neuritis. *Brain* 1959;82: 56-57.
35. Good WV, Muci-Mendoza R, et al. Optic neuritis in children with poor recovery of vision. *Aust NZ J Ophthalmol* 1992;20: 319-323.



## TRABECULECTOMY WITH ADJUNCTIVE INTRAOPERATIVE USE OF MITOMYCIN C IN THE TREATMENT OF PAEDIATRIC GLAUCOMA

HELMANOVÁ I., AUTRATA R., PYROCHTOVÁ S., ŘEHŮŘEK J.

Department of Paediatric Ophthalmology, Faculty of Medicine, Masaryk University Hospital, Brno

*Received after revision February 2007*

### Abstract

To evaluate the long-term efficacy and safety of trabeculectomy with adjunctive intraoperative use of mitomycin C (MMC) in paediatric patients with primary and secondary glaucomas, and to identify risk factors for failure of this technique.

A retrospective, noncomparative study of consecutive paediatric patients with glaucoma that underwent mitomycin C-augmented trabeculectomy from January 1995 to December 2005. The medical records of 61 consecutive patients (78 eyes) with a mean age of 7.3 years (range: 5 months to 17.3 years) were reviewed. A variety of primary and secondary glaucomas were identified. Mitomycin C (0.5 mg/ml) on a surgical sponge was applied to the episcleral surface for an average of  $3.6 \pm 1.2$  minutes (range: 2–5 minutes). Patients were followed up until a repeat glaucoma surgery after a minimum of 12 months. The clinical outcome examination included intraocular pressure (IOP) control, visual acuity, complications, and risk factors for failure. The surgical outcome was evaluated using Kaplan-Meier life-table analysis. Success was defined as IOP control of 22 mmHg or less with or without topical antiglaucoma medications, no evidence of glaucoma progression, without further glaucoma surgery, and without visually devastating complications. The outcomes for the group of patients with primary infantile glaucoma were compared with those for the group with secondary glaucoma.

The mean follow-up was  $6.2 \pm 4.8$  years (range: 1.2 to 11.5 years). The mean preoperative IOP for all eyes was  $35.4 \pm 9.7$  mmHg (range: 24 to 55 mmHg) and the postoperative mean IOP in all eyes was  $19.3 \pm 11.7$  mmHg (range: 5 to 43 mmHg) ( $p < 0.05$ ). The 12-, 24-, 36-, 48- and 60-month life-table cumulative probabilities of the success rate for IOP control were 79 %, 71 %, 65 %, 62 % and 58 %, respectively. Multivariate regression analysis determined the following factors as a significantly increased risk for failure: age of less than 1 year at time of surgery, aphakia, aniridia, anterior segment dysgenesis, and gipsy race. There was no difference in the cumulative success rate ( $p = 0.114$ ) during follow-up between primary ( $n = 35$  eyes) and secondary glaucoma ( $n = 43$  eyes) patients. A total of 28 eyes (35.9 %) were classified as failures: 25 eyes failed due to elevated intraocular pressure and the need for subsequent glaucoma surgery, 3 eyes failed due to a suprachoroidal haemorrhage, retinal detachment and loss of light perception. Six eyes (7.6 %) experienced a late bleb-related infection at 2 to 5 years after surgery. Other complications included flat anterior chamber, hyphaema, chronic hypotonia, serous choroidal detachment, spontaneously resolved.

Our study demonstrates that trabeculectomy with intraoperative adjunctive mitomycin C is an effective treatment for many paediatric glaucomas in which goniotomy, trabeculotomy or both have failed. Bleb-related endophthalmitis is an important risk of this surgery in children. Phakic children over 1 year of age at the time of surgery have a significantly higher probability of success than aphakic eyes in younger children.

## Key words

Paediatric glaucoma, Trabeculectomy, Mitomycin C

## Abbreviations used

IOP, intraocular pressure; MMC, mitomycin C; BRI, bleed-related infection

## INTRODUCTION

The initial management of childhood glaucomas generally involves surgery, and both goniotomy and trabeculotomy have been shown to have equivalent rates of success for primary infantile and congenital glaucoma with a low rate of complications. (1,2) When angle surgery fails to control the intraocular pressure (IOP) or is unlikely to succeed, trabeculectomy is the procedure of choice for most glaucoma surgeons. However, trabeculectomy has been reported to have a lower success rate in children compared with adults, (3,4) a feature that has been attributed to the inherent tendency toward excessive scarring in young children. (8) This tendency, combined with additional risk factors for surgical failure such as prior intraocular surgery, aphakia, or uveitis, predisposes to rapid fibrosis at the filtering site. (3,9) Mitomycin C (MMC) is an alkylating agent which interferes with DNA synthesis and inhibits both fibroblast proliferation and collagen synthesis. Mitomycin C has been shown to improve the success rate of trabeculectomy in humans. (10,11) Given the rapid formation of scar tissue and the generally poor co-operation with postoperative examination in the paediatric population, a single intraoperative application of the antifibrosis agent MMC may be preferred to 5-fluorouracil, which generally requires postoperative injections. (12) Trabeculectomy without antimetabolite therapy has a low probability of success in patients of 17 years of age or younger. (15-17) Trabeculectomy with adjunctive 5-fluorouracil has been utilised successfully in paediatric glaucoma patients, but the need for frequent subconjunctival injections has limited its application in this age group. (19,18) The success of trabeculectomy performed in adult glaucoma patients has been enhanced by the use of adjunctive MMC. (20,21) Success rates ranging from 56 % to 95 % have been reported for MMC trabeculectomy in paediatric patients. (22-24) Previous reports of trabeculectomy with MMC in a paediatric population are few. The purpose of this retrospective study is to analyse the success of trabeculectomy with MMC in a children group, and to identify risk factors for failure of the procedure.

## PATIENTS AND METHODS

A retrospective, noncomparative review of medical records identified 61 paediatric patients with glaucoma, who underwent trabeculectomy with intraoperative application of mitomycin C (61 consecutive patients, 78 eyes) from January 1995 to December 2005 at the Department of Paediatric Ophthalmology, Masaryk University Hospital. The results of all trabeculectomies with mitomycin C were recorded and statistical analysis performed. Thirty-four patients were females, 27 were males. The mean age was 7.3 years (range: 5 months to 17.3 years) (Table 1). All patients were seen on the

first postoperative day, and at 1 week, 1 month, 3 months, and 6 months. Patients who had successful outcomes at 6 months were followed up every 3 months. Preoperative and postoperative intraocular pressure (IOL) were measured while the patient was awake and in the sitting position using a Goldmann applanation tonometer or a Tonopen (Mentor Inc., Norwell, MA) whenever permitted by the patient's cooperation. A Tonopen or Perkins applanation tonometer was used during the examination under general anaesthesia for patients unable to co-operate. The best-corrected visual acuity was measured by a variety of methods according to each patient's age and degree of co-operation. The examinations included refraction, slit-lamp examination, and ophthalmoscopy. Visual fields were attempted in all children who were at least 7 to 8 years of age.

*Table 1*  
Demographic characteristics

Demographic characteristics	n (%)
Mean age (years) (range)	7.3 years (0.4 to 17.3)
Sex (n = 61 patients) Male	27 (44 %)
Female	34 (56 %)
Race (n = 61 patients) White	48 (78 %)
Gipsy	13 (22 %)
Prior glaucoma surgery (n = 78 eyes) Yes	52 (67 %)
No	26 (33 %)
Phakic	43 (55 %)
Aphakic	28 (36 %)
Pseudophakic	7 (9 %)
<b>Diagnosis</b>	
Primary congenital glaucoma	17 (22 %)
Anterior segment dysgenesis	14 (18 %)
Aniridia	8 (10 %)
Glaucoma after congenital cataract extraction	11 (14 %)
Juvenile open angle glaucoma	7 (9 %)
Traumatic glaucoma	6 (8 %)
Persistent hyperplastic primary vitreous	5 (6 %)
Glaucoma associated with uveitis (JRA)	4 (5 %)
Glaucoma with Sturge-Weber syndrome	3 (4 %)
Glaucoma with retinopathy of prematurity	3 (4 %)

JRA= juvenile rheumatoid arthritis

All surgeries were performed or directly supervised by two of the authors (A.R., R.J.). A limbus-based flap of conjunctiva and Tenon's capsule was created. Haemostasis was maintained. A one-half to three-quarter thickness trapezoidal or rectangular scleral flap was outlined adjacent to the superior limbus and dissected anteriorly. A 5 × 5 to 5 × 10-mm piece of cellulose sponge soaked in MMC (0.25–0.5 mg/ml) was placed on the episcleral surface overlying the intended surgical site either before or after scleral flap dissection. After removal of the sponge, the exposed episcleral surface and sub-Tenon's space were irrigated with balanced salt solution. When the MMC-soaked sponge was applied after scleral flap dissection, it was positioned over the scleral flap. A paracentesis track was made at least 90° from the scleral flap. The scleral flap dissection was then carried forward into the clear cornea. The internal trabeculotomy ostium was created by removal of a section of cornea, trabecular meshwork,

or both beneath the scleral flap. A peripheral iridectomy was performed. The scleral flap was closed with two to four interrupted 10-0 monofilament nylon or polyglactin sutures, the knots of which were buried within the sclera. The conjunctiva and Tenon's capsule were closed with a running 9-0 polyglactin suture on a vascular needle in one or two layers. Ten to 20 mg of methylprednisolone acetate and 10 to 20 mg of gentamicin were injected subconjunctivally into the inferior fornix.

Postoperative management included topical antibiotics for 1 week and then corticosteroids (prednisolone acetate 1 %) for 3 to 5 months in a tapering dose. Topical ocular hypotensive medications were used if necessary for the control of intraocular pressure.

Surgical success was defined as intraocular pressure control of 22 mm Hg or less with or without topical glaucoma control medication, no evidence of glaucoma progression, no further glaucoma surgery necessary, and no visually devastating complication. Two separate clinic visits at which the patients had average intraocular pressures of 23 mm Hg or greater on maximum-tolerated topical glaucoma control medications were required for failure. Glaucoma progression was judged to have occurred if the cup:disk ratio increased by 0.2 or more, or if a new visual field defect was noted on two consecutive examinations.

Surgical success was analysed by patient age at the time of surgery, lens status, diagnosis, and prior glaucoma surgery. Time to failure and overall success were analysed for these variables. For statistical analysis, several factors were analysed for each patient: age at surgery (less than or greater than 1 year); lens status (aphakia/pseudophakia or phakia); previous glaucoma surgery; diagnosis (anterior segment dysgenesis/ aniridia, or all others). A univariate analysis of factors related to failure was done using a chi-square test or Fisher exact test. The differences among the subgroups were assessed using the log-rank test. A P value of 0.05 or less indicated statistical significance. Because of the variability in length of the follow-up among patients, Kaplan-Meier life-table (survival) analysis was used to estimate the success rate at various postoperative intervals.

## RESULTS

Seventy-eight eyes of 61 patients were categorised by the Shaffer-Weiss classification system. The following diagnoses were noted ( $n = 78$  eyes): 17 with primary congenital glaucoma, 14 with anterior segment dysgenesis (Axenfeld-Rieger and Peter anomaly), 8 with aniridia, 11 with glaucoma after congenital cataract extraction, 7 with juvenile open angle glaucoma, 6 with traumatic glaucoma, 5 with persistent hyperplastic primary vitreous, 4 with glaucoma associated with JRA, 3 with Sturge-Weber syndrome, and 3 with retinopathy of prematurity. Forty-three eyes were phakic, 28 eyes were aphakic, and 7 eyes were pseudophakic. Twenty-six eyes had no prior glaucoma surgery, 52 eyes had at least one prior glaucoma surgery. The mean number of prior surgical procedures was  $1.3 \pm 0.9$  (range: 0-3). Mitomycin C application time averaged  $3.6 \pm 1.2$  minutes (range: 2.0-5.0 minutes).

Cumulative probabilities of success ( $n = 78$ ) were  $79\% \pm 14\%$  at 12 months,  $71\% \pm 16\%$  at 24 months,  $65\% \pm 15\%$  at 36 months,  $62\% \pm 17\%$  at 48 months, and  $58\% \pm 15\%$  at 60 months (*Fig. 1*). The mean IOP reduction after MMC-trabeculectomy was  $16.1 \pm 12.4$  mm Hg for all eyes. The average IOP reduction was statistically significant ( $P = 0.0028$ , paired t-test). The mean preoperative IOP for all eyes was  $35.4 \pm 9.7$  mmHg (range: 24 to 55 mmHg) and the postoperative mean IOP in all eyes was  $19.3 \pm 11.7$  mmHg (range, 5 to 43 mmHg) ( $p < 0.05$ ).

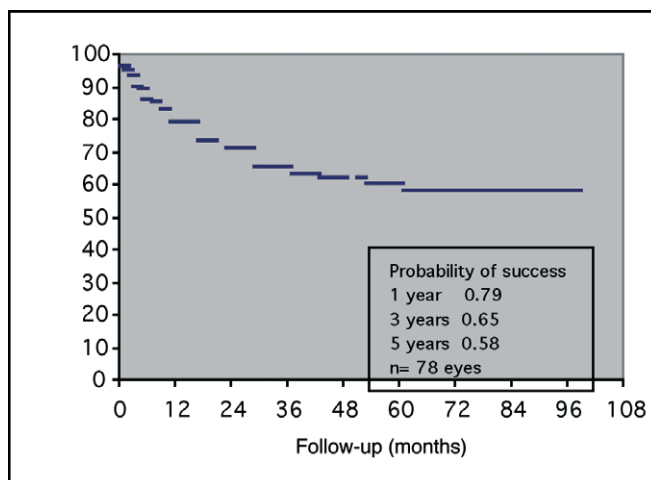
Fifty (64 %) of 78 eyes were successful at the last follow-up visit with a mean intraocular pressure of  $14.3 \pm 7.2$  mm Hg (range: 6 to 22 mm Hg) on an average of

0.7 topical antiglaucoma medications (range: 0 to 2 medications). The mean follow-up of the successful eyes was  $43.5 \pm 19.0$  months (range: 18 to 80 months), with 31 eyes (62 %) requiring no topical antiglaucoma medication, 10 eyes (20 %) requiring one medication, and 9 eyes (18 %) requiring two medications (*Table 2*).

*Table 2*  
Preoperative and postoperative intraocular pressures (IOP) and antiglaucoma medications

Preoperative IOP (mm Hg) (n = 78 eyes)	$35.4 \pm 9.7$ SD
Preoperative medication (mean, range)	2.1 (1–4)
Postoperative IOP, n=78 eyes (mm Hg)	$19.3 \pm 11.7$ SD
Postoperative IOP, successful eyes (n = 36) (mm Hg)	$14.3 \pm 7.2$ SD
Follow-up time of successful eyes (months)	$43.5 \pm 19.0$ SD
Topical antiglaucoma medication, successful eyes	
0	31 (62 %)
1	10 (20 %)
2	9 (18 %)

A total of 28 eyes (36 %) were classified as failures. The mean age at the time of surgery for these eyes was 4.7 years (range: 5 months to 14.5 years). The average time to failure was  $8.6 \pm 6.9$  months (range: 3 to 27 months). The mean preoperative and postoperative IOPs were 37.1 mm Hg (range: 22 to 52 mm Hg) and 32.5 mm Hg (range: 22 to 46 mm Hg), respectively. Twenty-five eyes failed due to elevated intraocular pressure and the need for subsequent glaucoma surgery, 3 eyes failed due to a suprachoroidal haemorrhage, retinal detachment, and loss of light perception.



*Fig. 1*  
Kaplan-Meier analysis for the cumulative probability of success and months of follow-up after MMC trabeculectomy on all 78 eyes

*Table 3*  
Univariate analysis of risk factors for failure of trabeculectomy with MMC

Risk factor	n (eyes)	% of failure	1st P-value	2nd P-value
Male	35	38		
Female	43	36	0.843	0.729
Race: white	58	23		
Race: gipsy	20	87	0.035	0.028
age<1 year	21	83		
age 1 to 18 years	57	24	0.017	0.0045
Aniridia//Anterior segment dysgenesis	8/14	59/73		
Other diagnosis	56	26	0.041	0.043
Aphakic eyes/Pseudophakic eyes	28/ 7	65/49		
Phakic eyes	43	23	0.026	0.037
Previous glaucoma surgery	52	48		
No previous glaucoma surgery	26	31	0.45	0.56

*Table 4*  
Multiple regression analysis of adjusted relative risks for failure of trabeculectomy with MMC

Risk factor	Relative risk	95% Confidence interval	P-value
age < 1 year	7.3	2.5-16.2	.0013
Aphakia or pseudophakia	3.8	1.8-10.4	.029
ADS or aniridia	2.3	1.7-6.8	.041
Gipsy race	2.2	0.9-6.3	.048
Previous glaucoma surgery	1.6	0.5-2.1	.57
Male gender	1.5	0.7-1.9	.74

Statistical analysis of surgical success by sex, age, lens status, diagnosis, and prior glaucoma surgery: a univariate analysis demonstrated an increased risk of failure that was statistically significant for patients under 1 year of age ( $P = .012$ ), aphakia ( $P = .019$ ), diagnosis of aniridia or anterior segment dysgenesis ( $P = .037$ ), and gipsy race ( $P = .041$ ) (*Table 3*). A multivariate regression analysis demonstrated statistically significant risk ratios of 7.3 (confidence interval, 2.5 to 16.2;  $P = .0013$ ) for patients under 1 year of age, 3.8 (confidence interval, 1.8 to 10.4;  $P = .029$ ) for aphakic patients, and 2.3 (confidence interval, 1.7 to 6.8;  $P = .041$ ) for patients with anterior segment dysgenesis (*Table 4*).

There was no difference in the cumulative success rate ( $P= 0.114$ ) during the follow-up between primary

( $n=35$  eyes) and secondary glaucoma ( $n=43$  eyes) patients.

The final postoperative best-corrected visual acuity was the same as, or better than, the preoperative level in 41 of the 50 patients categorised as successes (82 %). Six of the 28 patients (21 %) categorised as failures demonstrated a decrease in visual acuity.

Three (4 %) of all 78 eyes experienced a postoperative retinal detachment resulting in light perception visual acuity.

There were the following complications after trabeculectomy with MMC: shallow anterior chamber in 19 eyes (24 %), serous choroidal detachment in 11 eyes (14 %), hyphaema in 13 eyes (16 %), and chronic hypotonia in 10 eyes (12.8 %). These complications resolved spontaneously. Three eyes (4 %) either developed cataract or had progression of existing cataract. Four eyes (5 %) each were noted to have the following complications: haemorrhagic choroidal detachment, retinal detachment, vitreous haemorrhage, and late bleb leak.

Bleb-related infection (BRI) occurred in 6 of 78 eyes (7.6 %) at 23 to 51 months postoperatively. Blebitis occurred in two patients and bleb-related late-onset endophthalmitis in four. Five of the six infections (83 %) occurred in patients with primary infantile glaucoma. Although the incidence of BRI was greater in the group of patients with primary infantile glaucoma (14 %) than in the group with secondary glaucoma (2.3 %), this difference did not reach statistical significance. Four of the six eyes with endophthalmitis were noted to have excellent outcomes with IOP control and unchanged visual acuity.

## DISCUSSION

Prior reports describing the outcome of trabeculectomy without the use of adjunctive antifibrosis agents in the management of childhood glaucomas have documented success rates between 35 % and 50 % at variable follow-up intervals. (3-7, 15-17) Trabeculectomy has been utilised as an initial procedure in primary congenital glaucoma with higher success rates (54 % to 87 %), although with lower success rates than those noted for goniotomy and trabeculotomy. (28-30)

The antifibrosis agents 5-fluorouracil and MMC have been shown to enhance the rate of successful IOP control after trabeculectomy in adult patients at high risk for surgical failure. (10,11) In vitro studies have demonstrated a significant and prolonged effect on the proliferation and morphological characteristics of Tenon's capsule fibroblasts after direct exposure to high concentrations of 5-fluorouracil and MMC. (13) A greater effect for MMC as compared with 5-fluorouracil on both fibroblast proliferation and morphological characteristics has been shown by cell culture analysis. (14) Clinical studies comparing the two antifibrosis agents have similarly demonstrated a greater success rate and a greater degree of IOP reduction with MMC. (12)



One large series of 56 patients (79 eyes) has been reported by Susanna *et al* (22), who noted an overall success rate of 67 % with an average follow-up of 17 months. This is similar to the success rate in our study of 71 % at 24 months. The study population reported by *Susanna et al* (22) differed from ours in that it was composed of predominantly phakic primary congenital glaucoma patients. A high success rate (95 %) with mitomycin C trabeculectomy was noted in a series of 19 eyes reported by *Mandal et al* (23), who studied predominantly phakic primary congenital glaucoma patients. A much lower success rate (56 %) of 16 eyes was noted in a study by *Wallace et al* (24) for secondary paediatric glaucoma patients.

*Sidoti et al* (25) reported a 36-month life-table success rate for IOP control in 59 % of paediatric eyes. *Beck et al* (26) demonstrated a similar success rate (59 %) at 2 years postoperatively in their large series of paediatric glaucoma patients. In our present series, the 65 % life-table success rate at 36 months after surgery confirms the moderately good success rate of MMC trabeculectomy at intermediate follow-up intervals in paediatric patients. The long-term ability of MMC to improve trabeculectomy success rates in young children remains uncertain.

A very important risk factor for failure of MMC trabeculectomy is patient age. *Beck et al* (26) noted a decreased success rate (15 %) at the last follow-up in patients under the age of 1 year and a risk ratio of 5.6 with high statistical significance ( $P=.0005$ ), which is comparable with our results (risk ratio 7.3 ( $P=.0013$ )).

Aphakia is a known risk factor for failure after trabeculectomy in adult glaucomas. *Beck et al* (26) demonstrated an increased risk of failure for this group of aphakic eyes with multivariate analysis (risk ratio: 2.7;  $P=.0364$ ). A higher risk ratio by the same statistical analysis for MMC trabeculectomy in aphakic eyes was found in our present study (risk ratio: 3.8;  $P=.029$ ).

Aniridia and anterior segment dysgenesis have been noted to be refractory to glaucoma surgical intervention. (22, 24–26) Our study demonstrated an increased risk for failure in these secondary glaucomas which was statistically significant ( $P=.037$ ). A number of our patients with aniridia and anterior segment dysgenesis were also aphakic or less than 1 year of age; factors which we noted to be more important as risk factors for failure.

A combination of these two diagnostic categories and patient age less than 1 year of age demonstrated very poor outcomes, with no long-term success.

Aphakic patients after congenital cataract extraction had a higher success rate (84 %) for IOP control at the last follow-up. The study by *Beck et al* (26) noted success in 78 % with aphakic glaucoma after cataract extraction. It is likely that the older age of children who develop glaucoma after cataract extraction at least partially explains this improved success rate compared to the success rates of studies involving other aphakic children.

No significant differences in the success rates were noted when comparing eyes that had previous glaucoma surgery to those eyes that had no prior surgery (22,26).



Also, in our study we did not demonstrate a statistically significant difference, although a lower success rate was noted for the group that underwent prior glaucoma surgery.

Bleb-related infection after MMC trabeculectomy in children was described previously (22, 24-26), although the incidence in the few reported series of paediatric patients was low. Six patients (7.6 %) in this series experienced BRIs at a mean follow-up of 43.1 months. Of these, four experienced endophthalmitis and the remaining two patients experienced blebitis. The mean follow-up time until the development of BRI was significantly longer than the average total follow-up time for patients in previous reports of MMC trabeculectomy in children. The late onset of BRI as well as the increased risk of infection at longer postoperative intervals in eyes with functional filtering blebs may result from progressive conjunctival thinning after MMC application. BRI is a serious complication of trabeculectomy in children, and its incidence appears to be increased by the adjunctive use of MMC. Such infections may occur at extended postoperative intervals as demonstrated in this report. Secondary complications may be related to the infection itself or the aggressive treatment required to eradicate the infection. Loss of filtering bleb function and IOP control, the need for additional intraocular procedures, and loss of vision may result. Successful treatment of blebitis without compromise of filtering bleb function or visual acuity is possible, if identified early.

Trabeculectomy with MMC has been associated with the development of chronic hypotonia and vision loss in adults. (32,33) The seven paediatric patients (ten eyes) who did develop hypotonia and maculopathy in our study had good outcomes with conservative management. Children have a rapid healing response which may quickly reverse overfiltration. We observed spontaneous re-formation of all shallow or flat anterior chambers within several days.

Alternative surgical interventions for paediatric glaucoma patients are drainage implants and cyclodestruction. Drainage implants have been associated with much higher success rates than has cyclodestruction in paediatric glaucoma. (34-36) *Molteno*, *Baerveldt*, and *Ahmed* implants have been used in paediatric patients, with ultimate success rates of 44 % to 95 %. (37-39) Unlike trabeculectomy, surgical revision of these devices is frequently necessary in children. The mean intraocular pressure is higher with drainage implants compared to trabeculectomy with adjunctive mitomycin C, and the need for glaucoma medications is higher with drainage implants. (37-39) Some children with advanced glaucomatous damage may require intraocular pressure control in the lower part of the normal range to stabilise their disease, making trabeculectomy with adjunctive mitomycin C a more attractive option compared to a drainage implant. However, the risk of endophthalmitis is negligible with drainage implants compared to trabeculectomy with mitomycin C. Drainage implants are probably a better option than is trabeculectomy for aphakic

children who are contact-lens dependent, and who may be at greater risk for late-onset endophthalmitis after trabeculectomy.

Our study demonstrates that trabeculectomy with intraoperative adjunctive mitomycin C is an effective treatment for many paediatric glaucomas in which goniotomy, trabeculotomy or both have failed. Bleb-related endophthalmitis is an important risk with this surgery in children. Phakic children over 1 year of age at the time of surgery and of white race have a significantly higher probability of success than aphakic eyes with aniridia, anterior segment dysgenesis, in younger children, and of gipsy race. A randomised, prospective, multicentre trial between trabeculectomy with adjunctive mitomycin C and drainage implants would be helpful to determine the best surgical method for the different paediatric glaucoma groups.

#### REFERENCES

1. *Anderson DR*. Trabeculotomy compared to goniotomy for glaucoma in children. *Ophthalmology* 1983; 90: 805-806.
2. *McPherson SD, Jr and Berry DP*. Goniotomy vs external trabeculotomy for developmental glaucoma. *Am J Ophthalmol* 1983; 95: 427-431.
3. *Beauchamp GR, Parks MM*. Filtering surgery in children: barriers to success. *Ophthalmology* 1979; 86:170-180.
4. *Burke JP, Bowell R*. Primary trabeculectomy in congenital glaucoma. *Br J Ophthalmol* 1989; 73: 188-190.
5. *Fulcher T, Chan J, Lanigan B, et al*. Long-term follow up of primary trabeculectomy for infantile glaucoma. *Br J Ophthalmol* 1996; 80: 499-502.
6. *Debnath SC, Teichmann KD, Salamah K*. Trabeculectomy versus trabeculotomy in congenital glaucoma. *Br J Ophthalmol* 1989; 73: 608-611.
7. *Cadera W, Pachtman MA, Cantor LB, et al*. Filtering surgery in childhood glaucoma. *Ophthalmic Surg* 1984; 15: 319-322.
8. *Skuta GL and Parrish RK*. Wound healing in glaucoma filtering surgery. *Surv Ophthalmol* 1987; 32: 149-170.
9. *Sturmer J, Broadway DC, Hitchings RA*. Young patient trabeculectomy. Assessment of risk factors for failure. *Ophthalmology* 1993; 100: 928-939.
10. *Chen CW, Huang HT, Bair JS, et al*. Trabeculectomy with simultaneous topical application of mitomycin-C in refractory glaucoma. *J Ocul Pharmacol* 1990; 6: 175-182.
11. *Kupin TH, Juzych MS, Shin DH, et al*. Adjunctive mitomycin C in primary trabeculectomy in phakic eyes. *Am J Ophthalmol* 1995; 119: 30-39.
12. *Katz GJ, Higginbotham EJ, Lichter PR, et al*. Mitomycin C versus 5-fluorouracil in high-risk glaucoma filtering surgery. Extended follow-up. *Ophthalmology* 1995; 102: 1263-1269.
13. *Jampel HD*. Effect of brief exposure to mitomycin C on viability and proliferation of cultured human Tenon's capsule fibroblasts. *Ophthalmology* 1992; 99: 1471-1476.
14. *Khaw PT, Sherwood MB, MacKay SL, et al*. Five-minute treatments with fluorouracil, floxuridine, and mitomycin have long-term effects on human Tenon's capsule fibroblasts. *Arch Ophthalmol* 1992; 110: 1150-1154.
15. *Inaba Z*. Long-term results of trabeculectomy in the Japanese: analysis by life-table method. *Jpn J Ophthalmol* 1982; 26: 361-373.
16. *Gressel MG, Heuer DK, Parrish RK II*. Trabeculectomy in young patients. *Ophthalmology* 1984; 91: 1242-1246.
17. *Beauchamp GR, Parks MM*. Filtering surgery in children: barriers to success. *Ophthalmology* 1979; 86: 170-180.
18. *Zalish M, Leiba H, Oliver M*. Subconjunctival injection of 5-fluorouracil following trabeculectomy for congenital and infantile glaucoma. *Ophthalmic Surg* 1992; 23: 203-205.
19. *Whiteside-Michel J, Liebmman JM, Ritch R*. Initial 5-fluorouracil trabeculectomy in young patients. *Ophthalmology* 1992; 99: 7-13.

20. *Chen C-W*. Enhanced intraocular pressure controlling effectiveness of trabeculectomy by local application of mitomycin C. *Trans Asia-Pacific Acad Ophthalmol* 1983; 9: 172-177.
21. *Palmer SS*. Mitomycin as adjunct chemotherapy with trabeculectomy. *Ophthalmology* 1991; 98: 317-321.
22. *Susanna R, Oltrogge EW, et al*. Mitomycin as adjunct chemotherapy in congenital and developmental glaucoma. *J Glaucoma* 1995; 4: 151-157.
23. *Mandal AK, Walton DS, et al*. Mitomycin C-augmented trabeculectomy in refractory congenital glaucoma. *Ophthalmology* 1997; 104: 996-1001.
24. *Wallace DK, Plager DA, et al*. Surgical results of secondary glaucomas in childhood. *Ophthalmology* 1998; 105: 101-111.
25. *Beck AD, Lynch MG, Noe RL, Buzawa D*. The use of a new laser lens holder for performing laser suture lysis in children. *Arch Ophthalmol* 1995; 113: 140-141.
26. *Rosner B*. Fundamentals of biostatistics. Belmont, California: Wadsworth, 1995: 345-442.
27. *Shaffer RN, Weiss DI*. Congenital and pediatric glaucomas, 1st ed. St Louis: Mosby, 1970: 1-221.
28. *Burke JP, Bowell R*. Primary trabeculectomy in congenital glaucoma. *Br J Ophthalmol* 1989; 73: 186-190.
29. *Debnath SC, Teichmann KD, Salamah K*. Trabeculectomy versus trabeculotomy in congenital glaucoma. *Br J Ophthalmol* 1989; 73: 608-611.
30. *Rao KV, Saj CM, Babu BVN*. Trabeculectomy in congenital glaucoma. *Indian J Ophthalmol* 1984; 32: 439-440.
31. *Costa VP, Willson RP, Moster MR, Schmidt CM*. Hypotony maculopathy following the use of topical mitomycin C in glaucoma filtration surgery. *Ophthalmic Surg* 1993; 24: 389-394.
32. *Al Faran MF, Tomey KF, Al Mutlag FA*. Cyclocryotherapy in selected cases of congenital glaucoma. *Ophthalmic Surg* 1990; 21: 794-798.
33. *Phelan MJ, Higginbotham E*. Contact transscleral Nd: YAG laser cyclophotocoagulation for the treatment of refractory pediatric glaucoma. *Ophthalmic Surg Lasers* 1995; 26: 401-403.
34. *Bock CJ, Freedman SF, Buckley EG, Shields MB*. Transscleral diode laser cyclophotocoagulation for refractory pediatric glaucomas. *J Pediatr Ophthalmol Strabismus* 1997; 34: 235-239.
35. *Molteno ACB, Ancker E, Biljon GV*. Surgical technique for advanced juvenile glaucoma. *Arch Ophthalmol* 1984; 102: 51-57.
36. *Hill RA, Heuer DK, Baerveldt G, Minckler DS, Martone JF*. Molteno implantation for glaucoma in young patients. *Ophthalmology* 1991; 98: 1042-1046.
37. *Netland PA, Walton DS*. Glaucoma drainage implants in pediatric patients. *Ophthalmic Surg* 1993; 24: 723-729.



## SAFETY AND EFFICACY OF TRAVOPROST ADJUNCTIVE TREATMENT IN PAEDIATRIC GLAUCOMA

HELMANOVÁ I., AUTRATA R., ŠENKOVÁ K., ŘEHŮŘEK J.

Department of Paediatric Ophthalmology, Faculty of Medicine, Masaryk University Hospital, Brno

*Received after revision February 2007*

### Abstract

Although medical therapy with ocular hypotensives may delay the need for surgery in some paediatric glaucomas, most patients require repeated surgical interventions. To reach an effective control IOP, children often require a long-term adjunctive glaucoma medication after surgery. Travoprost (Travatan, Alcon) is a prostaglandin analogue reducing intraocular pressure (IOP) via enhancement of uveoscleral outflow, and the IOP-lowering effect has been shown to be additive in combined therapy with other ocular hypotensive agents. The purpose of this study was to evaluate the effectiveness and safety of travoprost therapy in children with glaucoma.

This study was designed as a prospective study of the patients who were administered travoprost at our clinic between January 2002 and December 2005. Seventy-three eyes of 58 paediatric patients with a variety of glaucoma diagnoses were included in the study, and were observed with an average of 28 months (range 18 to 48 months). The mean age of the patients was 7.6 years (range, 8 months to 16 years). Responders were defined as those who had at least a 10% IOP reduction, whereas nonresponders had less than a 10% IOP reduction on travoprost. The baseline IOP was compared with the IOP during the whole time of travoprost therapy for each patient; visual acuity and side effects were noted at each follow-up examination.

The mean pretreatment IOP was  $26.7 \pm 5.9$  mm Hg, whereas the post-treatment IOP was  $21.4 \pm 7.8$  mm Hg. The mean IOP reduction for this group after the addition of travoprost was 11.6% (5.3 mm Hg). Thirty-five patients (52 treated eyes) were responders, with an average IOP reduction of 7.8 mm Hg (30.6 %), whereas 23 patients were nonresponders. In the responders, there was a good correlation between baseline IOP and the magnitude of IOP reduction. The juvenile open-angle glaucoma and aphakic glaucoma were the most common diagnoses in responders and they were older than nonresponders. Systemic and ocular side effects were rarely noted.

Travoprost administration was well tolerated during the study follow-up, with an excellent systemic and ocular safety profile. Travoprost was found as effective in 60% of paediatric patients with primary and secondary glaucoma and combined additive antiglaucoma medications.

### Key word

Paediatric glaucoma, Travoprost, Intraocular pressure

### Abbreviations used

IOP, intraocular pressure; SD, standard deviation; OAG, open-angle glaucoma; JOAG, juvenile open-angle glaucoma

## INTRODUCTION

Prostaglandin analogues are effective ocular hypotensive agents and are being used increasingly in the treatment of elevated intraocular pressure (IOP). Based on dose-response studies they demonstrate a duration of action of 24 hours. Long-term studies demonstrate effective control of IOP with such a dosing schedule; these agents are typically dosed once daily. In a reported comparison between 2 prostaglandin analogues, travoprost provided statistically superior reductions in IOP compared with latanoprost.

Travoprost (Travatan, Alcon), a prostaglandin analogue, reduces intraocular pressure (IOP) via enhancement of uveoscleral outflow. (1,2,3) Travoprost has been shown to decrease the mean IOP in adult glaucoma patients by 10% to 35 %. (4-13) The IOP-lowering effect of this drug has been reported to be additive in combined therapy with other ocular hypotensive agents. (6,12, 13-17) In adults, travoprost is well tolerated and has an acceptable systemic and ocular safety profile. Travoprost may be a useful drug for the treatment of paediatric glaucoma because of its IOP-lowering effect in adults, effectiveness in addition with other antiglaucoma medications, and low occurrence of side effects. Our present study was conducted to evaluate the effectiveness and safety of travoprost administration in paediatric glaucoma.

## MATERIALS AND METHODS

The authors prospectively followed all paediatric glaucoma patients in whom travoprost (0.004 %, Alcon) had been used from January 2002 to December 2005. Seventy-three eyes of 58 paediatric patients with a variety of glaucoma diagnoses were included in the study, and were observed with an average of 28 months (range 18 to 48 months). The mean age of the patients was 7.6 years (range, 8 months to 16 years). Travoprost 0.004 %, 1 drop to the affected eye, was prescribed after baseline IOP was recorded. IOP was measured with Goldmann applanation tonometry, Tonopen, or both depending on the patient's age and co-operation. When Goldmann applanation tonometry was used, duplicate readings were taken on each eye and were averaged. When Tonopen was used, at least 2 readings were averaged for each eye at each examination. If these differed by more than 2 mm Hg, then measurements were repeated with Tonopen so that at least 3, and usually 5, values were available for averaging. The same technique for IOP measurement was used in each given patient. The IOP on travoprost was measured once a week in the first month and then at intervals of 1 to 2 months depending on the IOP and the patient's clinical status. The patients were continued on travoprost without other changes to the medical regimen unless additional medical or surgical interventions were necessary to control the glaucoma. IOP data were evaluated in this study only for eyes that had undergone no surgery for at least 6 months before the addition of travoprost.

Baseline IOP values were compared with IOP values after the addition of travoprost. Patients who showed at least 10% reduction of IOP on travoprost were considered to be "responders". Those who showed less than 10% reduction of IOP were considered to be "nonresponders".

All patients treated with travoprost were included to observe ocular or systemic side effects. Before starting travoprost, the patients and their parents were specifically informed about potential ocular side effects including conjunctival injection, iris colour change, and foreign body sensation. At each clinic visit the patients and their parents were asked about possible systemic side effects including lethargy, sleep disturbances, headache, changes in appetite, and about potential ocular side effects including burning, redness, or changes in iris colour or eyelashes.

The patients who had had unstable or inadequate baseline IOP measurements, underwent surgery within 6 months of starting travoprost, had inadequate follow-up, or had other changes observed simultaneously with the addition of latanoprost were observed for safety data only.

All values are presented by the mean  $\pm$  standard deviation (SD). Statistical comparisons were performed with the use of the Student's *t* test, the Fisher's exact test, the Mann-Whitney's test, and linear regression. The level of statistical significance was set to  $P < 0.05$  for all comparisons.

*Table 1*  
Glaucoma diagnoses and response to travoprost treatment

Diagnosis	Total (n = 73 eyes)	Responders (n = 52 eyes)	Nonresponders (n = 21 eyes)
Congenital glaucoma	19 (26 %)	9	10
JOAG	15 (21 %)	15*	0
Aphakic glaucoma	13 (18 %)	10	3
Infantile glaucoma	6 (8 %)	5	1
Sturge-Weber	5 (7 %)	3	2
Uveitis	4 (5 %)	2	2
Trauma	4 (5 %)	2	2
Steroid glaucoma	4 (5 %)	3	1
Aniridia	3 (4 %)	2	1

\*  $P = .0087$  compared with nonresponders.

## RESULTS

The most common diagnoses were congenital glaucoma, juvenile open-angle glaucoma (JOAG) and aphakic glaucoma.

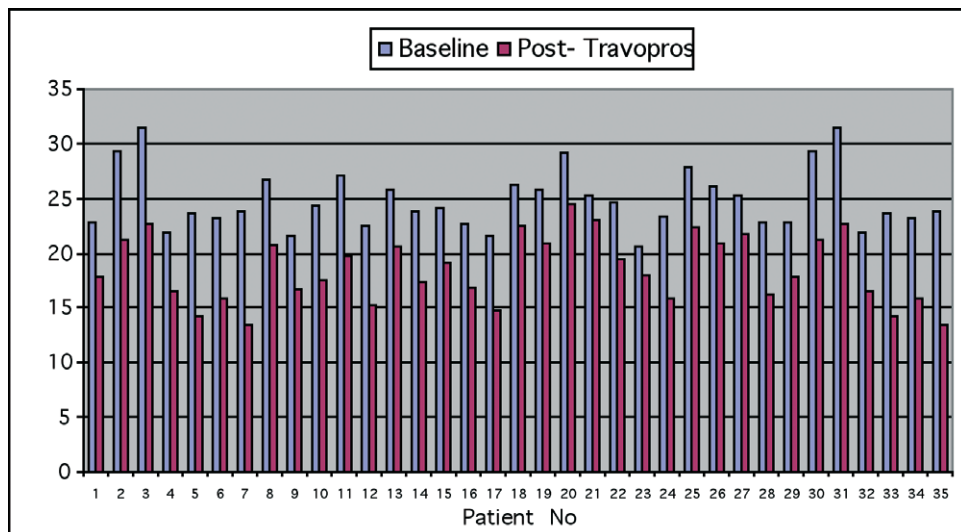
Most patients were taking other glaucoma medications before the addition of latanoprost. Topical beta-blockers and carbonic anhydrase inhibitors were the most common. Other medications included brimonidine, epinephrine, pilocarpine, and topical steroids. Only eleven patients were taking no other medications in the eye treated with latanoprost. Six eyes had undergone 1 to 2 glaucoma surgery, and 4 had undergone cyclocoagulation procedures.

In the 73 eyes in which IOP data could be evaluated, the mean pretreatment IOP was  $26.7 \pm 5.9$  mm Hg (range: 21.5 to 36 mmHg), whereas the post-treatment IOP was  $21.4 \pm 7.8$  mm Hg (range: 12 to 30 mmHg).

The mean IOP reduction for this group after the addition of latanoprost was 9.2% (2.3 mm Hg). Thirty-five patients (52 eyes) were responders, with an average IOP reduction of 7.8 mm Hg (30.6 %), whereas 23 patients (30 eyes) were nonresponders. In the responders, there was a good correlation between baseline IOP and the magnitude of IOP reduction.

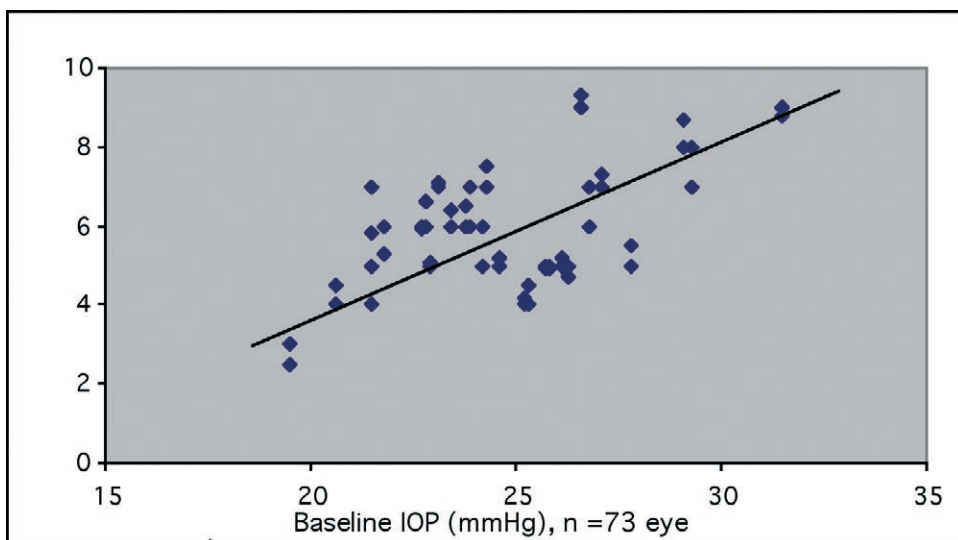
The average pretreatment IOP was similar for the responders and nonresponders:  $25.7 \pm 4.6$  mm Hg (range: 21.5 to 33 mmHg) and  $26.9 \pm 5.5$  mm Hg (range: 22 to 36 mmHg), respectively. The average post-treatment IOP for the responders was  $17.4 \pm 3.1$  mm Hg (range: 14 to 23 mmHg), compared with  $26.5 \pm 6.8$  mm Hg (range: 22.5 to 37 mmHg) for the nonresponders. The average IOP reduction in travoprost responders was  $7.8 \pm 3.9$  mm Hg ( $31.5\% \pm 15.7\%$ ;  $P = 0.0048$ ). *Fig. 1* presents the effect of travoprost on IOP in the responders.

All eyes were followed for side effects over the duration of their treatment with travoprost. The reported side effects included transient conjunctival redness (3 patients), unspecified irritation (2 patients), sleep disturbance (2 patients), and increased eyelash thickness and pigmentation (1 patient). No iris colour changes were noted.



*Fig. 1*  
Travoprost responders. Baseline IOP and IOP at final examination on travoprost treatment for each eye.





*Fig. 2*

Correlation of baseline IOP and magnitude of IOP reduction. Baseline IOP is plotted against IOP reduction on travoprost therapy for each of the 73 eyes. Linear regression yields a correlation coefficient of 0.86.

There was a significant difference in the mean age of responders and nonresponders ( $P=0.038$ ). The mean ages of the responders and nonresponders were  $12.3 \pm 4.1$  years (range, 8.8 to 16 years) and  $5.4 \pm 4.6$  years (range, 0.72 to 12.7 years), respectively. The responders were significantly more likely to have a diagnosis of JOAG than the nonresponders ( $P = 0.0087$ ). There were no statistically significant differences in the frequency of other diagnoses between responders and nonresponders.

In addition, there were no significant differences between responders and nonresponders with respect to the number of glaucoma medications and the number of glaucoma surgeries.

## DISCUSSION

Travoprost, a prostaglandin analogue, is one of the most effective hypotensive agents for the treatment of adult patients with open-angle glaucoma (OAG) and ocular hypertension. (4,5,7-11) In adults with ocular hypertension and glaucoma who take no other medications, travoprost reduces the mean IOP by 20 % to 35 %. (4,7,8,10,11) In our group of children with no other glaucoma medications (17 eyes), travoprost reduced IOP by a mean of 14.6 %.

Combined with other glaucoma medications, travoprost has been reported to cause additional IOP reductions of 10 % to 41 %. (12) In adult patients, in whom

travoprost was added to the current medication regimen, travoprost caused a mean additional IOP reduction of at least 15.9 %, with a 20 % or more reduction of IOP in at least one third of patients. (9) In our paediatric glaucoma patients, who were receiving travoprost in addition to other glaucoma medications, we noted a mean IOP reduction of 11.7 %.

In contrast to the reported adult studies, our results suggest that travoprost used either alone or in addition to other antiglaucoma medications is not as effective at lowering IOP in our paediatric patients with various types of glaucoma.

Our study suggests that travoprost does have a substantial ocular hypotensive effect in children with JOAG. Half of the patients with aphakic glaucoma also responded to travoprost. The mean age of the responders exceeded that of the nonresponders. In the responders, there was a good correlation between baseline IOP and the magnitude of IOP reduction, as has been reported in adult patients with travoprost medication. (3, 4) It is unclear why our group of children did not respond to travoprost as well as reported for adults with OAG. Travoprost is thought to work by increasing uveoscleral outflow (1,2,3) via relaxation of the ciliary muscle (18,19) and remodelling of the connective tissue in the ciliary muscle bundles. Perhaps the uveoscleral outflow pathways in children are different from those of adults and do not respond in the same manner to travoprost. Patients with JOAG may have a mechanism of glaucoma that is more similar to that of adults with OAG, and thus be more responsive to travoprost than children with other glaucoma types. Responders tended to be older than nonresponders in our study.

The systemic safety of travoprost appears very good in both children and adults. As in the multicentre trials that compared travoprost with timolol in adults, (7,10,11) ocular side effects in our study group were uncommon. Five from our patients experienced transient conjunctival redness on travoprost. Three patients reported increased lash pigmentation and thickness.

Hyperpigmentation and hypertrichosis of lashes has been reported in adult patients treated with travoprost. The ability of travoprost, like other prostaglandins, to act as a growth factor has been suggested to explain this phenomenon. Increased iris pigmentation has been noted as a side effect of travoprost in adult patients. The multicentre trials of travoprost in adults include ocular photographs in their protocols and found iris pigment changes in 3 % to 10 % of patients on travoprost for 6 months. (7,10,11) No iris colour changes were noted by the clinicians, patients, or parents in our study. Other reported adverse effects of travoprost and latanoprost have included cystoid macular oedema, facial rash, and hypotonia with choroidal effusions, all occurring within 1 to 4 weeks of beginning latanoprost treatment. These were not observed in our study, but might occur if children were treated with travoprost for longer time periods.

The results of the pilot study (20) suggest that travoprost produces reductions in IOP that may be sustained for up to 84 hours after dosing. The results of the follow-up study suggest that both prostaglandin analogues significantly lower IOP from the

baseline in patients with open-angle glaucoma and provide excellent diurnal IOP control throughout a 24-hour period (20).

A comparative study (21) of travoprost 0.004% and brinzolamide 0.1% concomitant therapy showed a greater efficacy than the fixed latanoprost 0.005% /timolol 0.5% combination in terms of absolute IOP decreases in adult glaucoma. Travoprost/brinzolamide therapy also offered the advantages of a greater percentage of responders. (21) The results of a prospective comparative study of these ocular hypotensive combination in paediatric glaucoma over a three-year period of follow-up at our clinic will be presented next year.

In conclusion, the systemic and ocular safety of travoprost in our study appeared excellent, but travoprost was not as effective in our group of paediatric glaucoma patients as it had been reported to be in adults with OAG. However, in our patients with JOAG and older, travoprost showed an acceptable ocular hypotensive effect.

#### REFERENCES

1. Gabelt BT, Kaufman PL. Prostaglandin F<sub>2</sub> increases uveoscleral outflow in the monkey. *Exp Eye Res* 1989; 49: 389-402.
2. Nilsson SFE, Samuelsson M, Bill A, Stjernschantz J. Increased uveoscleral outflow as a possible mechanism of ocular hypotension caused by prostaglandin F<sub>2</sub> 1-isopropylester in the monkey. *Exp Eye Res* 1989; 48: 707-716.
3. Toris CB, Camras CB, Yablonski ME. Effects of PhXA41, a new prostaglandin F<sub>2</sub> analog, on aqueous humor dynamics in human eyes. *Ophthalmology* 1993; 100: 1297-1304.
4. Rulo AH, Greve EL, Geijssen H, Hoyng PF. Reduction of intraocular pressure with treatment of latanoprost once daily in patients with normal-pressure glaucoma. *Ophthalmology* 1996; 103: 1276-1282.
5. Mishima HK, Masuda K, Kitazawa Y, Azuma I, Araie M. A comparison of latanoprost and timolol in primary open-angle glaucoma and ocular hypertension: a 12-week study. *Arch Ophthalmol* 1996; 114: 929-932.
6. Alm A, Widengard I, Kjellgren D, Soderstrom M, Fristrom B, Heijl A, et al. Latanoprost administered once daily caused a maintained reduction of intraocular pressure in glaucoma patients treated concomitantly with timolol. *Br J Ophthalmol* 1995; 79: 12-16.
7. Camras C., The United States Latanoprost Study Group. Comparison of latanoprost and timolol in patients with ocular hypertension and glaucoma: a six-month, masked, multicenter trial in the United States. *Ophthalmology* 1996; 103: 138-147.
8. Lusk M, Ticho U, Glovinsky J, Weinberger D, Nesher R, Yassur Y, et al. A comparative study of two dose regimens of latanoprost in patients with elevated intraocular pressure. *Ophthalmology* 1997; 104:1720-1724.
9. Patelska B, Greenfield D, Liebmann J, Wand M, Kusknick H, Ritch R. Latanoprost for uncontrolled glaucoma in a compassionate case protocol. *Am J Ophthalmol* 1997; 124: 279-286.
10. Watson P, Stjernschantz J. The Latanoprost Study Group. A six-month, randomized, double-masked study comparing latanoprost with timolol in open-angle glaucoma and ocular hypertension. *Ophthalmology* 1996; 103: 126-137.
11. Alm A, Stjernschantz J. The Scandinavian Latanoprost Study Group. Effects on intraocular pressure and side effects of 0.005% latanoprost applied once daily, evening or morning: a comparison with timolol. *Ophthalmology* 1995; 102: 1743-1752.
12. Hoyng PF, Rulo A, Greve E, Watson P, Alm A. The additive intraocular pressure-lowering effect of latanoprost in combined therapy with other ocular hypotensive agents. *Surv Ophthalmol* 1997; 41(suppl):93-98.
13. Rulo AH, Greve EL, Hoyng PF. Additive ocular hypotensive effect of latanoprost and acetazolamide: a short-term study in patients with elevated intraocular pressure. *Ophthalmology* 1997; 104: 1503-1507.
14. Fristrom B, Nilsson SEG. Interaction of PhXA41, a new prostaglandin analogue, with pilocarpine: a study on patients with elevated intraocular pressure. *Arch Ophthalmol* 1993; 111: 662-665.

15. *Rulo AH, Greve EL, Hoyng PF*. Additive effect of latanoprost, a prostaglandin F2 analogue, and timolol in patients with elevated intraocular pressure. *Br J Ophthalmol* 1994; 78: 899-902.
16. *Villumsen J, Alm A*. Effect of the prostaglandin F2 analogue PhXA41 in eyes treated with pilocarpine and timolol [abstract]. *Invest Ophthalmol Vis Sci* 1992; 33(suppl):1248.
17. *Linden C, Alm A*. Latanoprost and physostigmine have mostly additive ocular hypotensive effects in human eyes. *Arch Ophthalmol* 1997; 115: 857-861.
18. *Poyer JF, Millar C, Kaufman PL*. Prostaglandin F2 effects on isolated rhesus monkey ciliary muscle. *Invest Ophthalmol Vis Sci* 1995; 36: 2461-2465.
19. *Van Alphen GWHM, Wilhelm PB, Elsensfeld PW*. The effect of prostaglandins on the isolated internal muscles of the mammalian eye, including man. *Doc Ophthalmol* 1977; 42:397-415.
20. *Dubinger HB, Sircy MD, Landry T, et al*. Comparison of the diurnal ocular hypotensive efficacy of travoprost and latanoprost over a 44-hour period in patients with elevated intraocular pressure. *Clinical Therapeutics* 2004; 26:84-91.
21. *Martinez-de-la-Casa JM, Castillo A, Garcia-Feijoo J, et al*. Concomitant administration of travoprost and brinzolamide versus fixed latanoprost/timolol combined therapy: three-month comparison of efficacy and safety. *Current Medical Research and Opinions* 2004; 20,9: 1333-1339.

## COMBINATION OF LASER PHOTOCOAGULATION AND CRYOTHERAPY FOR THRESHOLD RETINOPATHY OF PREMATURITY DURING ONE SURGICAL PROCEDURE

ŠENKOVÁ K., AUTRATA R., HOLOUŠOVÁ M., ŘEHŮŘEK J.

Department of Paediatric Ophthalmology, Faculty of Medicine, Masaryk University Hospital, Brno

*Received after revision February 2007*

### Abstract

To report on the structural, functional, and refractive outcome, the safety and effectiveness of combined cryotherapy and diode laser indirect photocoagulation in the treatment of threshold retinopathy of prematurity (ROP).

Medical records of patients developing threshold ROP between 1995 to 2003 were reviewed to identify those treated with combined cryotherapy and photocoagulation and followed up for at least 4 years postoperatively. Ninety-four consecutive patients who had undergone combined procedure were examined for this noncomparative, interventional, retrospective case series. A total of 172 eyes received combined treatment. Data consisted of the grade of ROP pre- and postoperatively, most recent fundus examination, birthweight, visual acuity, complications, and refraction. Diode laser was used to ablate posterior avascular retina, and cryotherapy was used for anterior retina.

In 94 patients, 172 eyes received combined treatment. A total of 149 (87 %) of all eyes responded to combined treatment and had favourable anatomic outcome at the last examination. In 131 of all eyes (76 %), the functional outcome was favourable (visual acuity better than 20/200) at the last examination. In 18 eyes, which progressed to IV B stage, encircling procedures were performed. Perioperative complications included haemorrhages in 26 % of eyes, which resorbed spontaneously. No other intraoperative complications occurred. The mean duration of treatment was  $31 \pm 12$  minutes/eye. A mean of  $132 \pm 74$  laser burns/eye were applied. At the final visit (4 to 12 years) or later, 115 of all eyes (66.8 %) refracted were myopic, of which 26 (22.5 %) had high myopia over -6 dioptres.

Combined cryotherapy and diode laser photocoagulation for ROP in our patients resulted in regression of threshold ROP with relatively successful structural and functional outcomes. Combined therapy may be faster and useful for eyes with very posterior ROP. This may decrease the number of complications occurred when excessive cryotherapy or laser photoablation must be used in Zone 1 ROP.

### Key words

Retinopathy of prematurity, Diode laser photocoagulation, Cryotherapy

### Abbreviations used

ROP, retinopathy of prematurity; D, dioptres

## INTRODUCTION

Both transscleral cryotherapy and transpupillary diode laser photocoagulation have been shown to be effective in the treatment of threshold ROP (1-9). Cryotherapy, studied extensively as a treatment for threshold ROP in a large cohort of neonates in the Multicentre Trial of Cryotherapy for Retinopathy of Prematurity, was found to reduce the risk of an unfavourable outcome in threshold ROP from 45.4% in the untreated group to 26.1% in the treated group (2). In recent years, laser photocoagulation has gained increasing popularity for the treatment of threshold ROP (5,6,13).

Each modality has its particular advantages and disadvantages. The effectiveness of cryotherapy was proved in the largest multicentre randomised controlled trial of ROP treatment to date (1,2). A mean of only 50 applications were required to ablate the avascular retina, depending on the location (zone) of ROP (1). The treatment is not hindered by decreased media clarity to the same extent as transpupillary laser photocoagulation. However, cryotherapy can cause considerable damage to nontarget tissues such as conjunctiva, sclera, choroid, and macula (3,10,11). Beyond potential long-term sequelae, such damage may be acutely associated with more inflammation and pain, requiring general anaesthesia to be administered to frail infants (1). Cryotherapy is difficult to apply to the posterior retina and may require opening of the conjunctiva (1-9).

Laser photocoagulation is effective as cryotherapy in decreasing unfavourable anatomic outcomes from ROP (3-9). In addition, tissue destruction is more localised, and many studies report better postoperative visual acuity, (3,4,9,12) compared with cryotherapy as well as a lower incidence and severity of myopia (12,13). Laser treatment is easier to apply to the posterior retina than is cryotherapy. However, transpupillary photocoagulation is more difficult to apply anteriorly, especially in the presence of a small pupil or unclear media, typically caused by limbal corneal pannus, tunica vasculosa lentis, or vitreous haze. A mean number of 900 to 1600 laser applications are required to ablate the avascular retina; (3,4) therefore treatment duration may be prolonged compared with that of cryotherapy, possibly with greater stress on the infant or requiring longer anaesthesia. Laser energy is transmitted through the ocular media with an attendant risk of cornea, iris, or lens burns (15). In addition, it has recently been postulated that when a large number of burns are required to treat posterior disease, anterior segment ischaemia may occur, resulting in an extremely poor visual prognosis (16).

Combining the use of laser photocoagulation with cryotherapy for the treatment of threshold ROP may provide complementary advantages of each modality while tempering the disadvantages of each. Cryotherapy could be used to treat anteriorly and laser to treat posteriorly, with greater technical ease, shorter treatment duration, and perhaps decreased risk of cataract or anterior segment ischaemia. To our knowledge, such combination therapy has only been reported once before (18). We

report on our experience with the safety, efficiency, and effectiveness of combining cryotherapy and diode laser photocoagulation for the treatment of threshold ROP.

## METHODS

In this retrospectively analysed case series, the medical records of all patients treated for threshold ROP between January 1995 and December 2003 were reviewed, and 94 cases with combined laser + cryo treatment were identified. The mean gestational age was  $26.7 \pm 2$  weeks (range, 23 to 33), and the mean birthweight was  $865 \pm 132$  g (range, 580 to 1350g). The mean postnatal age at the time of treatment was  $10 \pm 1.5$  weeks (range, 8 to 13), corresponding to a mean postconceptional age at treatment of  $36.5 \pm 1.3$  weeks (range, 33 to 39). All treated eyes had threshold ROP as defined by the International Committee for the Classification of Retinopathy of Prematurity (19). Fifty-four eyes had threshold zone 1 disease, and the remaining 118 eyes had a mean of  $8 \pm 3$  clock hours (range, 7 to 12) of stage 3+ disease in posterior zone 2. For purposes of comparison with other reports, Snellen visual acuity was estimated from fixation behaviour using the criteria applied by *Payse et al* (3) and *Repka*. (5) Cryotherapy was applied to the avascular retina as far posteriorly as possible without opening the conjunctiva. In all patients, a posterior row of cryotherapy was applied 360° using red reflex monitoring. Additional cryotherapy was placed anteriorly with indirect ophthalmoscopy visualisation. Generally, two rows or approximately 20 applications were necessary. The skip areas between cryotherapy spots were filled in with laser application. Diode laser photocoagulation was then applied to the remaining area of the avascular retina, titrated to a grey-white burn (200 to 500 mW, 0.5 seconds for all patients).

Safety was assessed by reviewing ocular and systemic complications. Efficiency was assessed by recording treatment duration and the number of laser burns required, by fundus examination, visual acuity, and refraction at the most recent follow-up visit. Using criteria defined by the Cryotherapy for Retinopathy Prematurity Co-operative Group Study (2), an unfavourable outcome was defined as (1) a posterior retinal fold, (2) a retinal detachment involving zone 1 of the posterior pole, or (3) a retrolental tissue or mass obscuring the view of the posterior pole. Visual acuity outcomes were defined as favourable if the estimated visual acuity was better than 20/200 or unfavourable if visual acuity was less than 20/200.

*Table 1*  
Demographics, combined procedure Laser + Cryo

	Laser + cryo (N = 94 patients)		
	Mean	Minimum	Maximum
EGA (wk)	26.7	23.0	33.0
Birthweight (g)	865.0	580.0	1350.0
PCA-ROP onset (wk)	33.8	29	37
PCA-threshold (wk)	36.5	31.5	41.0

*Table 2*  
Treatment parameters, combined procedure Laser + Cryo

	Laser			Cryo		
	Mean	Minimum	Maximum	Mean	Minimum	Maximum
Number of spots	132	80	355	42.3	12	67
Power (mW)	278	200	500			
Duration (ms)	500	500	500			

## RESULTS

Patients were followed up for a mean of  $6.53 \pm 4.38$  years (range, 4 to 11 years) after surgery. All patients experienced transient conjunctival injection and chemosis, but no other ocular complications were noted.

Treatment required a mean of  $33 \pm 11$  minutes/eye (range, 21 to 53) – including all examinations and interruptions – from the time the patient received sedation until the eyelid speculum was removed. The treatment time per eye for bilaterally treated patients was estimated by dividing the total documented time by two. A mean of  $132 \pm 74$  laser burns (range, 80 to 355) were required after cryotherapy to achieve near-confluent ablation of the avascular retina.

The findings at the patients' most recent dilated fundus examination are summarised in *Table 3*. Using the criteria defined by the Cryotherapy for Retinopathy of Prematurity Co-operative Group (2), a favourable outcome was achieved in 149 of 172 eyes (87 %).

*Table 3*  
Anatomic outcome (n = 172 eyes)

Anatomic Outcome	No. (%)
Normal posterior pole	127 (72.5 %)
Straightened temporal vessels	8 (4.7 %)
Macular ectopia	7 (4.1 %)
Abnormal macular pigmentation	7 (4.1 %)
Stage IVb	9 (5.2 %)
Stage V	10 (5.8 %)

Visual acuity is summarised in *Table 4*. In all cases, visual acuity was assessed by testing fixation behaviour (20). All of the eyes with normal vision had normal posterior poles on fundus examination.



*Table 4*  
Functional outcome at final examination (n = 172 eyes)

<b>Functional Outcome</b>	<b>No. (%)</b>
Visual acuity better than 20/200	131 (76 %)
Vision not measured	8 (4.7 %)
Fixation central, steady, unmaintained	6 (3.5 %)
Monocular nystagmus	8 (4.7 %)
Hand motions only	8 (4.7 %)
No light perception	12 (7 %)

Eight eyes did not have visual acuity documented in the chart, but all of these eyes had normal posterior pole anatomy, which has been reported to correlate well with normal visual acuity in ROP (21). 149 of 172 measured eyes (87 %) had a favourable functional outcome. Estimated visual acuity better than 20/200 was recorded in 131 (76 %) of all analysed eyes.

All eyes were refracted at 12 months or later. Five eyes were not refracted because of retinal detachment, and 6 eyes were not followed up until 12 months. The distribution of refractive errors is illustrated in *Table 6*. The mean spherical equivalent after cycloplegia using 1 % cyclopentolate was  $-5.45 \pm 4.32$  dioptres (D) (range,  $-12.50$  to  $+6.50$  D). At the final visit, 116 of 172 eyes (67.4 %) were myopic, and 26 of 172 eyes (15.1 %) were highly myopic ( $> 6$  dioptres).

*Table 5*  
Postoperative complications of combined Laser + Cryo treatment  
N=172 eyes n (%)

Corneal oedema	12 (%)
Anterior segment ischaemia	3 (76 %)
Posterior synechiae	7(4.7 %)
Cataract	9 (3.5 %)
Hyphaema	7 (4.7 %)
Vitreous haemorrhage	13 (4.7 %)
Retinal-choroidal haemorrhage	11(7 %)

*Table 6*  
Refraction (spherical equivalent) (n=172 eyes) n (%)

Hypermetropia > +6.0 D	9 (5.2 %)
Hypermetropia +3.0 to +6.0 D	18 (10.5 %)
Hypermetropia <+3.0 D	29 (17 %)
Myopia < -3.0 D	46 (26.7 %)
Myopia - 3.0 to - 6.0 D	44 (25.6 %)
Myopia > - 6.0 D	26 (15.1 %)

## DISCUSSION

Combined use of cryotherapy and laser photocoagulation has been reported previously to be effective. (18) In this study we add our experience with 94 additional patients.

Combination therapy appeared to be safe. No serious ocular or systemic complications occurred in this group of patients, although the incidence of cataract formation after transpupillary laser photocoagulation for ROP may be as high as 6 %. (15) *Lambert et al* (16) recently described 10 eyes that developed dense cataracts postulated to be secondary to anterior segment ischaemia after extensive laser photocoagulation for ROP. Nine of these 10 eyes progressed to phthisis bulbi and no light perception. (16) The investigators theorised that the risk of cataract may increase with the number of laser burns required, whether the cataract is caused by direct thermal injury to the lens or it results from anterior segment ischaemia. (16) The eyes in their study required a higher number of laser burns (2,532 burns) for ROP than did eyes in other series, partly because of the relatively posterior location of the disease. (16). In our study, only 216 laser burns were required despite the posterior location of the ROP. *Lambert et al* (16) suggested that cryotherapy should be added to the treatment regimen when ROP is located relatively posteriorly because freezing causes less damage to ocular vessels than does photocoagulation (16). A rabbit model developed by *Freeman et al* (17) also suggests that cryotherapy is less likely to produce anterior segment ischaemia than photocoagulation (17).

As noted by *Azad et al* (22) cryotherapy is less time-consuming than laser photocoagulation in that a much larger area of retina is ablated per application. We estimate that 50-diode laser burns are necessary to cover the same retinal area covered by one cryotherapy application. Using cryotherapy alone requires only 40 to 50 applications per eye, (1,3) whereas studies using laser alone reported a mean number of 956 to 1,556 burns required (3,14). The treatment of our patients required a mean of 132 laser burns/eye after cryotherapy. Therefore, using laser alone is likely more time-consuming than combination therapy, which may lead to longer

anaesthesia time and a greater risk of laser-related complications.

The favourable anatomic outcome rate was 87 %, which compares favourably with the results reported after cryotherapy alone (74.3 %) or laser alone (91.6 %) (8). The favourable functional outcome rate was 76 %, which also compares well with the results reported after cryotherapy alone (65 %) (2). Some studies suggest superior visual acuity outcomes after laser photocoagulation compared with cryotherapy, but these studies are either small or do not compare concurrently treated groups (nonrandomised) (3-5). Potentially confounding variables include (1) the possibility of an effect on the overall improvement in the systemic management of premature infants during the time period of these studies, and (2) a different length of follow-up between the groups.

The studies by the Cryotherapy for Retinopathy of Prematurity Co-operative Group reported that functional outcome is strongly correlated with visible posterior pole changes. (21) Macular pigment changes associated with markedly decreased vision have been reported in 10 % to 34 % of eyes after cryotherapy for ROP (3,11). We observed macular pigmentary changes in 7 eyes, possibly because we did not apply cryotherapy as far posteriorly or to as large an extent as described in one of the reports (11).

The high incidence of myopia (67.4 %) and severity of myopia (15.1 %) with the incidence of myopia > 6 dioptres in this study are similar to what others have reported after using cryotherapy alone (2,13,23). Two groups of investigators have reported, in small nonrandomised studies, that cryotherapy is associated with a higher incidence and severity of postoperative myopia than is laser treatment (12,13).

The patients in this study may have been predisposed to severe myopia because of the posterior location of their ROP. It is well recognised that the incidence and severity of myopia correlate with the severity of ROP regardless of the treatment modality employed. There is selection bias in this study toward eyes with more posterior disease because eyes with more eyes with anterior disease were treated with cryotherapy alone rather than with combination therapy.

In conclusion, combined cryotherapy and diode laser photocoagulation for ROP in our patients resulted in regression of threshold ROP with relatively successful structural and functional outcomes. Combined therapy may be faster and useful for eyes with very posterior ROP. This may decrease the number of complications occurred when excessive cryotherapy or laser photoablation must be used in Zone 1 ROP.

## REFERENCES

1. Cryotherapy for Retinopathy of Prematurity Cooperative Group. Multicenter trial of cryotherapy for retinopathy of prematurity. Three-month outcome. *Arch Ophthalmol* 1990; 108: 195-204.
2. Cryotherapy for Retinopathy of Prematurity Cooperative Group. Multicenter trial of cryotherapy for retinopathy of prematurity. One-year outcome — structure and function. *Arch Ophthalmol* 1990; 108: 1408-1416.
3. *Paysse EA, Lindsey JL, Coats DK, Contant CF Jr, Steinkuller PG.* Therapeutic outcomes of cryotherapy versus transpupillary diode laser photocoagulation for threshold retinopathy of prematurity. *J AAPOS* 1999; 3: 234-240.
4. *Connolly BP, McNamara JA, Sharma S, Regillo CD, Tasman W.* A comparison of laser photocoagulation with trans-scleral cryotherapy in the treatment of threshold retinopathy of prematurity. *Ophthalmology* 1998; 105: 1628-1631.
5. *White JE, Repka MX.* Randomized comparison of diode laser photocoagulation versus cryotherapy for threshold retinopathy of prematurity: 3-year outcome. *J Pediatr Ophthalmol Strabismus* 1997; 34: 83-87.
6. *Hunter DG, Repka MX.* Diode laser photocoagulation for threshold retinopathy of prematurity. A randomized study. *Ophthalmology* 1993; 100: 238-244.
7. *Seiberth V, Linderkamp O, Vardarli I, Knorz MC, Liesenchoff H.* Diode laser photocoagulation for stage 3+ retinopathy of prematurity. *Graefes Arch Clin Exp Ophthalmol* 1995; 233: 489-493.
8. Laser ROP Study Group. Laser therapy for retinopathy of prematurity. *Arch Ophthalmol* 1994; 112: 154-156.
9. *Connolly BP, McNamara JA, Regillo CD, Tasman W, Sharma S.* Visual outcomes after laser photocoagulation for threshold retinopathy of prematurity. *Ophthalmology* 1999; 106: 1734-1737.
10. *Vrabec TR, McNamara JA, Eagle RC Jr, Tasman W.* Cryotherapy for retinopathy of prematurity: a histopathologic comparison of a treated and untreated eye. *Ophthalmic Surg* 1994; 25: 38-41.
11. *Saito Y, Hatsukawa Y, Lewis JM, Koike H, Omoto T, Tano Y.* Macular coloboma-like lesions and pigment abnormalities as complications of cryotherapy for retinopathy of prematurity in very low birth-weight infants. *Am J Ophthalmol* 1996; 122: 299-308.
12. *O'Keefe M, O'Reilly J, Lanigan B.* Longer-term visual outcome of eyes with retinopathy of prematurity treated with cryotherapy or diode laser. *Br J Ophthalmol* 1998; 82: 1246-1248.
13. *Laws F, Laws D, Clark D.* Cryotherapy and laser treatment for acute retinopathy of prematurity refractive outcomes, a longitudinal study. *Br J Ophthalmol* 1997; 81: 12-15.
14. *Banach MJ, Ferrone PJ, Trese MT.* A comparison of dense versus less dense diode laser photocoagulation patterns for threshold retinopathy of prematurity. *Ophthalmology* 2000; 107: 324-327.
15. *Christiansen SP, Bradford JD.* Cataract in infants treated with argon laser photocoagulation for threshold retinopathy of prematurity. *Am J Ophthalmol* 1995; 119: 175-180.
16. *Lambert SR, Capone A Jr, Cingle KA, Drack AV.* Cataract and phthisis bulbi after laser photocoagulation for threshold retinopathy of prematurity. *Am J Ophthalmol* 2000; 129: 585-591.
17. *Freeman HM, Hawkins WR, Schepens CL.* Anterior segment necrosis. An experimental study. *Arch Ophthalmol* 1966; 75: 644-650.
18. *Laatikainen L, Mattila J, Karna J.* Combined use of argon laser photocoagulation and cryotherapy in the treatment of retinopathy of prematurity. *Acta Ophthalmol Scand* 1995; 73: 333-335.
19. The Committee for the Classification of Retinopathy of Prematurity. An international classification of retinopathy of prematurity. *Arch Ophthalmol* 1984; 102: 1130-1134.
20. *Stout AU, Wright KW.* Pediatric eye examination. In: *Pediatric ophthalmology and strabismus*, ed Wright KW. Mosby, St. Louis (Mo); 1995: 63-72.
21. *Gilbert WS, Dobson V, Quinn GE, Reynolds J, Tung B, Flynn JT.* Cryotherapy for Retinopathy of Prematurity Cooperative Group. The correlation of visual function with posterior retinal structure in severe retinopathy of prematurity. *Arch Ophthalmol* 1992; 110: 625-631.
22. *Azad RV, Kumar H, Al Ajmi M, Al Essa M, Rashwan N.* Cryo for zone-1 ROP: a viable option. *J Pediatr Ophthalmol Strabismus* 1999; 36: 307-308.
23. *Choi MY, Park IK, Yu YS.* Long term refractive outcome in eyes of preterm infants with and without retinopathy of prematurity: comparison of keratometric value, axial length, anterior chamber depth, and lens thickness. *Br J Ophthalmol* 2000; 84: 138-143.
24. *Knight-Nanan DM, O'Keefe M.* Refractive outcome in eyes with retinopathy of prematurity treated with cryotherapy or diode laser: 3 year follow up. *Br J Ophthalmol* 1996; 80: 998-1001.

## CONGENITAL BROWN'S SYNDROME: SURGICAL OUTCOMES OF SILICONE EXPANDERS FOR SUPERIOR OBLIQUE *TENDON*

AUTRATA R., VODIČKOVÁ K., ŠENKOVÁ K., PELLAROVÁ H., ŘEHŮŘEK J.

Department of Paediatric Ophthalmology, Faculty of Medicine,  
Masaryk University Hospital, Brno

*Received after revision January 2007*

### Abstract

Brown's syndrome is typically characterised as an absence or severe limitation of elevation in adduction with divergence in upgaze and forced ductions showing an obvious mechanical restriction on attempts to elevate the adducted eye. The aetiology of Brown's syndrome appears to be multifactorial, and many theories have been proposed, including superior oblique tendon sheath and sleeve anomalies, a tight superior oblique tendon, and developmental anomalies of the trochlea. Superior oblique tendon-lengthening procedure using a silicone "expander" inserted within the tendon may improve the predictability of surgical outcome. The purpose of our retrospective review is to report on the effectiveness of the superior oblique tendon expander procedure for correcting congenital Brown's syndrome.

Medical records of 23 consecutive patients with severe congenital Brown's syndrome treated between 1995 and 2004 were evaluated retrospectively. Preoperative and postoperative extraocular motility patterns were analysed, and the final results were graded (excellent, good, fair, poor-undercorrected, and poor-overcorrected). All of the patients had a hypotropia > 20 prism dioptres in primary position. A superior oblique tendon lengthening procedure, using an 8- to 12-mm-long silicone band, was performed on each patient. A paired-sample Student's *t*-test was used to analyse the improvement in primary-position hypotropia between the first and last postoperative examinations.

As of the last recorded follow-up examination (mean, 61 months), 12 patients had an excellent result, five had a good result, four had a fair result, and two had a poor result. All the patients experienced an improvement in their severe Brown's syndrome, with 100% showing a postoperative primary-position hypotropia < 8 prism dioptres. Postoperative limitation of elevation in adduction was either -1 or -2 for 19 patients. Two patients required further surgery, and no extrusions of the implants were noted.

The superior oblique tendon expander procedure appears to be an effective and safe method in the surgical treatment of severe Brown's syndrome. A shorter band should be considered for Brown's syndrome patients with less hypotropia in primary position. The use of a large-segment (8- to 12-mm) band is appropriate for the correction of patients with primary-position hypotropia of more than 16–20 prism dioptres.

### Key words

Congenital Brown's syndrome, Superior oblique tendon, Silicone expanders

## INTRODUCTION

The Brown's syndrome is typically described as the absence or severe limitation of elevation in adduction with divergence in upgaze and forced ductions showing a mechanical restriction on attempts to elevate the adducted eye. (1) The aetiology of Brown's syndrome appears to be multifactorial, and many theories have been proposed, including superior oblique tendon sheath and sleeve anomalies, (2) a tight superior oblique tendon, (3) impaired slippage of the superior oblique tendon through the trochlea, and developmental anomalies of the trochlea. (4)

In 1991, *Wright* (5) proposed a novel approach to surgery for Brown's syndrome. He described a superior oblique tendon-lengthening procedure using a silicone "expander" inserted within the tendon as a way to improve the predictability of surgical outcome. This procedure gained increasing popularity in the past decade. (6) The goal of this retrospective review is to report the effectiveness and safety of the superior oblique tendon expander procedure for the correction of severe congenital Brown's syndrome in the long-term follow-up.

## PATIENTS AND METHODS

The medical records of 23 consecutive patients with severe congenital Brown's syndrome were evaluated retrospectively. All of the patients underwent a superior oblique tendon silicone expander procedure using a large 8- to 12-mm segment. The 23 patients (10 male and 14 female) ranged in age between 4 and 21 years (average, 11; median, 8). No patient had a history of strabismus surgery. All the 23 patients exhibited a manifest hypotropia in all positions of gaze before surgery. The initial postoperative evaluation was always performed 2 weeks after surgery. Subsequent evaluations were done approximately every 3 months. The minimum follow-up period was 24 months. *Table 1* demonstrates our grading system for the limitation of elevation in adduction in. *Table 2* summarises the preoperative and postoperative distance deviations in primary position as well as the preoperative and postoperative limitations of elevation in adduction for each patient. All patients had a severe form of congenital Brown's syndrome.

*Table 1*  
Grading system for assessing elevation in adduction

Grade for elevation limitation in adduction (PD)	Elevation in adduction measured from the horizontal plane (degrees)
-4	Downshoot in adduction ( $< 0^\circ$ )
-3	$1^\circ - 20^\circ$
-2	$21^\circ - 35^\circ$
-1	$36^\circ - 50^\circ$

PD, prism dioptres

We defined a severe congenital Brown's syndrome as a -4 limitation of elevation in adduction with a hypotropia in primary position ranging from 20 to 40 prism dioptres and a downward displacement of the affected eye on adduction. The patient's head position was controlled for all measurements. The classified postoperative results were "excellent," "good," "fair," or "poor" (undercorrected or overcorrected) per grading method of *Stager et al* (7). An **excellent** result was defined as elevation in adduction -1. A result was considered **good** if the postoperative limitation in elevation was -2. A limitation of elevation in adduction of -3 was considered to be **fair**. A grade of **poor** was assigned if the patient continued to exhibit either a downshoot in adduction (undercorrected) or an upshoot in adduction (overcorrected). Informed consent was obtained from each patient or parents of our children in the study after they had received a detailed explanation of the procedure. In all surgeries performed the technique described by *Wright* (5) was used. The presence of Brown's syndrome was confirmed intraoperatively in each case by a positive forced-duction test. After performing a superior oblique tenotomy, the forced-duction test was repeated to ensure that there was complete resolution of the restriction of elevation in adduction. An 8- to 12-mm long silicone retinal band was then sutured between the cut ends of the tendon with 6/0 nonabsorbable suture. The expander was placed 3 mm from the nasal border of the superior rectus muscle, and the outer layer of the intermuscular septum was closed over the silicone band. A paired-sample Student's *t*-test was employed to analyse the improvement in primary-position hypotropia between the first and last postoperative visits.

## RESULTS

The postoperative follow-up period ranged from 28 to 144 months (mean, 61). As of the last recorded follow-up examination, 13 patients had an "excellent" result, 7 had a "good" result, 3 patients had a "fair" result, and none had a "poor" result (*Fig. 1*). Undercorrection was noted in 11 (47 %) of 23 eyes in 4 weeks. However, a highly significant improvement was noted at a later follow-up ( $P = .0017$ ). *Table 2* demonstrates the improvement seen at a later visit compared with the improvement seen at the first postoperative examination at 1 week. *Fig. 2* shows the improvement in primary position hypotropia at the final postoperative visit compared with preoperative hypodeviation and 1-week postoperative hypodeviation. All patients experienced an improvement in their severe congenital Brown's syndrome, with 100 % showing a postoperative primary-position hypotropia < 10 prism dioptres.

As a result, no patient required further surgery. Five of the 23 patients showed conversion of preoperative hypotropia into postoperative hyperphoria. All the remaining 18 patients had a small (< 8 prism dioptre) residual hypotropia in primary position. Before surgery, 6 patients had a chin-up head posture for fusion and maintained their fusion after surgery, but the head posture was no longer necessary. No intraoperative or postoperative complications of the silicone implants were noted.

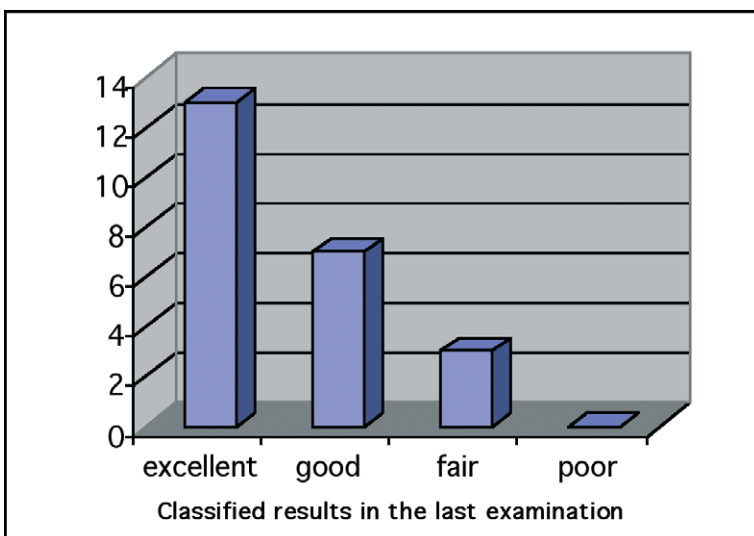


Fig. 1

Classified postoperative results at last examinations. Grading for “excellent”, “good”, “fair”, or “poor” (undercorrected or overcorrected) results by the method of Stager et al<sup>8</sup>. An excellent result was defined as elevation in adduction -1. A result was considered good if the postoperative limitation in elevation was -2. A limitation of elevation in adduction of -3 was considered to be fair. A grade of poor was assigned if the patient continued to exhibit either a downshoot in adduction (undercorrected) or an upshoot in adduction (overcorrected)

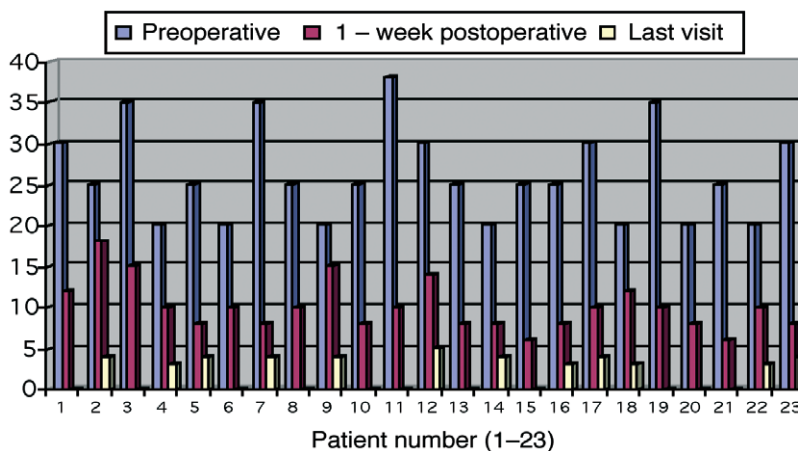


Fig. 2

A comparison of the preoperative, 1-week postoperative, and the last follow-up hypodeviations (prism dioptres) in primary position



*Table 2*  
Preoperative and postoperative comparison of primary-position deviations and limitations of elevation in adduction

Patient no.	Preop deviation (PD) and limitation (0 to -4) in elevation with adduction	Postop deviation at 1 wk (PD) and limitation (0 to -4) in elevation with adduction	Postop deviation at >12 mo (PD) and limitation (0 to -4) in elevation with adduction
1	RHypoT 30 (-4)	RHypoT 12 (-3)	No deviation (-1)
2	RHypoT 20 ET 5 (-4)	RHypoT 18 ET 4 (-2)	RHypoT 4 ET 2 (-1)
3	LHypoT 35 (-4)	LHypoT 15 (-3)	No deviation (-2)
4	LHypoT 20 (-4)	LHypoT 10 (-2)	LHypo(T)3 X(T) 3 (-1)
5	RHypoT 25 XT 10 (-4)	RHypoT 8 XT 4 (-2)	RHypoT 4 XT 6 (-1)
6	RHypoT 20 ET 8 (-4)	RHypoT 10 (-1)	No deviation (-1)
7	LHypoT 35 XT 5 (-4)	LHypoT 8 XT 5 (-2)	LHypoT 4 XT 4 (-2)
8	LHypoT 25 (-4)	LHypoT 10 (-2)	No deviation (-1)
9	RHypoT 20 (-4)	RHypoT 15 (-3)	RHypoT 4 (-2)
10	LHypoT 25 ET 6 (-4)	LHypoT 8 (-2)	No deviation (-1)
11	RHypoT 38 (-4)	RHypoT 10 (-3)	RH 4 (-2)
12	RHypoT 30 (-4)	RHypoT 14 (-2)	No deviation (-1)
13	RHypoT 25 ET 6 (-4)	RHypoT 8 (-1)	No deviation (-1)
14	LHypoT 20 XT 5 (-4)	LHypoT 8 XT 2 (-3)	LHypoT 4 XT 2 (-2)
15	RHypoT 25 XT 10 (-4)	RHypoT 8 XT 4 (-2)	RHypoT 3 XT 4 (-1)
16	LHypoT 25 XT 5 (-4)	LHypoT 8 XT 10 (-2)	LHypoT 4 XT 6 (-1)
17	RHypoT 30 (-4)	RHypoT 10 (-3)	No deviation (-2)
18	RHypoT 20 ET 5 (-4)	RHypoT 12 ET 4 (-2)	RHypoT 4 ET 2 (-1)
19	LHypoT 35 (-4)	LHypoT 10 (-2)	No deviation (-1)
20	RHypoT 20 (-4)	LHypoT 8 (-2)	No deviation (-1)
21	RHypoT 25 XT 10 (-4)	RHypoT 8 XT 4 (-2)	No deviation (-1)
22	RHypoT 20 ET 8 (-4)	RHypoT 10 (-1)	No deviation (-1)
23	LHypoT 30 XT 5 (-4)	LHypoT 8 XT 5 (-3)	LHypoT 4 (-2)

ET, esotropia; XT, exotropia; X, exophoria; X(T), intermittent exotropia; RHypoT, right hypotropia; RHypo(T), intermittent right hypotropia; LHypoT, left hypotropia; LHypo(T), intermittent left hypotropia; RH, right hyperphoria

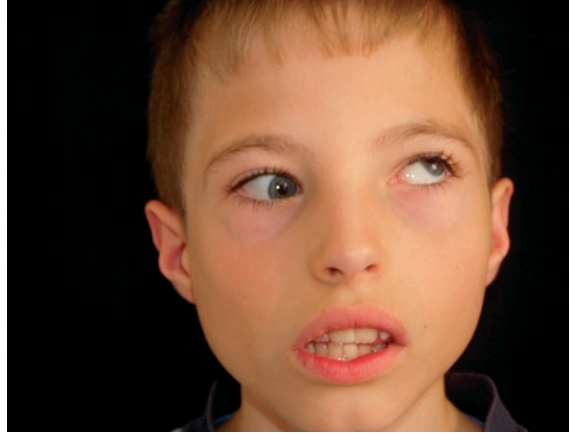## DISCUSSION

After Brown's description of his superior oblique "tendon sheath syndrome", attempts were made to correct the suspected deficit by dissecting and stripping the superior oblique tendon; however, these operations resulted in mixed results. (8,9) Superior oblique tenotomy has proved to be a relatively effective treatment for the severe congenital Brown's syndrome. (10-12) However, induced superior oblique palsy has been reported to be a complication; the rate of occurrence is as high as 85 %. (13) A high percentage of undercorrections after superior oblique tenectomy has also been reported. (14) A combined procedure, involving superior oblique tenotomy and inferior oblique recession, has been successful in decreasing the rate of induced superior oblique palsy. (15) Superior oblique tendon recession has also been reported to be an effective procedure for Brown's syndrome and inferior oblique palsy. (16)

In 1991, *Wright* (5) described an operation with a predictable amount of superior oblique weakening using a silicone expander in the superior oblique muscle tendon after a tenotomy. The reported results of this procedure were encouraging. *Stager et al* (7) reported an 80 % overall success rate in a series of 20 eyes with moderate to severe Brown's syndrome. The investigators suggested several modifications to *Wright's* original technique, including the use of shorter bands to eliminate overcorrections and of a narrower band to help decrease the rate of downgaze restrictions as reported by *Wilson et al.* (17) *Wright* also published a follow-up to his original article wherein he reported on a series of 15 patients with severe Brown's syndrome who underwent the expander procedure. (18) He graded his results on a scale from 1 to 10, with any score greater than 7 defined as successful. Using this scale, he reported a success rate of 87 %. *Stolovitch et al* (19) reviewed 8 patients who underwent the same procedure and reported a success rate of 88 %.

Using the outcome criteria of *Stager et al* (7) and defining a successful outcome as a hypotropia < 8 prism dioptres in primary position, the postoperative success rate for our series in the last examination is 100 %. The initial follow-up visit was discouraging at 1 week postop.: 47 % of the patients had an apparent undercorrection. However, a later follow-up showed that the elevation in adduction had significantly improved, and no patient required further additional surgery. Our results in this series of patients are comparable with the postoperative outcomes of *Awad et al.'s* (6) study, which used the similar surgical techniques with a 10-12 mm silicone band and the same outcome criteria. Their postoperative long-term success rate was also 100 %.

It has been postulated that a 10-mm band may be unnecessarily long and that this length plays a role in postoperative overcorrections. (7) Despite our using 8- to 12-mm bands in all our patients aged from 4 to 21 years, there were no overcorrections. All subjects in our study had a severe form of Brown's syndrome with a preoperative deviation ranging from 20 to 40 prism dioptres in primary position.



*Fig. 3*

Brown's syndrome with typical absence or severe limitation of elevation in adduction

The investigators postulate that the use of shorter expanders might only be considered when dealing with less severe primary-position hypodeviations. Longer expanders (10- to 12-mm) appear to be a more appropriate choice for patients who have severe Brown's syndrome with a primary-position hypotropia  $> 20$  prism dioptres. Longer expanders might increase the rate of implant extrusion; however, none of our patients presented with this complication despite our use of the longer silicone bands. One of the complications of the superior oblique expander procedure has been the potential for postoperative restrictions in downgaze. (5) It has been speculated that this might be caused by adhesions to the superior rectus muscle or the sclera. (7) In our study, we did not observe any downgaze restrictions, probably due to careful attention to restore the integrity of the inner and outer intermuscular septum.

In conclusion, the superior oblique tendon expander procedure seems to be an effective and safe method in the surgical treatment of severe congenital Brown's syndrome. The use of 8- to 12-mm band also appears to be an appropriate choice when dealing with patients with a primary-position hypotropia  $> 20$  prism dioptres.

## REFERENCES

1. *Von Noorden GK*. In Binocular vision and ocular motility: theory and management of strabismus, Mosby, St. Louis 1996, 437-442.
2. *Parks MM*. The superior oblique tendon. 33<sup>rd</sup> Doyne memorial lecture. Trans Ophthalmol Soc UK 1977;97: 288-304.
3. *Crawford JS*. Surgical treatment for true Brown Syndrome. Am J Ophthalmol 1976;81: 229-234.
4. *Sevel D*. Brown's syndrome. A possible etiology explained embryologically. Ophthalmology 1981; 18:26-32.
5. *Wright KW*. Superior oblique silicone expander for Brown syndrome and superior oblique overaction. J Pediatr Ophthalmol Strabismus 1991;28: 101-107.
6. *Awad AH, Digout LG, Al Turkmani S, et al*. Large-segment superior oblique tendon expanders in the management of severe congenital Brown syndrome. JAAPOS 2003;7, 4: 23-29.
7. *Stager DR, Parks MM, Stager DR, Pesheva M*. Long-term results of silicone expander for moderate and severe Brown syndrome (Brown syndrome "plus"). J AAPOS 1999; 3: 328-332.
8. *Brown HW*. True and simulated superior oblique tendon sheath syndromes. Doc Ophthalmol 1973;34:123-129.
9. *Parks MM, Brown M*. Superior oblique tendon sheath syndrome of Brown. Am J Ophthalmol 1975;79: 82-88.
10. *Crawford JS*. Late results of superior oblique muscle tenectomy in true Brown's syndrome. Am J Ophthalmol 1980; 89: 824-829.
11. *Parks MM*. Surgery for Brown's syndrome. Symposium on strabismus. Trans New Orleans Acad Ophthalmol 1978: 157-167.
12. *Von Noorden GK, Oliver P*. Superior oblique tenectomy in Brown's syndrome. Ophthalmology 1982; 89: 303-308.
13. *Eustis HS, O'Reilly C, Crawford JS*. Management of superior oblique palsy after surgery for true Brown's syndrome. J Pediatr Ophthalmol Strabismus 1987; 24: 10-16.
14. *Prieto-Diaz J*. Superior oblique overaction. Int Ophthalmol Clin 1989;29:43-50.
15. *Parks MM, Eustis HS*. Simultaneous superior oblique tenotomy and inferior oblique recession in Brown's syndrome. Ophthalmology 1987; 94: 1043-1048.
16. *Astle WF, Cornock E, Drummond GT*. Recession of the superior oblique tendon for inferior oblique palsy and Brown's syndrome. Can J Ophthalmol 1993; 28: 207-212.
17. *Wilson ME, Sinatra RB, Saunders RA*. Downgaze restriction after placement of superior oblique tendon spacer for Brown syndrome. J Pediatr Ophthalmol Strabismus 1995; 32: 29-34.
18. *Wright KW*. Results of the superior oblique tendon elongation procedure for severe Brown's syndrome. Trans Am Ophthalmol Soc 2000; 98: 41-48.
19. *Stolovitch C, Leibovitch I, Loewenstein A*. Long-term results of superior oblique tendon elongation for Brown's syndrome. J Pediatr Ophthalmol Strabismus 2002; 39: 90-93.

## LONG-TERM SURGICAL OUTCOMES OF THE SECONDARY IOL IMPLANTATION IN CHILDREN

AUTRATA R., PYROCHTOVÁ S., HELMANOVÁ I., LOKAJ M., ŘEHŮŘEK J.

Department of Paediatric Ophthalmology, Faculty of Medicine,  
Masaryk University Hospital, Brno

*Received after revision January 2007*

### Abstract

To evaluate the functional outcomes of various techniques for implanting intraocular lenses (IOL) in aphakic children in the absence of adequate capsular support and for placing a secondary IOL within the capsular bag.

Sixty-eight children, aged from 36 months to 16 years (mean: 7.95 years), who originally had aphakia after cataract extraction, were operated on during the period from January 1995 to January 2003. The mean follow-up time was 6.9 years (range: 3 to 10 years). Visual outcomes, refraction, and complications of 93 eyes were reviewed. Secondary PCIOL implantation with transscleral suture fixation was performed in 25 eyes, anterior chamber (AC) IOLs were implanted in 17 eyes in the absence of capsular support. Nineteen eyes had PCIOL implantation within the reopened capsular bag, in 32 eyes PCIOLs were implanted into the ciliary sulcus without suture fixation. All postoperative data are presented from the last examinations.

The best spectacle-corrected visual acuity (BSCVA) postoperatively was preserved in 55 eyes, improved in 27 eyes (1 or 2 Snellen lines gain), and worsened in 11 eyes (1 or 2 Snellen lines gain) in comparison with their preoperative value. Uncorrected visual acuity (UCVA) was improved in all eyes. The mean spherical equivalent refraction preoperatively was +13.28 D (range: +9.50 to +17.25 D) and changed to +2.14 D (range -3.25 to +5.75 D). Binocular vision status was maintained in 57 children and improved in 11 children. High-grade stereopsis was present in 29% of children with bilateral pseudophakia and in 10.4% of children with unilateral pseudophakia. The highest complication rate (fibrinous inflammatory response, korectopia, secondary glaucoma) was observed after ACIOL implantation cases. Posterior chamber IOLs implanted into the reopened capsular bag as well as transscleral suture fixated PCIOLs induced significantly less complications. No severe complications like endophthalmitis or retinal detachment were found.

PCIOLs sutured to the ciliary sulcus offer a superior option to ACIOLs for the correction of childhood aphakia in children lacking capsular support. The placement of secondary IOLs within the capsular bag can be accomplished successfully for selected paediatric patients. In the bag fixation of foldable IOLs is associated with a low rate of complications and excellent visual and refractive outcomes. Secondary PCIOL implantation is a safe and effective method for the correction of paediatric aphakia.

### Key words

Aphakia, children, Secondary implantation, Intraocular lenses

## Abbreviations used

IOLs, intraocular lenses; PCIOLs, posterior chamber intraocular lenses; ACIOLs, anterior chamber intraocular lenses; AC, anterior chamber; TSSIOL, transsclerally sutured IOL

## INTRODUCTION

The use of intraocular lenses (IOLs) to correct paediatric aphakia has become increasingly common in recent years and is now regarded as a well-accepted approach for children beyond infancy. Improvements in surgical technique and IOL design have made implantation of IOLs into small paediatric eyes safer and less traumatic.

Secondary implantation of an intraocular lens (IOL) can be the most effective treatment for the correction of aphakia in children after removal of a congenital or traumatic cataract. (1-4, 14-17) Poor compliance, high replacement costs, or keratopathy may prevent successful visual rehabilitation when using an aphakic contact lens. (17) Spectacles are not well suited for children with unilateral aphakia because of the adverse optical properties of aphakic lenses. IOL implantation provides the possibility for these patients of achieving better vision and some binocular co-operation.

Posterior chamber intraocular lenses (PCIOLs) implanted in the ciliary sulcus with capsular support offer the best option for correction in these cases. (4,5,19) With modern lensectomy techniques and acceptance of IOLs in children, this population of aphakic children without capsular support should decrease with time. Anterior chamber intraocular lenses (ACIOLs) have been successfully used in adults when the posterior capsule is absent or when extensive iridocapsular adhesions prevent PCIOL implantation. (18) More recently, materials and techniques for sutured PCIOLs have improved, giving paediatric surgeons an alternative to ACIOLs in aphakic children without capsular support. (20-24)

Surgery for cataracts in infancy usually includes an anterior capsulectomy, lens aspiration, a primary posterior capsulectomy, and an anterior vitrectomy. (4) Over time, the remaining equatorial lens epithelial cells often produce new cortical fibres. This process can produce a ring of cortex trapped between the lens equator and the fused anterior and posterior capsulectomy edges. Therefore, a potential space for in-the-bag placement of an IOL may be maintained between the anterior and posterior capsular leaflets. This development (Soemmering's ring) occurs most prominently in children who have undergone lensectomy early in their lives. In this paper the authors describe a technique for reopening the capsular bag, removing the Soemmering's ring, and placing the IOL in the bag.

## MATERIALS AND METHODS

Sixty-eight children, aged from 36 months to 16 years (mean: 7.95 years), who originally had aphakia after cataract extraction, were operated on during the period from January 1995 to January 2003. The mean follow-up time was 6.9 years (range: 3 to 10 years). Visual outcomes, refraction, and complications of 93 eyes were reviewed. Secondary PCIOL implantation with transscleral suture fixation was performed in 25 eyes, anterior chamber (AC) IOLs were implanted in 17 eyes in the absence of capsular support. Nineteen eyes had PCIOL implantation within the reopened capsular bag, in 32 eyes PCIOLs were implanted into the ciliary sulcus without suture fixation. All postoperative data are presented from the last examinations.

Conventional techniques were used for implantation of the ACIOL as described previously. (25) For TSSIOL placement, the technique described originally by Lewis (26) in 1993 and modified by Epley *et al* (27) in 1999 was used.

In-the-bag implantation: A scleral or corneal tunnel is fashioned for a length adequate to allow implantation of the IOL. Viscodissection as well as blunt and sharp dissection is used as needed to break the posterior synechiae attaching the iris to the capsular remnants. A dense, white ring made of the fused edges of the anterior and posterior capsules is usually visible in the centre of the pupillary space. A vitrector handpiece driven by a Venturi pump was used. With the cutting port of the vitrector tip facing posteriorly, the anterior capsule is engaged by the cutter at the edge of the fused central circular capsulectomy at the point where separation from the posterior capsular remnant is evident.

This initial anterior capsular opening is made in a position where the Soemmering's ring is most exuberant. Cutting speeds of 150 to 300 cuts per minute are recommended. This vitrector-cut anterior capsulectomy (vitrectorhexis) is continued for 360°. Care is taken to keep the vitrector cut as close to the centrally fused capsular ring as possible but without inadvertently cutting through the posterior capsular remnant. Curved intraocular scissors or a sharp cystotome needle can also be used if desired or needed. Cortical material is aspirated from within the capsular bag remnant using the vitrector or a standard straight or U-shaped irrigation/aspiration handpiece. A viscoelastic substance is placed between the capsular leaflets. The anterior capsular edge is identified for 360°. Ideally, there should be no radial tears in this anterior capsular edge. An IOL is then placed within the capsular bag. Care is taken to ensure that the lens is not asymmetrically placed with 1 haptic in the bag and 1 haptic in the sulcus. A supplemental vitrectomy is performed if needed through the central posterior capsular opening before IOL implantation.

## RESULTS

The best spectacle-corrected visual acuity (BSCVA) postoperatively was preserved in 55 eyes, improved in 27 eyes (1 or 2 Snellen lines gain), and worsened in 11 eyes (1 or 2 Snellen lines gain) in comparison with their preoperative value. Uncorrected visual acuity (UCVA) was improved in all eyes. The mean spherical equivalent refraction preoperatively was +13.28 D (range: +9.50 to +17.25 D) and changed to +2.14 D (range -3.25 to +5.75 D). Binocular vision status was maintained in 57 children and improved in 11 children. High-grade stereopsis was present in 29% of children with bilateral pseudophakia and in 10.4% of children with unilateral pseudophakia. The highest complication rate (fibrinous inflammatory response, korectopia, secondary glaucoma) was observed after ACIOL implantation cases. Posterior chamber IOLs implanted into the reopened capsular bag as well as transscleral suture fixated PCIOLs induced significantly less complications. No severe complications like endophthalmitis or retinal detachment were found.

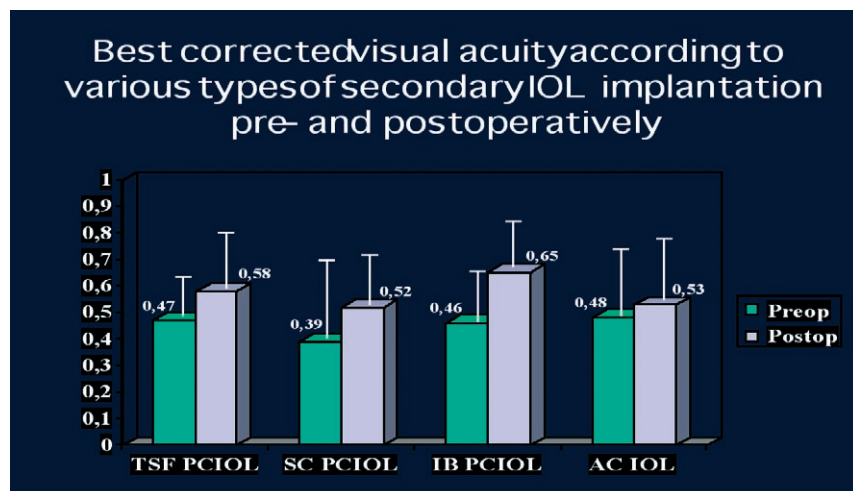


Fig. 1

Best corrected visual acuity after secondary IOL implantation

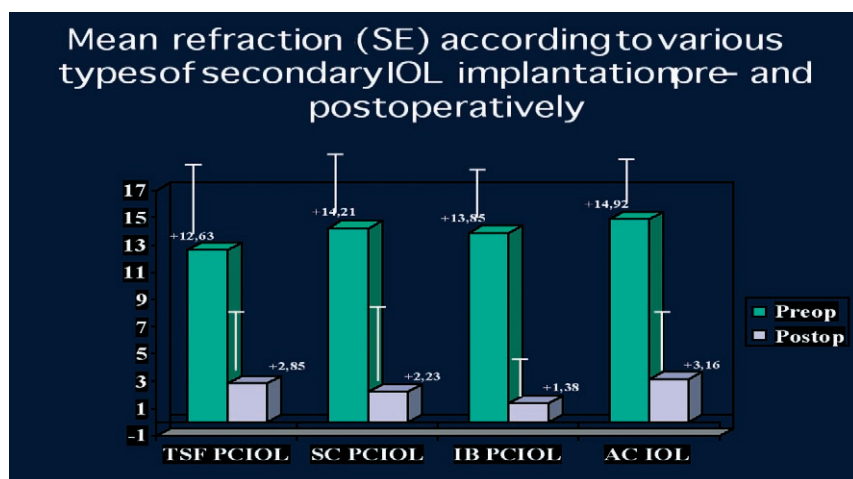


Fig. 2

Mean SE refraction after secondary IOL implantation



### Binocular vision aftersecondary IOL implantation

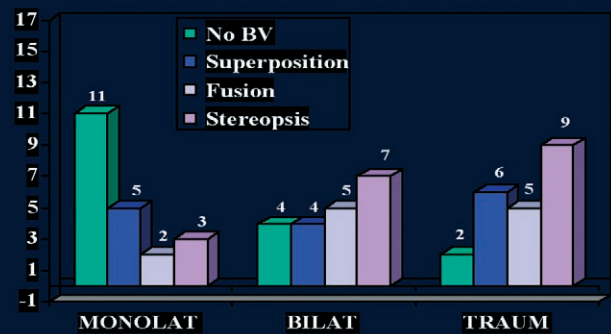


Fig. 3  
Binocular vision after secondary IOL implantation

### Complicationrateaftersecondary IOL implantation((% of eyes)

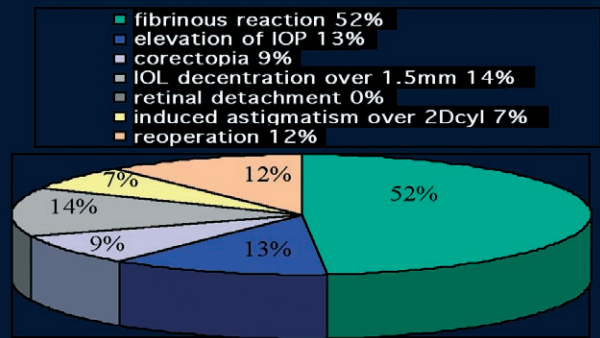


Fig. 4  
Complications after secondary IOL implantation

## DISCUSSION

The paediatric aphakic population continues to be a treatment challenge. In addition to IOLs, treatment options for both preserving visual acuity and preventing amblyopia include contact lenses and spectacles. Spectacles and contact lenses have some inherent disadvantages (1,2,3) and are not successful in all cases. Children who are not doing well with these therapies may benefit from secondary lens implantation. Insertion of an IOL into the ciliary sulcus or capsular bag is the treatment of choice when adequate capsular support exists. (4) In the older child, an IOL would ideally be placed primarily into the capsular bag after a lensectomy. (4,5,6) If posterior synechiae are present, it is sometimes possible to lyse them intraoperatively and regain enough capsule to support a PCIOL. (7) However, if the surgeon is unable to remove these iridocapsular adhesions, only 2 choices remain: transsclerally sutured IOL (TSSIOL) and ACIOL. Neither TSSIOLs nor ACIOLs have been studied extensively in children. Sulcus-fixated PCIOL surgery is technically more difficult than ACIOL implantation and has its own inherent complications, including vitreous or ciliary body haemorrhage, IOL tilt that induces astigmatism, and conjunctival erosion of scleral sutures leading to infection or endophthalmitis. (8,9) ACIOLs have the advantage of being easier to insert but may have a higher complication rate in the long term. We do not recommend the use of ACIOLs in children given the potentially high complication rate and the availability of the TSSIOL technique for the correction of aphakia in select children for whom capsule-supported PCIOLs and contact lenses are not an option.

The use of TSSIOLs in patients with dislocated lenses has not been studied in children, largely because there is a small patient population of children with dislocated lenses. This technique may be of significant future benefit to these patients, allowing them to receive a lens implant at the time of primary surgery. Long-term follow-up and larger studies will be necessary to accurately assess the risks and benefits of the TSSIOL technique for more generalised use.

The implantation of an IOL at the time of cataract surgery in children younger than 1 year remains controversial. Initially, most of these infants have aphakia after the surgical procedure. Surgery for cataracts in infancy usually includes an anterior capsulectomy, lens aspiration, a primary posterior capsulectomy, and an anterior vitrectomy. (11) Over time, the remaining equatorial lens epithelial cells often produce new cortical fibres. This process can produce a ring of cortex trapped between the lens equator and the fused anterior and posterior capsulectomy edges. Therefore, a potential space for in-the-bag placement of an IOL may be maintained between the anterior and posterior capsular leaflets. This development (Soemmering's ring) occurs most prominently in children who have undergone lensectomy early in their lives. A Soemmering's ring of cortex is needed to keep the anterior and posterior capsular remnants from becoming completely fused, to accomplish secondary in-the-bag implantation.

*Wilson et al* (7) described a technique for reopening the capsular bag, removing the Soemmering's ring, and placing the IOL in the bag. They recommend a specific technique for infant lens extraction when an IOL is not being implanted that will facilitate secondary in-the-bag IOL implantation later if needed or desired.

*Wilson et al* concluded that the capsular fixation of an IOL may provide the greatest margin of safety for tolerance of the implant over the long life of a child. Secondary implantation of an IOL in a child's aphakic eye has become commonplace and is considered reasonably safe and effective despite the ciliary sulcus location of the implant. With the use of the Wilson's technique described in his article, successful capsular fixation of a secondary IOL may be possible.

As early as 1985, *Apple et al* (12) recognised the advantages of capsular bag fixation, as opposed to ciliary sulcus fixation. They made a special note about the advantages of in-the-bag implantation for children in whom there is the need to tolerate the IOL for the whole of their lives.

*Taylor* (13) stated that secondary IOLs can be successfully implanted in children who have adequate posterior capsule to support them. However, he noted that the ciliary sulcus is a less than satisfactory site for implantation.

When performing infantile cataract surgery without primary IOL implantation, it is useful to leave an adequate capsular rim for subsequent IOL placement. A 4.5-mm central posterior and anterior capsulectomy is usually adequate to prevent opacification of the visual axis but assures an adequate rim of support when secondary IOL implantation is elected.

In a patient with bilateral aphakia, it is sometimes a clever idea to choose the eye with the worst capsular support first. If it is not feasible to safely achieve implantation, bilateral aphakia can still be chosen.

Scleral tunnel incision is preferable for secondary IOL implantation even if a foldable IOL is to be used. In our experience, scleral tunnels are easier to enlarge than corneal tunnels. After the posterior synechiae are severed, a change to a PMMA IOL may be warranted when capsular support is limited. This change can be accomplished more easily from a scleral incision. It is important to assess whether it is possible to reopen the capsular bag leaflets for in-the-bag secondary IOL implantation. The key is to locate one area in which the anterior capsule edge is not strongly adherent to the posterior capsule. Viscoelastic agents can be very useful in the separation of the capsular layers. If adhesions are very strong, alternative dissection (with iris reposition and/or a micro vitreoretinal knife) techniques must be used. The next step is to remove the Soemmering's ring by bimanual irrigation/aspiration and placement of secondary IOL into the capsular bag whenever possible. A foldable lens is recommended for this location. In our experience, in-the-bag fixation is more consistently achieved with foldable IOLs, either three-piece or single-piece.

When the ciliary sulcus is the intended placement site for a secondary IOL, our preferred lens is an HSM PMMA IOL. Perhaps the rigidity of this IOL helps to prevent the decentration associated with the use of foldable IOLs. Foldable IOLs

work well when microphthalmia is present or optic capture through the anterior and posterior capsule can be accomplished.

In the absence of an available capsular support, sutured IOLs, iris-claw lenses, or ACIOLs can be used, depending on the surgeon's preference, ocular environment, and IOL availability. Further studies with more patients and long-term follow-ups are convenient to establish superiority of one over another.

In conclusion of our study, PCIOLs sutured to the ciliary sulcus offer a superior option to ACIOLs for the correction of childhood aphakia in children lacking capsular support. Placement of secondary IOLs within the capsular bag can be accomplished successfully for selected paediatric patients. In-the-bag fixation of foldable IOLs is associated with a low rate of complications and excellent visual and refractive outcomes. Secondary PCIOL implantation is a safe and effective method for the correction of paediatric aphakia.

#### REFERENCES

1. *Hiles DA, Hered RW.* Modern intraocular lens implants in children with new age limitations. *J Cataract Refract Surg* 1987; 13: 493-497.
2. *BenEzra D, Cohen E, Rose L.* Traumatic cataract in children: correction of aphakia by contact lens or intraocular lens. *Am J Ophthalmol* 1997; 123: 773-782.
3. *Hiles DA.* Visual rehabilitation of aphakic children: III. Intraocular lenses. *Surv Ophthalmol* 1990;34:371-9.
4. *Wilson ME, Bluenstein EC, Wang X.* Current trends in the use of intraocular lenses in children. *J Cataract Refract Surg* 1994; 20: 579-583.
5. *Lambert SR, Drack AV.* Infantile cataracts. *Surv Ophthalmol* 1996; 40: 427-458.
6. *Young TL, Bloom JN, Ruttum M, Sprunger DT, Weinstein JM.* The IOLAB, Inc pediatric intraocular lens study. AAPOS Research Committee. American Association for Pediatric Ophthalmology and Strabismus. *J AAPOS* 1999; 3: 295-302.
7. *Wilson ME Jr, Englert JA, Greenwald MJ.* In-the-bag secondary intraocular lens implantation in children. *J AAPOS* 1999; 3: 350-355.
8. *Hiles DA, Watson BA.* Complications of implant surgery in children. *J Am Intraocul Implant Soc* 1979;5:24-32.
9. *Soloman K, Gussler JR, Gussler C, VanMeter WS.* Incidence and management of complications of trans-sclerally sutured posterior chamber lenses. *J Cataract Refract Surg* 1993; 19: 488-493.
10. *Uthoff D, Teichman KD.* Secondary implantation of scleral-fixated intraocular lenses. *J Cataract Refractive Surgery* 1998; 24: 945-950.
11. *Wilson ME.* Surgery for pediatric cataracts. In: Spaeth GL, ed. *Ophthalmic surgery, principles and practices*. 3rd ed. Philadelphia: WB Saunders Co. In press 1999.
12. *Apple DA, Reidy JJ, Googe JM, Mamalis N, Novak LC, Loftfield K, et al.* A comparison of ciliary sulcus and bag fixation of posterior chamber intraocular lenses. *J Am Intraocul Implant Soc* 1985; 11: 44-63.
13. *Taylor D.* The Doyné lecture. Congenital cataract: the history, the nature and the practice. *Eye* 1998;12:9-36.
14. *Biglan AW, Cheng KP, Davis JS, Gerontis CC.* Secondary intraocular lens implantation after cataract surgery in children. *Am J Ophthalmol* 1997; 123: 224-234.
15. *Awad AH, Mullaney PB, Al-Hamad A, Wheeler D, Al-Mesfer S, Zwaan J.* Secondary posterior chamber intraocular lens implantation in children. *J AAPOS* 1998; 2: 269-274.
16. *Koenig SB, Ruttum MS, Lewandowski MF, Schultz RO.* Pseudophakia for traumatic cataracts in children. *Ophthalmology* 1993; 100: 1218-1224.
17. *BenEzra D, Cohen E, Rose L.* Traumatic cataract in children: correction of aphakia by contact lens or intraocular lens. *Am J Ophthalmol* 1997; 123: 773-782.
18. *Auffarth GU, Wesendahl TA, Brown SJ, Apple DJ.* Are there acceptable anterior chamber intraocular lenses for clinical use in the 1990s? An analysis of 4104 explanted anterior chamber intraocular lenses. *Ophthalmology* 1994; 101: 1913-1922.

19. *Brady KM, Atkinson CS, Kilty LA, Hiles DA.* Cataract surgery and intraocular lens implantation in children. *Am J Ophthalmol* 1995; 120: 1-9.
20. *Soloman K, Gussler JR, Gussler C, VanMeter WS.* Incidence and management of complications of transsclerally sutured posterior chamber lenses. *J Cataract Refract Surg* 1993; 19: 488-493.
21. *Kumar M, Arora R, Sanga L, Sota LD.* Scleral-fixated intraocular lens implantation in unilateral aphakic children. *Ophthalmology* 1999; 106: 2184-2189.
22. *Buckley EG.* Scleral fixated (sutured) posterior chamber intraocular lens implantation in children. *J AAPOS* 1999; 3: 289-294.
23. *Zetterstrom C, Lundvall A, Weeber H Jr, Jeeves M.* Sulcus fixation without capsular support in children. *J Cataract Refract Surg* 1999; 25: 776-781.
24. *Young TL, Bloom JN, Ruttum M, Sprunger DT, Weinstein JM.* The IOLAB, Inc pediatric intraocular lens study. AAPOS Research Committee. American Association for Pediatric Ophthalmology and Strabismus. *J AAPOS* 1999; 3: 295-302.
25. *Jaffe NF.* Anterior chamber lens implantation. In: Jaffe NS, Jaffe MS, Jaffe GF, eds. *Cataract surgery and its complications*. 6th ed. London: Mosby-Wolfe; 1997: p. 182-187.
26. *Lewis JS.* Sulcus fixation without flaps. *Ophthalmology* 1993; 100: 1346-1350.
27. *Epley KD, Levine ES, Katz HR.* A simplified technique for stable transscleral suture fixation of posterior chamber intraocular lenses. *Ophthalmic Surg Lasers* 1999; 30: 398-402.



## ACRYSOF INTRAOCULAR LENS PRIMARY IMPLANTATION IN CHILDREN WITH CONGENITAL AND DEVELOPMENTAL CATARACT

PYROCHTOVÁ S., AUTRATA R., LOKAJ M., ŘEHŮŘEK J.

Department of Paediatric Ophthalmology, Faculty of Medicine,  
Masaryk University Hospital, Brno

*Received after revision January 2007*

### Abstract

To evaluate the visual results, complications, the prevalence and severity of posterior capsule opacification (PCO) in paediatric eyes having cataract extraction with foldable acrylic AcrySof intraocular lens implantation for congenital and developmental cataract.

This prospective observational study comprised 97 consecutive eyes of 65 children who had surgery for congenital and developmental cataract during the period from January 1995 to December 2004 and were followed up in our clinic. Three groups were formed based on the age at surgery and surgical technique. Group 1, younger than 2 years, included 28 eyes with primary posterior continuous curvilinear capsulorhexis (PCCC) and anterior vitrectomy (AV). Group 2 contained children from 2 to 6 years (30 eyes) with PCCC + AV (17) and optic capture (13). In Group 3, children older than 6 years (39 eyes) were randomly assigned to PCCC+AV, (group 3A, n= 21 eyes) or without PCCC+AV, (group 3B, n=18 eyes). The main outcome parameters were: visual axis opacification, severity of PCO formation, the need for a secondary procedure to clear the visual axis, visual acuity, refraction, binocular vision and complications of all 97 eyes. Statistical analyses were performed using SPSS for Windows, version 10.0. A *P* value less than 0.05 was considered statistically significant.

The mean age at surgery was 5.8 years  $\pm$  4.2 (SD) (range 0.4 to 16 years). The mean follow-up time was 6.7 years (range: 2.3 to 12 years). The best spectacle-corrected visual acuity (BSCVA) improved in all cases. At the final follow-up, a BSCVA of 0.5 or better was achieved in 78 %, 71 % and 63 % of the eyes in groups 1,2,3, respectively. Overall, 35 eyes (36 %) developed visual axis opacification and 21 eyes (24.7 %) required secondary intervention. In group 1, 12 eyes (39.2 %) developed PCO and 7 eyes (25 %) had a secondary pars plana vitrectomy (PPV). In group 2, 9 eyes (30 %) developed PCO and 6 eyes (20 %) had additional procedure (PPV). In group 3A, no eyes (0 %) had visual axis opacification. However, in group 3B, 14 eyes (78 %) developed PCO, and 11 eyes required secondary intervention. The visual axis was clear after one secondary procedure in all 21 eyes with PCO, at the last follow-up. In all patients, posterior synechiae occurred in 14% of the eyes, cell deposits on the IOL in 38 %. Chronic glaucoma developed in 4 eyes, and transitory glaucoma in 3 eyes. All eyes in all groups had well-centred IOLs. A fundus examination did not reveal cystoid macular oedema. No severe complications like endophthalmitis or retinal detachment occurred.

The AcrySof IOL provided a satisfactory functional and anatomical outcome and produced a very acceptable inflammatory response. With appropriate management of the posterior capsule, AcrySof IOL implantation maintained visual axis clarity in 64% of the eyes. Of the 36 % of eyes with visual axis opacification, 24 % required a secondary procedure to eliminate visually significant opacification.

In-the-bag implantation of the Acrysof IOLs is associated with a low rate of complications and excellent visual and refractive outcomes.

#### Key words

Congenital cataract, children, Primary implantation, AcrySof intraocular lenses.

#### Abbreviations used

PCO, posterior capsule opacification; PCCC, posterior continuous curvilinear capsulorrhexis; AV, anterior vitrectomy; BSCVA, best spectacle-corrected visual acuity; PPV, pars plana vitrectomy

### INTRODUCTION

Paediatric cataract surgery and the correction of aphakia after cataract removal in children present unique management problems rarely encountered in adult patients with cataracts. Because of the risk of deprivation amblyopia, cataract surgery in children younger than 7 years of age cannot be delayed once a cataract has developed. In the last 15 years, IOL use in children has been increasing, mainly because of the improvement in surgical techniques, such as continuous circular capsulorrhexis, which facilitates safe IOL implantation in the bag. Few intraoperative and postoperative complications are reported. In older children with traumatic or infantile cataract, the results of cataract surgery with primary IOL implantation are excellent and the complication rate is very low. In infants, however, surgical complications are much more common, mainly as a result of increased tissue reactivity. The use of IOLs in children younger than 2 years remains controversial because of the high complication and reoperation rates.

Our study evaluated the visual results, complications, the prevalence and severity of posterior capsule opacification (PCO) in paediatric eyes having cataract extraction with foldable acrylic AcrySof IOL implantation for congenital and developmental cataract.

### PATIENTS AND METHODS

This prospective observational study comprised 97 consecutive eyes of 65 children who had surgery for congenital and developmental cataract during the period from January 1995 to December 2004 and were followed up in our clinic. Eyes with associated ocular anomalies, microcornea, glaucoma, or traumatic cataract were excluded from the study. All the eyes had thorough preoperative visual assessment. Slit-lamp biomicroscopy, intraocular pressure, automatic refractometry and keratometry, axial length by A-scan, ultrasonography by B-scan, manifest and cycloplegic refraction, and funduscopy were performed. In younger or unco-operative children, preoperative examinations were performed in general anaesthesia. Visual acuity was assessed using Teller acuity cards, Lea symbols, or Snellen charts. The IOL power was calculated with the modified SRK II formula. The surgery technique included a limbal or clear corneal incision, injection of a viscoelastic to the anterior chamber, manual anterior capsulorrhexis, hydrodissection, irrigation/aspiration. The management of the posterior capsule and the anterior vitreous depended primarily on the patients' age at the time of surgery. All the eyes received a 3-piece or 1-piece AcrySof IOL (Alcon Laboratories). The goal was to implant the IOL in the bag. Three groups were formed based on the age at surgery and the surgical technique.



**Group 1** with children younger than 2 years included 28 eyes with primary posterior continuous curvilinear capsulorrhexis (PCCC) and anterior vitrectomy (AV).

In these eyes a posterior capsulotomy was made with a 27-gauge needle and then enlarged to 4 mm, creating a PCCC by forceps. A dry anterior vitrectomy was done through the posterior capsulotomy site. It was confirmed that no vitreous was present at the pupillary level. After the viscoelastic was injected, the AcrySof IOL was implanted in the capsular bag. **Group 2** included children from 2 to 6 years (30 eyes) with PCCC + AV (17 eyes, group 2A) and PCCC + AV+ posterior optic capture (13 eyes, group 2B) as described by Gimbel. In **Group 3**, children older than 6 years (39 eyes) were randomly assigned to implant AcrySof IOL with PCCC+AV (group 3A, n = 21 eyes) or without PCCC+AV to leave an intact posterior capsule (group 3B, n = 18 eyes).

Secondary cataracts were removed if there were significant disturbances of the visual axis. The postoperative follow-up included the latest examination of each patient.

The main outcome parameters were: visual axis opacification, severity of PCO formation, the need for a secondary procedure to clear the visual axis, visual acuity, refraction, binocular vision, and complications of all 97 eyes. Statistical analyses were performed using SPSS for Windows, version 10.0. A *P* value less than 0.05 was considered statistically significant.

*Table 1*  
Distribution of patients' age and AcrySof IOL implantation technique

Group (number, eyes)	age	surgical technique
Group 1 (28)	< 2 years	PCCC+ AV
Group 2 A (17)	2 to 6 years	PCCC+ AV
Group 2 B (13)	2 to 6 years	PCCC + AV+optic capture
Group 3 A (21)	>6 years	with PCCC+AV
Group 3 B (18)	>6 years	without PCCC+AV

PCCC= posterior continuous curvilinear capsulorrhexis

AV= anterior vitrectomy

## RESULTS

The mean age at surgery was 5.8 years  $\pm$  4.2 (SD) (range 0.4 to 16 years). The mean follow-up time was 6.7 years (range: 2.3 to 12 years). The best spectacle-corrected visual acuity (BSCVA) improved in all cases. At the final follow-up, a BSCVA of 0.5 or better was in 78 %, 71 %, and 63 % of the eyes in Groups 1, 2, 3, respectively. (*Table 1*)

Overall, 35 eyes (36 %) developed visual axis opacification and 21 eyes (24.7 %) required secondary intervention. In group 1, 12 eyes (39.2 %) developed PCO and 7 eyes (25 %) had a secondary pars plana vitrectomy (PPV). In group 2, 9 eyes (30 %) developed PCO and 6 eyes (20 %) had additional procedures (PPV). In group 3A, no eyes (0 %) had visual axis opacification. However, in group 3B, 14 eyes (78 %) developed PCO, and 11 eyes required secondary intervention. The visual axis was clear after one secondary procedure in all 21 eyes with PCO, at the last follow-up.

In all patients, posterior synechiae occurred in 14% of the eyes, cell deposits on the IOL occurred in 38 %. Chronic glaucoma developed in 4 eyes, and

transitory glaucoma in 3 eyes. All the eyes in all groups had well-centred IOLs. The fundus examination did not reveal cystoid macular oedema. There were no serious intraoperative complications. No severe postoperative complications like endophthalmitis or retinal detachment occurred.

*Table 2*

Final visual acuity: Comparison between the groups of eyes with AcrySof IOL implantation

Group (number, eyes)	BSCVA>0.5 (n, % of eyes)	Bilateral (n, % of eyes)	Unilateral (n, % of eyes)
Group 1 (28)	22 (78 %)	18 (64 %)	10 (36 %)
Group 2 A (17)	13 (76 %)	12 (70 %)	5 (30 %)
Group 2 B (13)	10 (71 %)	10 (77 %)	3 (23 %)
Group 3 A (21)	15 (72 %)	14 (67 %)	7 (33 %)
Group 3 B (18)	11(61 %)	12(67 %)	6 (33 %)

BSCVA= best spectacle-corrected visual acuity

*Table 3*

Visual axis opacification and need for a secondary procedure after AcrySof IOL implantation

Group (number, eyes)	No PCO (n, % of eyes)	PCO (n, % of eyes)	Secondary procedure
Group 1 (28)	16 (61 %)	12 (39 %)	7 (25 %)
Group 2 A (17)	12 (71 %)	5 (29 %)	2 (12 %)
Group 2 B (13)	9 (69 %)	4 (31 %)	1 (8 %)
Group 3 A (21)	21 (100 %)	0 (0 %)	0
Group 3 B (18)	4 (22 %)	14 (78 %)	11 (61 %)

PCO= posterior capsule opacification

In Group 1, 27% of the eyes developed posterior synechiae and in 41 % of the eyes cell deposits occurred on the IOL surface. The mean postoperative IOP was  $17.5 \pm 3.6$  mmHg. The incidence of synechia formation and deposits was significantly higher in Group 1 than in other groups ( $P < 0.01$  and  $P < 0.03$ , respectively).

In Groups 2 A and B, no eye developed posterior synechiae, 32 % of the eyes had cell deposits on the IOL. The mean postoperative IOP was  $16.9 \pm 3.4$  mmHg. In Groups 3 A and B, only three eyes developed posterior synechiae and 5 eyes had cell deposits on the IOL. The mean postoperative IOP was  $18.1 \pm 1.7$  mmHg. All the eyes in all groups had well-centred AcrySof IOLs. The visual acuity improved in all cases. Cataract morphology had no influence on the incidence of PCO formation in eyes with lens-cortex-posterior capsule involvement. At the last follow-up, the visual axis was clear in all of the eyes. Pigment deposits in the anterior IOL surface did not obscure the visual axis. The difference in the rate of early postoperative complications between those with PCO and those with a clear visual axis was

statistically significant ( $P < 0.01$ ). Glistenings in the AcrySof IOL were seen only in 4 eyes of all patients in the study. Binocular vision evaluation in the final examination demonstrated good stereopsis postoperatively in 88 % of patients with bilateral cataract and 43 % of patients with unilateral cataract ( $P < 0.01$ ).

## DISCUSSION

Our study design was based on experiences over the past decade. Children with cataract were grouped by age and randomly assigned to have surgery using one of the five techniques. All children received an AcrySof acrylic IOL. The importance of the IOL as a factor affecting the incidence of PCO is well recognised. Acrylic IOLs have been reported to lead to significantly lower rates of PCO than PMMA and silicon lenses. The sharp, rectangular optic edge of the AcrySof IOL also inhibits PCO. These positive characteristics, combined with its ability to be inserted through a small incision, make the AcrySof IOL the best choice for children. The biocompatibility of the AcrySof IOL was excellent in all the eyes in our study.

The management of paediatric cataract varies greatly with patient's age. There are different challenges in infants, preschool children, and juveniles. In paediatric cataract surgery, opacification of the visual axis is a disabling complication. The AcrySof IOL results in a lower visual axis obscuration rate and is biocompatible with paediatric eyes. (1,2,3)

In a worldwide survey conducted in 2001, 67 % of ASCRS respondents, and 72 % of AAPOS

respondents preferred hydrophobic acrylic IOLs for children. The results of 3-piece AcrySof are favourable. The results of 1-piece AcrySof IOLs are encouraging in adult cataract surgery, leading to its extended application in paediatric cataract surgery. The 1-piece AcrySof IOL is compatible with a small incision and the injector system. Its unique haptic configuration, combined with excellent memory, makes the IOL easy to implant and resistant to deformation.

Visual axis obscuration is a concern in children younger than 6 years because of the possibility of amblyopia, non-compliance with NdYAG capsulotomy, and anaesthesia-related complications of secondary procedure. The rate of visual axis obscuration in eyes with PCCC and PMMA IOLs in children younger than 6 years ranges from 15 % to 75 %. (1-5) In the eyes with PCC and no vitrectomy, the AcrySof IOL produces an anterior vitreous reticular response in the early postoperative period. (7,8)

Trivedi et al performed a retrospective study of 42 eyes with PCCC, vitrectomy, and 1-piece AcrySof IOL. Visual axis obscuration was observed in 16 % of all eyes, and secondary surgical intervention was required in 12 % of the eyes. This may be because primary anterior vitrectomy was performed in all eyes. (9)

When a PCCC or vitrectomy was not performed, visual axis obscuration developed in 31.4 % of the eyes with the 1-piece AcrySof IOL, and in 46 % with the

3-piece AcrySof IOL. A secondary procedure was required in 17.3 % of the eyes with a 1-piece AcrySof IOL and in 23.7 % of the eyes with a 3-piece AcrySof IOL. In a study of 42 eyes, *Trivedi and Wilson* (9) found posterior synechiae and cell deposits in 12 % of the eyes. In a study of 59 eyes, *Kugelberg et al.* (10) did not find posterior synechiae but did observe inflammatory cells on the IOL in 15 % of the eyes. The incidence of uveal inflammation was not significantly different from that in our study.

Pigment deposits and inflammatory cells on the anterior IOL surface were only seen in a few children less than 6 years of age at the time of surgery. *Vasavada et al.* (3) describe pigmented cell clumps, mainly in eyes with optic capture and anterior vitrectomy. These pigmented deposits could be a problem of anterior vitrectomy combined with optic capture performed in a strong manner. In our study the deposits and cells did not obscure the visual axis in most of the affected eyes. *Vasavada and Trivedi* report an incidence for deposits of 100 % in children having optic capture and 61 % in those with no optic capture. Another study (11) reports an incidence of 25 %, indicating that the AcrySof IOL significantly reduces the incidence of cell deposits. Posterior optic capture is technically more challenging and the results reported indicate that it is not necessary to prevent secondary cataract formation. (11)

The reported incidence of PCO if the posterior capsule is left intact is 60 % to 100 %. (11) Most reports, however, were of PMMA and HSM PMMA IOLs. Good results of AcrySof IOL implantation have been published to date (7-11). *Mullner-Eidenbock et al* (11) report on the developed PCO rate in 10 eyes of 50 eyes in which AcrySof IOLs were implanted. In our study, PCO occurred in 21 eyes of 79 eyes with posterior capsulotomy and anterior vitrectomy, and in 11 eyes of 18 eyes with an intact posterior capsule. There was a proliferative type of PCO in most of the eyes in our paediatric patients. The visual axis was clear after one secondary procedure in all eyes with PCO, at the last follow-up. We found that optic capture is not necessary to ensure a clear visual axis. However, primary posterior capsulotomy and anterior vitrectomy significantly reduce PCO rate and should be performed especially in preschool children.

In our children, we did not detect any haptic deformation with 1-piece AcrySof IOLs, because of their haptic design, as well as in *Trivedi and Wilson's* study (9).

We found that eyes with bilateral cataract were associated with significantly better visual acuity than eyes with unilateral cataract.

In conclusion, our prospective study shows that implantation of the AcrySof IOL is well tolerated in children, achieved satisfactory visual acuity with a low inflammatory response rate and excellent binocular visual outcomes. With appropriate management of the posterior capsule, AcrySof IOL implantation maintained visual axis clarity in 64 % of the eyes. Of the 36 % of eyes with visual axis opacification, 24 % required one secondary procedure to eliminate visually significant opacification. In-the-bag implantation of AcrySof IOLs is associated with a low rate of complications and acceptable visual and refractive outcomes.

## REFERENCES

1. *Wilson ME, Bartholomew LR, Trivedi RH.* Pediatric cataract surgery and intraocular lens implantation; practice styles and preferences of the 2001 ASCRS and AAPOS memberships. *J Cataract Refract Surg* 2003; 29: 1811-1820.
2. *Wilson ME, Apple DJ, Bluetein EC, Wang XH.* Intraocular lenses for pediatric implantation; biomaterials, designs, and sizing. *J Cataract Refract Surg* 1994; 20: 584-591.
3. *Vasavada AR, Trivedi RH.* Role of optic capture in congenital cataract and intraocular lens surgery in children. *J Cataract Refract Surg* 2000; 26: 824-831.
4. *Vasavada AR, Trivedi RH, Singh R.* Necessity of vitrectomy when optic capture is performed in children older than 5 years. *J Cataract Refract Surg* 2001; 27: 1185-1193.
5. *Wilson ME, Elliot L, Johnson B, et al.* AcrySof acrylic intraocular lens implantation in children. clinical indications of biocompatibility. *J AAPOS* 2001; 5: 377-380.
6. *Stager DR, Weakly DR, Hunter JS.* Long-term rates of PCO following small incision foldable acrylic intraocular lens implantation in children. *J Pediatr Ophthalmol Strabismus* 2002; 39: 73-76.
7. *Vasavada AR, Trivedi RH, Nath VC.* Visual axis opacification after AcrySof IOL implantation in children. *J Cataract Refract Surg* 2004; 30: 1073-1081.
8. *Vasavada AR, Nath VC, Trivedi RH.* Anterior vitreous face behaviour with AcrySof in pediatric cataract surgery. *J AAPOS* 2003; 7: 384-388.
9. *Trivedi RH, Wilson ME.* Single-piece acrylic intraocular lens implantation in children. *J Cataract Refract Surg* 2003; 29: 1738-1743.
10. *Kugelberg M, Kugelberg U, Babrova N, et al.* After-cataract in children having cataract surgery with or without anterior vitrectomy implanted with a single piece AcrySof IOL. *J Cataract Refract Surg* 2005; 31: 757-762.
11. *Mullner-Eidenbock A, Amon A, Moser E, et al.* Morphological and functional results of AcrySof IOL implantation in children. Prospective randomized study of age-related surgical management. *J Cataract Refract Surg* 2003; 29: 285-293.



## **RESULTS OF SURGERY IN DUANE'S RETRACTION SYNDROME: COMPARISON OF UNILATERAL RECESSION AND RESECTION VERSUS BILATERAL MEDIAL RECTUS RECESSIONS**

VODIČKOVÁ K., AUTRATA R., ŠENKOVÁ K., ŘEHŮŘEK J., PELLAROVÁ H.

Department of Paediatric Ophthalmology, Faculty of Medicine, Masaryk University Hospital, Brno

*Received after revision February 2007*

### **A b s t r a c t**

To evaluate a long-term efficacy of lateral rectus resection with medial rectus recession in the affected eye of patients with Duane's retraction syndrome (DRS) with esotropia and limited abduction, compared with bilateral medial rectus recessions.

The medical records of 23 patients with DRS who underwent a recession-resection procedure (Group A) and 26 patients with DRS who underwent bilateral medial rectus recessions (Group B) were reviewed and compared. Ocular alignment (prism dioptres-PD), head position, ocular ductions (graded from 0 = full duction to -4 = total deficit), severity of retraction, and binocular single vision field in each group were evaluated pre- and postoperatively. Statistical analysis of the data was performed.

Before surgical treatment, both groups (Group A and B) did not differ in mean primary position esotropia (21.3 and 24.7 PD, respectively), mean head-face turn (17.9° and 18.5°), average limitation of abduction (-3.2 and -3.4), or adduction (-0.4 and -0.3). After surgery, both groups had similar mean esotropia (4.2 PD and 3.5 PD), mean face turns (4.1° and 2.8°). However, the mean abduction limitation in the affected eye was greater in the group B (-1.2 and -2.6,  $P = .03$ ) and the mean adduction was significantly worse in the control group B than in the group A (-1.6 vs -0.5,  $P = .04$ ). Globe retraction improved in all subjects of the group B. It worsened in 6 patients of the group A and did not improve in the other 11. In this group, 3 patients required reoperation for undercorrection.

Seventeen of 23 patients with DRS, selected on the basis of esotropia, limited abduction, and mild retraction, benefited from a recession-resection procedure in the affected eye. Abduction improved to a higher degree as seen after bilateral medial rectus recessions. However, unilateral recession-resection procedure should be performed in patients with mild retraction of the globe and good preoperative adduction.

### **Key words**

Duane's retraction syndrome, Recession of medial rectus muscle

### **Abbreviations used**

DRS, Duane's retraction syndrome; PD, prism dioptres; BSV, binocular single vision

## INTRODUCTION

Duane's syndrome is characterised by anomalous innervation to the lateral rectus muscle, which produces subnormal abducting force and contraction of the lateral rectus muscle when attempting adduction. Esotropia, usually less than 30 PD, is the most common ocular deviation in primary position. (1,2) It presents when the limitation in abduction is greater than the limitation in adduction and when the tonus of the lateral rectus muscle in primary position is less than that of the medial rectus muscle. The limitation in adduction may cause clinical convergence deficiency manifest by a remote convergence point. (1)

Several surgical strategies have been tried to improve ocular misalignment and anomalous head position. Additional surgical goals include achieving binocular single vision in the primary position and expanding and centring the size of the diplopia-free field. Recession of the medial rectus muscle has been shown to be effective in correcting esotropia in the primary position and improving anomalous head position. However, over time there may be a gradual recurrence of the deviation and head position because of lack of abduction tone. Transpositions of the vertical rectus muscles to the lateral rectus muscle generate active abduction vector forces, which will enlarge the area of single binocular vision. (3-7)

Resection of the lateral rectus muscle of the affected eye in DRS with esotropia and limited adduction includes the risk of severely limiting adduction and worsening globe retraction on adduction. However, in selected cases, we have combined resection of the lateral rectus muscle with recession of the medial rectus muscle of the affected eye in patients with DRS. These patients had esotropia with limited abduction and mild to moderate globe retraction. We compared our results with those of the patients with DRS and limited abduction in whom we have performed bilateral medial rectus recessions, which has been a much more common option for this form of DRS.

## MATERIALS AND METHODS

We performed lateral rectus resection and medial rectus recession on the affected eye in patients with unilateral DRS syndrome with esotropia and limited abduction. All the patients who underwent this procedure in our clinic in the period from 1994 to 2002 were included in the **group A** of the comparative study. The surgery in this group involved recession of the medial rectus muscle up to 6.0 mm and resection of the lateral rectus muscle up to 4.0 mm. These limits can prevent worsening of the globe retraction. The **group B** included 26 consecutive patients with DRS with esotropia and limitation in abduction who underwent bilateral medial rectus recessions between 1993 and 2001. Follow-up time after surgery was at least 12 months.

Orthoptic measurements were taken in primary position and the secondary positions of gaze by using the prism and cover test. The patients fixated with the unaffected eye on a target at 6 m and in primary position at 0.3 m. Limitations of duction were graded on a scale from 0 (full duction) to -4 (total duction deficit). (25)

The grade of globe retraction was examined by using signs developed by J.L. Mims (26): 1) exodeviation of more than 3 PD on gaze to the nonaffected side, 2) noticeable enophthalmos and palpebral fissure narrowing more than 2 mm in full adduction compared with primary position, 3)



defective adduction as indicated by a corneal light reflection 1 mm or more inside the lateral limbus on adduction, 4) near point of convergence greater than 6 cm, and (5) upshoot or downshoot when the affected eye moves to adduction. The number of these signs was assessed in each patient. Preoperative and postoperative fields of BSV of the A group of patients were measured by a Goldmann perimeter.

Statistical analysis for nonparametric data used the Mann-Whitney test for unpaired data or the Wilcoxon test for paired data. For comparison of parametric data, we used the paired *t* test for paired data and Student's *t*-test for nonpaired data.

## RESULTS

Before surgical treatment, both groups (Group A and B) did not differ in mean primary position esotropia (21.3 and 24.7 PD, respectively), mean head-face turn (17.9° and 18.5°), average limitation of abduction (-3.2 and -3.4), or adduction (-0.4 and -0.3). After surgery, both groups had similar mean esotropia (4.2 PD and 3.5 PD), mean face turns (4.1° and 2.8°). However, the mean abduction limitation in the affected eye was greater in the group B (-1.2 and -2.6,  $P = .03$ ) and mean adduction was significantly worse in the control group B than in the group A (-1.6 vs -0.5,  $P = .04$ ). Globe retraction improved in all subjects of the group B. It worsened in 6 patients of the group A and did not improve in the other 11. In this group, 3 patients required reoperation for undercorrection. Preoperative and postoperative evaluations are summarised in *Tables 1, 2* and *Figs 1, 2*.

## DISCUSSION

Duane's retraction syndrome (DRS) is a spectrum of eye motility disorders in which the common features are retraction of the globe and narrowing of the lid fissure, both occurring on attempted adduction of the involved eye.(1,18,19) These result from anomalous co-contraction of the lateral rectus and medial rectus muscles on adduction of the involved eye, probably caused by simultaneous innervation of the lateral rectus muscle by a branch of the third nerve. (20-22) Electromyographic studies have shown that other muscles innervated by the third nerve can also co-contract with the lateral rectus muscle. (20)

Patients with DRS characterised by limited abduction and esotropia often use a significant compensatory face turn toward the affected eye to maintain binocular single vision (BSV). Various surgical approaches can be effective in treating this common form of DRS. Medial rectus recession as a sole procedure in the involved eye can eliminate the compensatory head posture. (23) Adding a large recession or a posterior fixation suture to the contralateral medial rectus muscle may enhance the range of BSV field to the affected side by partially matching rotation deficits to that side. (3,19) Transposition of the vertical rectus muscles has been advocated to improve abduction in this form of DRS. (7,27)

*Table 1*  
Clinical data in the A group patients before and after recession-resection procedure

No.	Age (y)	Surgery (mm)		Deviation in primary (PD)		Head turn (°)		Adduction		Abduction		Retraction (No. of signs)	
		MR Rec.	LR Res.	Pre ET	Post	Pre	Post	Pre	Post	Pre	Post	Pre	Post
1	4	5	3	20	Ortho	20	0	0	-1	-4	-1	2	2
2	3.5	5	3	25	Ortho	17	0	0	-1	-3	-1	2	2
3	19	6	4	30	Ortho	30	0	-0.5	-1	-4	-2.5	2	2
4	4.5	5	3	18	6 XT	12	10	0	0	-3	-2	1	3
5	5.6	5	4	16	12 ET	11	11	0	0	-4	-3	2	4
6	7.5	4	3	10	4 ET	15	9	-0.5	0	-4	-3	2	3
7	4.5	5	3	12	Ortho	16	0	0	-0.5	-3	-3	4	4
8	6	4	3	24	Ortho	12	0	0	0	-4	-3	1	3
9	10	5	3	16	Ortho	15	5	0	-1	-4	-3	3	4
10	4	5	3	20	8 ET	20	0	0	-1	-4	-1	2	2
11	3	5	3	25	Ortho	17	0	0	-1	-3	-1	2	2
12	14	6	4.5	30	Ortho	30	0	-0.5	-1	-4	-2	2	2
13	3	5	3	10	6 XT	12	10	0	0	-3	-2	1	4
14	5.8	5	4	25	16 ET	18	11	0	0	-4	-3	2	3
15	7	4	3	18	4 XT	15	9	-0.5	0	-3	-3	2	4
16	4	5	3	24	6 ET	16	0	0	-0.5	-4	-3	4	4
17	6	4	3	18	Ortho	12	0	0	0	-4	-3	1	3
18	12	5	3	16	Ortho	15	5	0	-2.0	-4	-3	3	3
19	9	5	3	20	4 XT	20	0	0	-1	-4	-1	2	2
20	4	5	4	25	Ortho	17	0	0	-1	-3	-1	2	2
21	13	6	4	30	10 ET	30	0	-0.5	-1	-4	-2	2	3
22	3.5	5	4	20	6 XT	12	10	0	0	-4	-2	1	1
23	6.5	5	4	26	Ortho	11	11	0	0	-4	-3	2	2
<b>Mean</b>	<b>8.2</b>	<b>4.8</b>	<b>3.4</b>	<b>21.3</b>	<b>4.2</b>	<b>17.9</b>	<b>4.1</b>	<b>-0.4</b>	<b>-0.5</b>	<b>-3.1</b>	<b>-1.2</b>	<b>2.3</b>	<b>3.2</b>

ET= Esotropia; LR= lateral rectus; MR= medial rectus; Ortho= orthophoria; PD= prism dioptries; Post= after surgery;

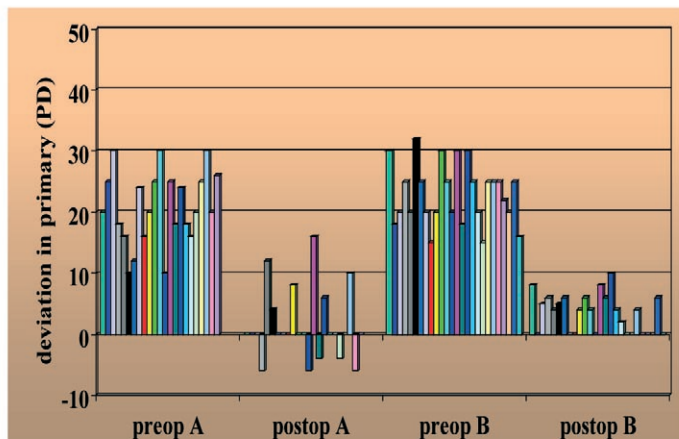
Pre= before surgery; Rec= recession; Res= resection; XT= exotropia

*Table 2*  
Data of the B group patients before and after bilateral m. r. recession procedure

No.	Age (y)	MR recession (mm)		Head turn (°)		Esotropia in primary (PD)		Adduction		Abduction		Retraction (No. of signs)	
		Affected eye	Non affected eye	Pre	Post	Pre	Post	Pre	Post	Pre	Post	Pre	Post
1	8	6	5	15	4	30	8	0	-2	-4	-4	2	1
2	3.5	5	4	10	0	18	0	1	-1.5	-3	-2	2	1
3	21	5	5	15	3	20	5	-0.5	-2	-4	-2	2	1
4	13	6	5	20	5	25	6	-0.5	-2	-3	-2	3	2
5	19	5	4	10	5	20	4	0	-1.5	-4	-3.5	2	1
6	11	7	5	18	3	32	5	1	-2	-4	-3	2	0
7	8	6	5	15	0	25	6	0	-1	-3	-2	2	0
8	6	5	5	12	0	20	0	0	-0.5	-4	-2.5	2	1
9	17	6	4	18	0	15	0	-0.5	-1	-3.5	-3	2	0
10	5.5	5	5	15	0	20	4	-0.5	-1	-2.5	-1.5	1	0
11	14	7	5	20	5	30	6	0	-2	-4	-4	2	1
12	8.5	6	5	18	0	25	4	1	-1.5	-4	-2	2	1
13	7	5	4	20	8	20	0	-0.5	-2	-4	-2	2	1
14	9	7	5	25	10	30	8	-0.5	-2	-3	-2	3	2
15	8	5	6	10	5	18	6	1	-1.5	-4	-3	2	1
16	22	8	6	15	0	30	10	0	-2	-4	-3	2	0
17	19	6	5	18	0	25	4	0	-1	-3	-2	2	0
18	5	6	5	18	0	20	2	0	-0.5	-4	-2	2	1
19	13	5	5	12	0	15	0	-0.5	-1	-3	-2	2	0
20	7.5	6	6	22	3	25	0	-0.5	-1	-2.5	-1	1	0
21	4	8	5	25	10	25	4	0	-2	-4	-4	2	1
22	15	7	6	20	5	25	0	1	-1.5	-3.5	-2	2	1
23	7	6	6	15	0	22	0	-0.5	-2	-4	-2	2	1
24	9	6	5	20	0	20	0	-0.5	-2	-3	-2	3	2
25	16	7	6	25	5	25	6	0	-1.5	-4	-3	2	1
26	12	6	5	18	0	16	0	0	-2	-4	-3	2	0
<b>Mean</b>	<b>11.3</b>	<b>6.1</b>	<b>5.2</b>	<b>18.5</b>	<b>2.8</b>	<b>24.7</b>	<b>3.5</b>	<b>-0.3</b>	<b>-1.6</b>	<b>-3.4</b>	<b>-2.6</b>	<b>2.1</b>	<b>0.7</b>

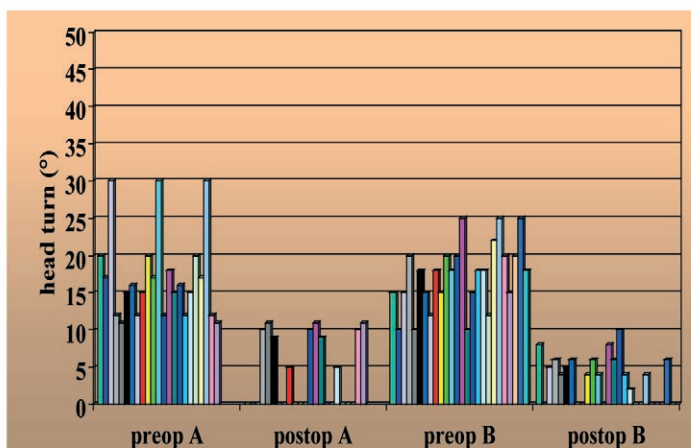
ET= Esotropia; LR= lateral rectus; MR= medial rectus; Ortho= orthophoria; PD= prism diptres; Post= after surgery;

Pre= before surgery; Rec= recession; Res= resection; XT= exotropia



*Fig. 1*

Deviation in primary position pre- and postoperatively in both groups of each patient with Duane's syndrome



*Fig. 2*

Head turn (°) pre- and postoperatively in both groups of each patient with Duane's syndrome

Transposition of the vertical rectus muscles to the lateral rectus improves the anomalous face turn, the deviation in the primary position, and abduction in patients with Duane's syndrome and esotropia. Horizontal transpositions of the vertical rectus muscles toward the lateral rectus muscle can restore the equilibrium

of the ocular muscles forces in primary position and move the eye toward the physiological field of gaze. (4,7,8) Transpositions may create some restriction in adduction, mainly if severe innervational anomalies are present. Undercorrections, overcorrections, induced vertical deviations, and worsening of co-contraction with anomalous vertical movements (1,3,5,6,11,12) have been reported in up to 30 % of the patients who underwent horizontal transposition of the vertical rectus muscles to the lateral rectus muscle. Previous studies have suggested that undercorrections after transpositions may be treated with botulinum toxin to the ipsilateral medial rectus or recession of the contralateral medial rectus muscle to avoid overcorrections. (7,13)

*Velez et al* (29) reported that vertical rectus transposition surgery was effective in improving abduction and expanding the size of the binocular single visual field. Adding posterior lateral fixation sutures resulted in fewer undercorrections and surgically induced vertical deviations. He suggested that the augmented transposition seems to be effective even in the presence of medial rectus restriction. Patients with mild to moderate limitation to abduction on the force duction test show larger binocular visual fields after transpositions.

Lateral transposition of the vertical rectus muscles has been shown to improve the abduction of the affected eye and improve the range of BSV field into the ipsilateral field of gaze. (7) In their study of vertical muscle transposition, *Molarte* and *Rosenbaum* (6) showed that this approach can improve abduction ability and increase the horizontal BSV field size. Although they did not report the average width of their patients' BSV fields, they stated that some patients gained 60° of diplopia-free field. However, 46 % of their patients required additional medial rectus weakening surgery and 15 % developed a vertical deviation. *Foster* (7) reported a good expansion of the BSV field to the ipsilateral side in patients with DRS on whom he performed full-tendon transpositions with posterior fixation sutures. However, this procedure also runs the risk of inducing vertical tropias. Undercorrections following vertical muscle transpositions could necessitate weakening of the ipsilateral medial rectus muscle, with the attendant risk of anterior segment ischaemia.

In unilateral DRS with esotropia and limited abduction, surgical treatment is aimed at achieving orthotropia in primary position and eliminating a compensatory head posture and, where possible, disfiguring globe retraction. In addition, it should try to maximise the range of the BSV field, which ideally should be centred around the primary position. The field can be enlarged by matching the range of ductions in the 2 eyes. (3,19,24-26) Bilateral medial rectus recession has been the most common procedure used by the authors for patients with DRS with esotropia. In our study the B group included patients who underwent this surgery.

Our results suggest that the surgeon should limit the recession of the medial rectus muscle to no more than 5.0 mm when a lateral rectus resection is added. The medial rectus muscle recession is required to release restricted forced ductions to

abduction and thus facilitate improvements in abduction. The trade-off in some of our patients was a worsening of the signs of globe retraction. Minimisation of the chances of worsening the retraction is achieved best by limiting the resection to no more than 3.0 or 3.5 mm. While this amount would be considered inadequate for esotropia surgery in patients without DRS, our results show that it can form an effective part of the surgical plan for patients with DRS with esotropia and limited abduction. Small resections of the lateral rectus muscle can be effective in this form of Duane's syndrome due to the abnormal muscle structure noted in these cases. The lateral rectus muscle in Duane's syndrome is stiffer and, as a result, has a higher length-tension curve than a normal lateral rectus muscle. (28) The size of the esotropia in primary position is another factor that must be considered before undertaking a recession-resection procedure. The angle of the esotropia should be at least 14 or 15 PD to avoid the risk of an overcorrection.

*Collins et al* (10) found the medial rectus muscle in Duane's syndrome to be mechanically different from a contracted medial rectus muscle in an esotropic patient with limitation of abduction. The medial rectus muscle in Duane's syndrome with esodeviation does not show contracture in the primary position. There is no passive mechanical restrictive force of the medial rectus muscle near the primary position to be released by recession of the medial rectus muscle in the involved eye, except beyond 10° to 15° of abduction.

Only patients with minimal signs of globe retraction (3 or fewer by our criteria) would benefit from a recession-resection procedure on the affected eye. We would not recommend using this procedure on patients with DRS with marked upshoots or downshoots, eyelid narrowing of more than 50 % on adduction, or unusually stiff, fibrotic lateral rectus muscles. This method does offer advantages, however, when used on the appropriate patients: it is a straightforward procedure that does not put the normal eye at any surgical risk. A small resection is easily reversible should signs of globe retraction worsen or an overcorrection occur. Undercorrections can be solved by further weakening the ipsilateral medial rectus muscle or weakening the contralateral medial rectus muscle.

Recession of the ipsilateral medial rectus muscle can eliminate abnormal face turn but generally produces only minimal improvement in abduction, thus limiting the range of BSV to the ipsilateral side. (23) Surgeons often add a recession or posterior fixation of the contralateral medial rectus muscle to match duction deficits and improve the range of abduction in the affected eye, thus expanding the range of BSV to the ipsilateral side. (3,24-26) A previous study (3) showed that relatively large recessions (up to 8 mm) of both medial rectus muscles can increase the field of BSV to both a right and left gaze to an average total field width of 30°. However, this study reported postoperative worsening of adduction limitations.

Pressman and Scott have reported that medial rectus muscle recessions for unilateral Duane's syndrome improve the angle of deviation in the primary position and the anomalous head position in 100 % of the patients with a final binocular

visual field of 30°, including primary position. Fifty-seven per cent of those patients were orthotropic in primary position. The face turn was eliminated in 85 % of the patients. Their analysis of ocular rotations demonstrated a limitation of adduction in all 12 patients. Only 25 % of the 12 patients had a minimal improvement in abduction.(3)

Other studies have also shown that unilateral or bilateral medial rectus recessions may markedly decrease adduction and cause a consecutive exotropia, synergistic divergence, or limited ocular rotations, which are very difficult to manage. (10,14,17)

In summary, we found that ipsilateral recession-resection procedures in patients with DRS with esotropia can improve abduction and eliminate compensatory face turns comparable with those achieved by the more traditional surgery of bilateral medial rectus recessions. However, a recession-resection procedure should be performed in patients with mild retraction of the globe and good preoperative adduction. The esotropia in primary position preoperatively should be at least 15–20 PD to reduce the risk of overcorrection. Limiting the resection of the lateral rectus muscle to 3.5–4 mm can minimise the risks of worsening adduction and retraction. Based on the results found in our study we can support the conclusions as reported by *Morad et al.*, but further studies with larger groups of patients are needed to confirm these results.

#### REFERENCES

1. *DeRespinis PA, Caputo AR, Wagner RS, Guo S.* Duane's retraction syndrome. *Surv Ophthalmol* 1993; 38: 257–288.
2. *Shaully Y, Weissman A, Meyer E.* Ocular and systemic characteristics of Duane syndrome. *J Pediatr Ophthalmol Strabismus* 1993; 30: 178–183.
3. *Pressman SH, Scott WE.* Surgical treatment of Duane's syndrome. *Ophthalmology* 1986; 93: 29–38.
4. *Saunders RA, Wilson ME, Bluestein EC, Sinatra RB.* Surgery on the normal eye in Duane retraction syndrome. *J Pediatr Ophthalmol Strabismus* 1994; 31: 162–169.
5. *Metz HS.* 20th annual Frank Costenbader lecture: Muscle transposition surgery. *J Pediatr Ophthalmol Strabismus* 1993; 30: 346–353.
6. *Molarte AB, Rosenbaum AL.* Vertical rectus muscle transposition surgery for Duane's syndrome. *J Pediatr Ophthalmol Strabismus* 1990; 27: 171–177.
7. *Foster RS.* Vertical muscle transposition augmented with lateral fixation. *J AAPOS* 1997; 1: 20–30.
8. *Laby DM, Rosenbaum AL.* Adjustable vertical rectus muscle transposition surgery. *J Pediatr Ophthalmol Strabismus* 1994; 31: 75–78.
9. *Gobin MH.* Surgical management of Duane's syndrome. *Br J Ophthalmol* 1974; 58: 301–306.
10. *Collins CC, Jampolsky AL, Howe PS.* Mechanical limitations of rotation. In: Scott AB, ed. *Mechanics of strabismus: a symposium on oculomotor engineering*. San Francisco: The Smith Kettlewell Eye Research Institute; 1992. p. 19–40.
11. *Wybar KC.* Management of sixth nerve palsy and Duane's retraction syndrome. *Trans Ophthalm Soc UK* 1981; 101: 276–278.
12. *Carlson MR, Jampolsky AL.* An adjustable transposition procedure for abduction deficiencies. *Am J Ophthalmol* 1979; 87: 382–387.
13. *Clark RA, Rosenbaum AL, Demer JL.* Magnetic resonance imaging after surgical transposition defines the anteroposterior location of the rectus muscle pulleys. *J AAPOS* 1999; 3: 9–14.
14. *Goldstein JH, Sacks DB.* Bilateral Duane's syndrome. *J Pediatr Ophthalmol Strabismus* 1978; 14: 12–17.

15. *Nelson LB.* Severe adduction deficiency following a large medial rectus recession in Duane's retraction syndrome. *Arch Ophthalmol* 1986; 104: 859-862.
16. *Noel LP, Clarke WN.* Adduction deficiency following medial recti recession in Duane's retraction syndrome. Case report. *Arch Ophthalmol* 1987; 105: 465.
17. *Shiratori A, Kameyama C, Sibasaki K.* Adduction deficiency following a large medial rectus recession in Duane's retraction syndrome type 1. *J Pediatr Ophthalmol Strabismus* 1999; 36: 98-100.
18. *Duane A.* Congenital deficiency of abduction, associated with impairment of adduction, retraction movements, contraction of the palpebral fissure and oblique movements of the eye. *Arch Ophthalmol* 1995; 34:133-159.
19. *Kraft SP.* A surgical approach to Duane syndrome. *J Pediatr Ophthalmol Strabismus* 1988; 25: 119-130.
20. *Scott AB, Wong G.* Duane's syndrome. An electromyographic study. *Arch Ophthalmol* 1972; 87: 140-147.
21. *Metz HS.* Duane's retraction syndrome. *Arch Ophthalmol* 1982; 100: 843-844.
22. *Raab EL.* Clinical features of Duane's syndrome. *J Pediatr Ophthalmol Strabismus* 1986; 33: 64-68.
23. *Kaban TJ, Smith K, Day C, Orton R, Kraft S, Cadera W.* Single medial rectus recession in unilateral Duane syndrome type I. *Am Orthopt J* 1995; 45: 108-114.
24. *Kraft SP, Clarke MP.* Surgical treatment of Duane's retraction syndrome. *Ophthalmol Clin North Am* 1992; 5: 79-92.
25. *Saunders AS, Wilson ME, Bluestein EC, Sinatra BS.* Surgery on the normal eye in Duane retraction syndrome. *J Pediatr Ophthalmol Strabismus* 1994; 31: 162-169.
26. *Mims JL.* Choice of surgery for Duane's retraction syndrome. In: Van Heuven WAJ, Zwaan J, eds. *Decision making in ophthalmology.* St Louis: Mosby; 1992. p. 162-163.
27. *Feretis D, Papastratigakis B, Tsamprarakis J.* Planning surgery in Duane's syndrome. *Ophthalmologica* 1981; 183: 148-153.
28. *von Noorden GK.* *Binocular vision and ocular motility.* 5th ed. St Louis: Mosby; 1996. p. 430-437.
29. *Velez FG, Foster RS, Rosenbaum AL.* Vertical rectus muscle augmented transposition in Duane syndrome. *J AAPOS* 2001; 5: 105-113.