

## **TRANS-SCLERAL DIODE LASER CYCLOPHOTOCOAGULATION IN CHILDREN WITH REFRACTORY GLAUCOMA. LONG-TERM OUTCOMES**

AUTRATA R., LOKAJ M., ŘEHŮŘEK J.

Department of Paediatric Ophthalmology, Paediatric Teaching Hospital, Faculty of Medicine,  
Masaryk University, Brno

### **A b s t r a c t**

The aim of this study was to evaluate the efficacy of diode laser cyclophotocoagulation in paediatric patients with refractory glaucoma and to assess complications associated with this method. The study included 69 eyes in 53 children with uncontrolled refractory glaucoma who underwent diode laser cyclophotocoagulation (cyclodiode) treatment. The mean age of this group was 6.1 years (range, 0.9 to 15 years). Intraocular pressure (IOP) and visual acuity were the main parameters evaluated and complications were recorded. The mean follow-up was 4.5 years (range, 1.7 to 8.5 years). The diagnoses included aphakic glaucoma, anterior segment dysgenesis, congenital glaucoma, aniridia, juvenile chronic arthritis and Sturge-Weber syndrome. Fifty-two percent of eyes were aphakic and 78% had undergone at least one previous surgical procedure for glaucoma. The patients underwent a mean of 2.1 treatment sessions per eye (range, 1 to 6). The mean preoperative IOP value was 34.0 mmHg and the mean postoperative value was 20.8 mmHg at the end of the study ( $P < 0.05$ ). With repeat cyclodiode treatments (mean interval between two successive treatments, 7.1 month), 79% of the eyes had IOP less than 21 mmHg at 1 year and 63 % at 2 years. Four eyes developed subsequent choroidal detachment and two eyes had retinal detachment with a loss of vision. Apart from them, no eyes lost their preoperative vision because of cyclodiode-related complications. It is concluded that cyclophotocoagulation by diode laser is a useful therapy for the treatment of refractory paediatric glaucoma with uncontrolled intraocular pressure. The repeated treatment can provide effective control of IOP with a low risk of severe complications.

### **Key words**

Diode laser, Cyclodestructive procedure, Glaucoma, Children

### **INTRODUCTION**

Glaucoma in children, particularly secondary and advanced glaucoma, is difficult to manage. Drainage surgery may be complicated by hypotony when the eye is large and has a thin sclera and/or by failure to control intraocular pressure (IOP) caused by an aggressive healing response. In patients whose glaucoma cannot be controlled by drainage procedures, treatment may be difficult and associated with a considerable risk.

The diode laser cyclophotocoagulation (laser cycloablation, cyclodiode) is a relatively new method of ciliary epithelium ablation to reduce IOP. Previously,

the most common method used for cycloablation has been cyclocryotherapy. A successful outcome of cyclocryotherapy may be limited by intraocular inflammation and potentially devastating complications (1,2).

Laser cycloablation is generally considered to be more effective and better tolerated by the patient than cyclocryotherapy (3). Large clinical studies have confirmed that cyclodiode treatment is reasonably effective and safe (4,5).

We present data on a group of paediatric patients (age < 15 years) with refractory glaucoma, who underwent cyclodiode treatment at the Department of Ophthalmology, Faculty of Medicine, Masaryk University in Brno, with the aim to evaluate the effectiveness and safety of this procedure.

## MATERIALS AND METHODS

The clinical records of patients younger than 15 years who had undergone cyclodiode treatment between March 1993 and December 2000 were reviewed and only the patients followed up for more than 12 months were included. A total of 69 eyes in 53 patients were entered in this study. Of the total 69 eyes, 31 received the treatment once (45%), 18 eyes twice (26%), 10 eyes three-times (14.5%) and 10 eyes four-times and more (14.5%). A total of 162 cyclodiode procedures were performed, with a mean of 2.1 sessions per eye (range, 1 to 6 sessions). The mean age at the time of the first session was 6.1 years (range, 0.9 to 15 years). The mean follow-up was 4.5 years (range, 1.7 to 8.5 years).

Diagnoses and previous operative procedures are shown in *Table 1*. Aphakic glaucoma and congenital glaucoma were the most common diagnoses. Of the 69 eyes, 27 (39%) had undergone at least one surgical procedure for glaucoma; the mean number of previous glaucoma procedures was 2.3.

Cyclodiode treatment was based on the following indications: (i) advanced glaucoma after previously failed surgical procedures, (ii) markedly elevated IOP (in these eyes IOP control was required before the definitive surgery), (iii) moderately elevated IOP (in eyes with maximum medication, in which risks associated with drainage surgery were high) and (iv) blind painful eye with elevated IOP.

IOP measurements were made by Goldmann tonometry in the patients who could be examined with the use of a slit lamp and who cooperated well. In the patients examined under anaesthesia, IOP was measured with a Perkins tonometer (Tono-Pen or ProTon; Tomey).

All cyclodiode procedures were performed under general anaesthesia. A lid speculum was used to permit adequate access to the treated eye. Transillumination was used in all cases to demonstrate the position of the ciliary body, because its location varies considerably in enlarged and abnormal eyes.

The following treatment conditions were used in all cyclodiode sessions: 35 applications at 2000 mW for 1500 ms on average, the use of a portable diode laser and a contact probe (Nidek DC 3000, Tokyo, Japan).

Topical corticosteroids were administered four- to eight-times daily for 6 weeks after treatment. When a satisfactory IOP response to treatment was obtained, the patient was converted to a low-dose maintenance medication. When there was no adequate IOP response or the initial IOP effect was lost, a repeat treatment of up to six sessions was undertaken.

The duration of follow-up depended on individual circumstances. On each visit, IOP, visual acuity and a full clinical examination were carried out when possible. On the average, each patient was examined at 1 and 3 months and then at intervals required by the eye status. IOP was recorded at dates as close as possible to the periods of 1 week, 1, 3, 6, 9, 12 and 18 months after treatment and on the last visit. The treatment was defined as successful when IOP was reduced to 21 mmHg or less.

The statistical analysis was performed with the use of the Wilcoxon test, Fisher's exact test and Kaplan-Meier survival curve. The results were presented as mean  $\pm$ SD values.

The Ethics Committee of the Paediatric Teaching Hospital at the Faculty of Medicine approved of this study.

Table 1

Glaucoma diagnoses and previous surgical procedures in our group of 69 eyes

Diagnosis	Number of eyes affected
Congenital glaucoma	19 (27,5%)
Aphakic glaucoma	16 (23,2%)
Uveitic glaucoma	11 (15,9%)
Anterior segment dysgenesis	9 (13%)
Aniridia	7 (10,2%)
Secondary angle-closure glaucoma	5 (7,3%)
Sturge-Weber syndrome	2 (2,9%)
Previous Surgery	Number of procedures*
Trabeculectomy	29 (26%)
Cataract surgery	18 (16%)
Trabeculectomy with mitomycin	16 (14%)
Cyclocryotherapy	12 (11%)
Goniotomy	11 (10%)
Trabeculotomy	8 (7%)
Molteno drainage tube	7 (6%)
Pars plana vitrectomy	5 (5%)
Cryotherapy for retinopathy of prematurity	3 (3%)
Total no. of procedures	109

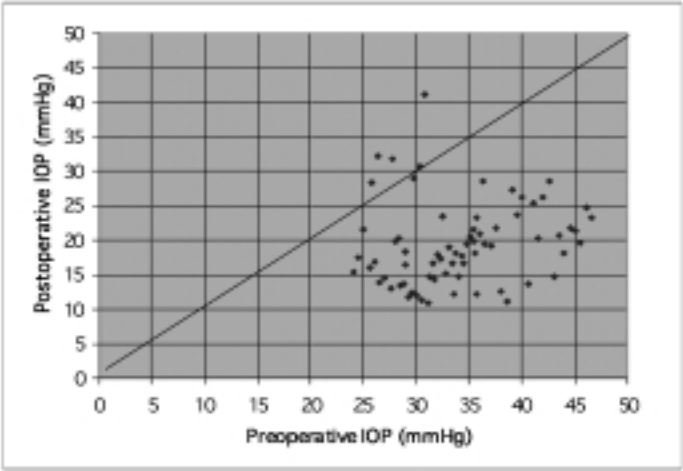
\*Some children underwent more than one surgical procedure in the eye involved.

## RESULTS

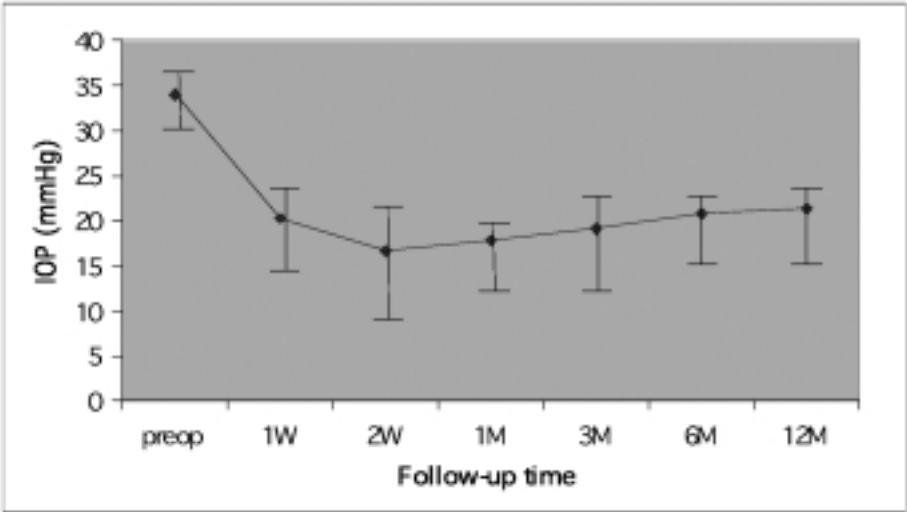
### INTRAOCULAR PRESSURE

The mean pretreatment IOP value for the whole patient group was  $34.0 \pm 7.1$  mmHg and it decreased to  $20.8 \pm 6.38$  mmHg at the end of the study. At 3 months after the first treatment session, the mean IOP value was  $19.1 \pm 6.7$  mmHg ( $P < 0.05$ ). The scatter chart shows preoperative and postoperative IOP values for the first treatment session (*Fig. 1*). The mean period from the first treatment to the final IOP assessment was 10.7 months. After the first session, there was a marked decrease in the mean IOP value, with a small regression during the following year (*Fig. 2*). The decrease in mean IOP values in response to repeated cyclodiode treatment (*Fig. 3*) implied that the repeated procedure was effective in IOP reduction.

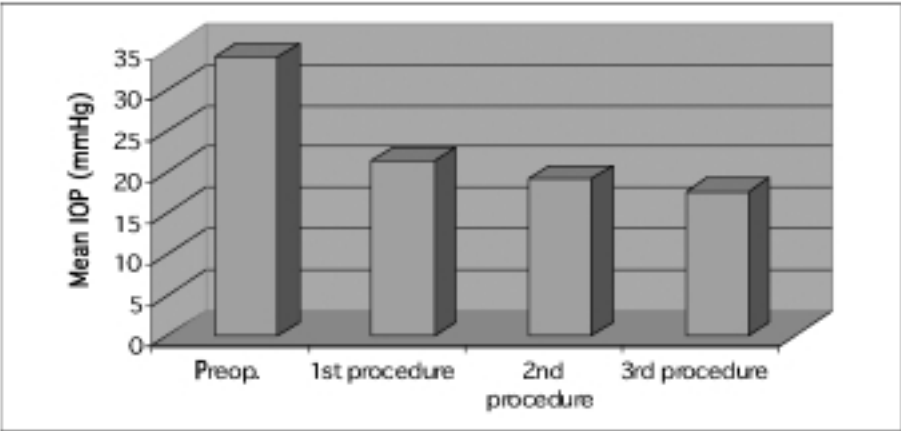
Of the 69 (68%) cases treated, 47 achieved a reduction of IOP to  $< 21$  mmHg by a single procedure. After repeated treatments, sustained control of IOP to 21 mmHg was achieved in 79% of the eyes at 1 year, 63% at 2 years and 48% at 5 years, as demonstrated by the Kaplan-Meier survival curve (*Fig. 4*). In these eyes, the mean period between two subsequent sessions was 7.1 months.



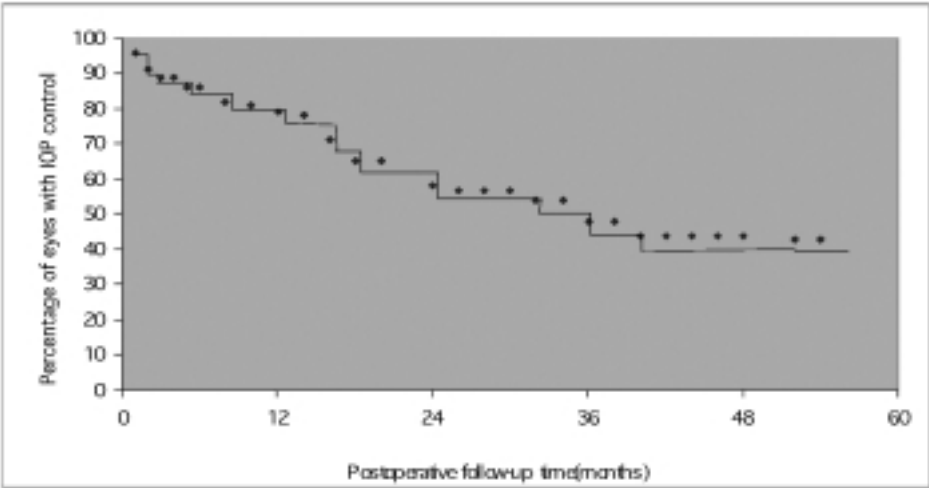
*Fig. 1*  
Scatter chart of preoperative and postoperative intraocular pressure (IOP) values after the first laser cyclophotocoagulation.



*Fig. 2*  
The mean intraocular pressure after the initial cyclophotocoagulation treatment. Error bars represent 95% confidence intervals. W, week; M, month; IOP, intraocular pressure.



*Fig. 3*  
Reduction in the mean IOP value after the first, second and third cyclodiode treatments. IOP, intraocular pressure.

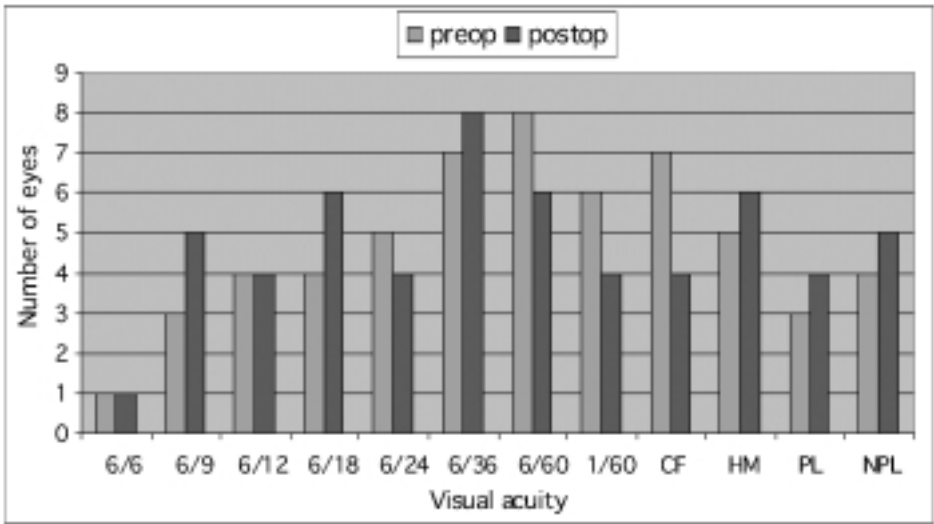


*Fig. 4*  
Kaplan-Meier survival curve demonstrating the percentage of eyes with intraocular pressure control achieved by multiple cyclodiode procedures. IOP, intraocular pressure.

The mean numbers of antiglaucoma drugs administered before cyclodiode therapy and at the end of follow-up were  $1.68 \pm 1.5$  and  $2.17 \pm 1.3$ , respectively ( $P > 0.01$ ). The increase in medication was because of the fact that new drugs, such as dorzolamide and latanoprost, became available during the study period and were therefore used.

### VISUAL ACUITY

We examined 57 of the 69 eyes. In the rest it was not possible because of poor cooperation of the children. Of the 57 eyes examined, 19 (33 %) had visual acuity at the level of finger counting or worse before treatment. For most of the patients, visual acuity remained constant. One or more levels of vision were lost in 6 of 57 eyes (10.5%). All eyes losing vision had a pretreatment value of 6/60 or worse. These eyes lost vision either because of postoperative complications or due to progression of severe glaucoma. On the other hand, in some of the treated eyes, visual acuity improved because of visual maturation or resolution of corneal oedema.



*Fig. 5*  
Visual acuity levels before and after laser treatment. CF, counting fingers; HM, hand movements; PL, light perception; NPL, no perception of light.

## COMPLICATIONS

Two eyes with aphakic, very advanced glaucoma in two patients had untreatable retinal detachment with a loss of vision. This occurred after the second cyclodiode session. These patients had received previous YAG laser cycloablation. Four eyes subsequently developed choroidal detachment with a decrease in vision. The treatment of nine eyes of 69 (13%) resulted in a significant postoperative uveitis, which was successfully treated with topical and systemic corticosteroids. Topical nonsteroidal anti-inflammatory treatment (ketorolac or diclofenac) was required in some cases to alleviate pain. Subsequent glaucoma drainage surgery was performed in 8 of 69 eyes (11.6%).

## DISCUSSION

Several procedures are available to manage childhood glaucoma. We believe that primary congenital glaucoma should always be treated by surgical intervention, goniotomy or trabeculotomy. Cyclodestruction or aqueous tube-shunt implantation are used for treatment of refractory congenital glaucoma, aphakic glaucoma or other secondary childhood glaucomas. However, the success of external filtering surgery in children has many barriers.

This study was concerned with refractory glaucoma in children managed by diode laser trans-scleral cyclophotocoagulation. Our results are similar to those of another series of paediatric patients reported by *Kirwan et al.* (5), and *Bock et al.* (6). Compared with adults treated according to the same protocol, the treatment in children had a similar effect on IOP reduction but had a shorter duration (4,7).

A single cyclodiode procedure reduced IOP in 60% of the patients but, in some cases, the treatment did not long, particularly in very young patients. These required repeated treatment to achieve long-term control of IOP. Diode laser cycloablation cannot replace drainage procedures in the management of refractory, secondary paediatric glaucomas but the patients in this study were poor candidates for drainage procedures, particularly those with aphakic eyes that may be predisposed to severe posterior segment complications after drainage procedures.

Surgical treatment in paediatric aphakic glaucoma is difficult. Trabeculectomy, with or without antimetabolites, may have a low rate of long-term success in young patients (8,9). The implantation of a glaucoma drainage device offers moderate to good success rates, depending on the patient population (10–15). In older subjects, treatment outcomes are generally better. Success rates are between 50% and 90% at 1 year but may decrease with an increasing follow-up duration. The use of drainage devices can maintain IOP in the normal range and allow for a significant reduction in medication (16). Severe complications, including suprachoroidal haemorrhage, choroidal detachment or hypotony have been reported (12,13,14,17). Studies on aphakic or very young patients tend to show even worse results.

Trabeculectomy in secondary glaucomas or advanced, previously treated congenital glaucoma requires the use of antimetabolites, usually mitomycin-C. This approach has been reported to have good results, particularly in older children. Long-term results may be poorer in younger aphakic patients (8,9,18). The development of bleb leaks and/or late endophthalmitis may be an additional complication (19).

In our patients, a large proportion of eyes had previous glaucoma surgery. Such patients generally tend to have a poor prognosis after further drainage surgery. Most of the eyes in our study were aphakic, which is also associated with a poor surgical prognosis. Therefore cyclodiode treatment was the method of choice and it resulted in a low rate of severe adverse effects; only 4 of 69 eyes (5.8%) lost vision because of treatment. Although corticosteroids were administered postoperatively, uveitis occurred in nine eyes (13%). These figures are higher than those in studies on adult glaucoma but lower than the figures reported for cyclocryotherapy or tube-shunt procedures in paediatric patients (3,12,17).

Other methods of cycloablative treatment include cyclocryotherapy, Nd:YAG laser cyclo-ablation and endocyclophotocoagulation. The long-term results of cyclocryotherapy in paediatric patients have been reported with an IOP control rate of 66% at 6 months and 44% at 4.8 years (3). Severe complications affected 10 of 64 (16%) eyes in this study.

In refractory paediatric glaucomas treated by Nd:YAG laser cycloablation, results with a 50% success rate have been reported (20). Nd:YAG laser cycloablation has been compared with cyclodiode in adult patients (21). Both modalities offer similar treatment effects, but Nd:YAG laser treatment may have a higher rate of adverse effects, including sympathetic ophthalmia (22). One disadvantage of using a contact diode laser for cycloablation in adults may be a potentially higher rate of repeat treatment, as compared with YAG laser (23). In our study, two eyes with retinal detachment had had YAG cycloablation before cyclodiode treatment. These eyes were treated with great caution, appropriate to this condition. With repeated cyclodiode treatment, there is always concern that hypotony may eventually develop and, therefore, repeat treatments should be used only when surgery is contraindicated. A study by *Bock et al.* on the use of trans-scleral diode laser cyclophotocoagulation for refractory paediatric glaucomas reported similar findings, with a 50% success rate at 6 months and a 70% retreatment rate (6).

Experience with endocyclophotocoagulation remains limited. In the 1997 series of 68 patients ranging in age from 1 to 86 years (mean,  $58.3 \pm 24.1$ ), *Chen et al.* (24) reported a 90% success rate (IOP, 21 mmHg) with the use of a new diode laser microendoscope. The mean follow-up was  $12.9 \pm 5.1$  months and the retreatment rate was only 7%. Twelve eyes had a primary diagnosis of congenital glaucoma and 10 eyes had aphakic/pseudophakic glaucoma. Visual acuity was stable or improved in



94% of the patients after the operation (24). In the same year, *Mora et al* (25) reported a small group of eight eyes, including five eyes of three paediatric patients treated by endolaser. The follow-up was short (mean, 5.1 months) and seven eyes (88%) had a postoperative IOP of 22 mmHg. The retreatment rate was 38%, with an average of 1.6 treatments per eye. In either series, no significant complications (retinal detachment, phthisis, endophthalmitis or sympathetic ophthalmia) were observed. *Gayton* (26) reported an incident of traumatic aniridia in which the iris became adherent to the endolaser probe during cyclophotocoagulation and was torn loose upon withdrawal of the instrument. *Neely and Plager* (27) reported two cases of retinal detachment following endocyclophotoablation. These procedures appeared uneventful and the cause of the postoperative retinal detachment remained unknown. The success rate of endocyclophotoablation in their study was similar to that obtained with either cryotherapy or externally applied trans-scleral laser procedures. Compared with externally applied laser, endoscopic ciliary body destruction requires repeat treatment less frequently and is probably more anatomically suited to abnormal eyes.

*Phelan and Higginbotham* (20) reported a series of 10 paediatric eyes treated with trans-scleral Nd:YAG laser cyclophotocoagulation and found a 50% success rate (IOP < 21 mmHg) after an average follow-up of  $15.5 \pm 5.0$  months. The retreatment rate was 70% and each eye underwent an average of 2.4 treatments. Other studies in adult patients have noted scleral thinning or sympathetic ophthalmia as rare complications of trans-scleral Nd:YAG laser cyclophotocoagulation (28,29) *Bock et al.* reported similar experience when using trans-scleral diode laser (6). Their overall success rate was 50% (IOP, 21 mmHg) after an average follow-up of  $18.5 \pm 10.8$  months. The retreatment rate was 70%, and the patients received an average of 2.2 laser treatments (range, 1 to 6). Retinal detachment occurred in one patient and visual loss was recorded in four of 22 eyes with reliable visual acuities. The most relevant data on treatment with the use of trans-scleral Nd:YAG, endoscopic diode and trans-scleral diode laser cycloablation procedures are summarised (6, 20, 27) and compared with our results below.

Characteristics	<b>Trans-scleral Nd:YAG</b> Phelan et al. (20)	<b>Endoscopic diode</b> Neely and Plager (27)	<b>Trans-scleral diode</b> Bock et al. (6)	<b>Tran-sscleral diode</b> Our study
No. of eyes	10	36	26	69
Baseline IOP, mmHg	$34.1 \pm 4.2$	$35.06 \pm 8.55$	$34.2 \pm 10.4$	$34.0 \pm 7.1$
Follow-up, mo	$15.5 \pm 5.0$	$19.2 \pm 19.4$	$18.5 \pm 10.8$	$54 \pm 31.2$
No. of treatments (range)	$2.4 \pm 1.3$ (1–4)	$1.4 \pm 0.9$ (1–4)	$2.2 \pm 1.3$ (1–6)	$2.1 \pm 1.7$ (1–6)
Final IOP, mmHg	Not presented	$23.6 \pm 11.1$	$21.2 \pm 10.0$	$20.8 \pm 6.38$
Criterion of success (mmHg)	IOP<21	IOP= 21	IOP= 21	IOP <21
Success rate	50%	43%	50%	63%
Serious complications (%)	5 (50)	4 (11)	5 (19)	4(5.8%)

In our group of paediatric patients, cyclodiode treatment had a reasonable success rate and a few adverse effects. Cyclodiode may be used as an adjunctive therapy to external filtering surgery, for treatment of selected patients in whom intraocular surgery is not recommended because of a high risk of surgical complications or, as shown by our results, as a useful method for managing paediatric glaucoma. Further studies with long-term follow-up periods are required for all laser-assisted cycloablative techniques before any definite conclusions are drawn as to the preference of any of these methods for managing paediatric glaucoma.

*Autrata R., Lokaj M., Řehůřek J.*

#### TRANSSKLERÁLNÍ CYKLOFOTOKOAGULACE DIODOVÝM LASEREM U DĚTÍ S REFRAKTERNÍM GLAUKOMEM. DLOUHODOBÉ VÝSLEDKY

#### S o u h r n

Cílem studie bylo zhodnocení účinnosti cyklofotokoagulace diodovým laserem u dětských pacientů s refrakterním glaukomem a zjištění komplikací spojených s touto metodou. Soubor tvoří 69 očí u 53 dětí s dekompenzovaným refrakterním glaukomem, které byly ošetřeny cyklofotokoagulací. Průměrný věk pacientů byl 6.1 roku (rozsah, 0.9 až 15 roků). Nitrooční tlak (NOT), zraková ostrost a komplikace byly hlavními hodnocenými parametry. Průměrná doba sledování byla 4.5 roku (rozsah, 1.7 až 8.5 roku). Nejčastěji se vyskytovaly tyto typy glaukomu: afakický glaukom, dysgeneze předního segmentu, na klasickou léčbu nereagující vrozený glaukom, aniridie, glaukom u juvenilní chronické artritidy a Sturge-Weberova syndromu. 52% očí bylo afakických, a 78% očí prodělalo minimálně jednu předchozí operaci pro glaukom. V celém souboru bylo provedeno průměrně 2.1 cyklofotokoagulace na 1 oko (rozsah, 1 až 6 procedur). Průměrná předoperační hodnota nitroočního tlaku (NOT) byla 34 mmHg a na závěr studie byla průměrný pooperační NOT 20.8 mmHg ( $P < 0.05$ ). Po opakovaných procedurách (průměrný interval mezi dvěma zákroky byl 7.1 měsíce), mělo za 1 rok 79% očí NOT menší než 21 mmHg a za 2 roky to bylo 63% očí. Z pozdních vážných komplikací byla zaznamenána ablace cévnatky u 4 očí a amoce sítnice u 2 očí, které měly následně snížení zrakové ostrosti. Závěrem lze hodnotit cyklofotokoagulaci diodovým laserem jako užitečnou metodu pro léčbu refrakterního dětského glaukomu, kde selhávají klasické léčebné metody. Opakovaná cyklofotokoagulace může efektivně snížit nitrooční tlak při relativně nízkém riziku závažných komplikací.

#### REFERENCES

1. Wagle NS, Freedman SF, Buckley EG. Long-term outcome of cyclocryotherapy for refractory pediatric glaucoma. *Ophthalmology* 1998; 105: 1921–1926.
2. Gross RL, Feldman RM, Spaeth GL. Surgical therapy of chronic glaucoma in aphakia and pseudophakia. *Ophthalmology* 1988; 95: 1195–1201.
3. Suzuki Y, Araie M, Yumita A, Yamamoto T. Transscleral Nd: YAG laser cyclophotocoagulation versus cyclocryotherapy. *Graefes Arch Clin Exp Ophthalmol* 1991; 229: 33–36.
4. Bloom PA, Tsai JC, Sharma K. „Cyclodiode.“ Trans-scleral diode laser cyclophotocoagulation in the treatment of advanced refractory glaucoma. *Ophthalmology* 1997; 104: 1508–1519.
5. Kirwan JF, Shah P, Khaw PT. Diode laser cyclophotocoagulation role in the management of refractory pediatric glaucomas. *Ophthalmology* 2002; 109: 316–323.
6. Bock CJ, Freedman SF, Buckley EG, Shields MB. Transscleral diode laser cyclophotocoagulation for refractory pediatric glaucomas. *J Pediatr Ophthalmol Strabismus* 1997; 34: 235–239.

7. *Kosoko O, Gaasterland DE, Pollack IP, Enger CL.* Long-term outcome of initial ciliary ablation with contact diode laser transscleral cyclophotocoagulation for severe glaucoma. The Diode Laser Ciliary Ablation Study Group. *Ophthalmology* 1996; 103: 1294–1302.
8. *Azuara-Blanco A, Wilson RP, Spaeth GL.* Filtration procedures supplemented with mitomycin C in the management of childhood glaucoma. *Br J Ophthalmol* 1999; 83: 151–156.
9. *Beck AD, Wilson WR, Lynch MG.* Trabeculectomy with adjunctive mitomycin C in pediatric glaucoma. *Am J Ophthalmol* 1998; 126: 648–657.
10. *Molteno AC, Ancker E, Van Biljon G.* Surgical technique for advanced juvenile glaucoma. *Arch Ophthalmol* 1984; 102: 51–57.
11. *Munoz M, Tomey KF, Traverso C.* Clinical experience with the Molteno implant in advanced infantile glaucoma. *J Pediatr Ophthalmol Strabismus* 1991; 28: 68–72.
12. *Hill RA, Heuer DK, Baerveldt G.* Molteno implantation for glaucoma in young patients. *Ophthalmology* 1991; 98: 1042–1046.
13. *Netland PA, Walton DS.* Glaucoma drainage implants in pediatric patients. *Ophthalmic Surg Lasers* 1993; 24: 723–729.
14. *Coleman AL, Hill R, Wilson MR.* Initial clinical experience with the Ahmed Glaucoma Valve implant. *Am J Ophthalmol* 1995; 120: 23–31.
15. *Cunliffe IA, Molteno AC.* Long-term follow-up of Molteno drains used in the treatment of glaucoma presenting in childhood. *Eye* 1998; 12: 379–385.
16. *Noureddin BN, Wilson-Holt N, Lavin M.* Advanced uncontrolled glaucoma. Nd:YAG cyclophotocoagulation or tube surgery. *Ophthalmology* 1992; 99: 430–436.
17. *Eid TE, Katz LJ, Spaeth GL, Augsburger JJ.* Long-term effects of tube-shunt procedures on management of refractory childhood glaucoma. *Ophthalmology* 1997; 104: 1011–1016.
18. *Mandal AK, Walton DS, John T, Jayagandan A.* Mitomycin C-augmented trabeculectomy in refractory congenital glaucoma. *Ophthalmology* 1997; 104: 996–1001.
19. *Waheed S, Ritterband DC, Greenfield DS.* Bleb-related ocular infection in children after trabeculectomy with mitomycin C. *Ophthalmology* 1997; 104: 2117–2120.
20. *Phelan MJ, Higginbotham EJ.* Contact transscleral Nd:YAG laser cyclophotocoagulation for the treatment of refractory pediatric glaucoma. *Ophthalmic Surg Lasers* 1995; 26: 401–403.
21. *Youn J, Cox TA, Herndon LW.* A clinical comparison of transscleral cyclophoto-coagulation with neodymium:YAG and semiconductor diode lasers. *Am J Ophthalmol* 1998; 126: 640–647.
22. *Lam S, Tessler HH, Lam BL, Wilensky JT.* High incidence of sympathetic ophthalmia after contact and noncontact neodymium:YAG cyclotherapy. *Ophthalmology* 1992; 99: 1818–1822.
23. *Schuman JS, Bellows AR, Shingleton BJ.* Contact transscleral Nd:YAG laser cyclophotocoagulation. Midterm results. *Ophthalmology* 1992; 99: 1089–1094.
24. *Chen J, Cohn RA, Lin SC, Cortes AE, Alvarado JA.* Endoscopic photocoagulation of the ciliary body for treatment of refractory glaucomas. *Am J Ophthalmol* 1997; 124: 787–96.
25. *Mora JS, Iwach AG, Gaffney MM, Wong PC, Nguyen N, Ma AS.* Endoscopic diode laser cyclophotocoagulation with a limbal approach. *Ophthalmic Surg Lasers* 1997; 28: 118–23.
26. *Gayton JL.* Traumatic aniridia during endoscopic laser cycloablation. *J Cataract Refract Surg* 1998; 24: 134–5.
27. *DE Neely, DA Plager.* Endocyclophotocoagulation for management of difficult pediatric glaucomas. *J AAPOS* 2001; 5: 221–9.
28. *Fiore PM, Melamed S, Krug JH Jr.* Focal scleral thinning after transscleral Nd:YAG cyclotherapy. *Ophthalmic Surg* 1989; 20: 215–6.
29. *Edward DP, Brown SV, Higginbotham E, Jennings T, Tessler HH, Tso MO.* Sympathetic ophthalmia following neodymium:YAG cyclotherapy. *Ophthalmic Surg* 1989; 20: 544–6.

