

## **VISUAL OUTCOME AFTER CONGENITAL CATARACT SURGERY. LONG-TERM CLINICAL RESULTS**

ONDRÁČEK O., LOKAJ M.,

Department of Paediatric Ophthalmology, Paediatric Teaching Hospital, Faculty of Medicine,  
Masaryk University, Brno

### **A b s t r a c t**

The results of congenital cataract extraction were evaluated in 108 patients (163 eyes) who underwent cataract surgery at the Department of Paediatric Ophthalmology between 1985 and 1998. The outcome was assessed in terms of postoperative visual acuity and binocular vision. Fifty-one percent of the patients with bilateral aphakia and 47% with bilateral intraocular lens (IOL) implantation had a Snellen visual acuity of 0.5 or higher on the last visit. Similar values were achieved in 36% and 61% of the patients with unilateral aphakia and IOL implantation, respectively. In the patients who wore contact lenses after surgery, 29 % of those with bilateral cataract and 18 % of those with unilateral cataract attained fusion or stereopsis. Eleven of the 17 patients with unilateral cataract who had primary IOL implantation by 6 months of age achieved stereopsis. We conclude that surgery and optical correction should be performed at a very early age, i.e., in the sensitive period of binocular visual development, especially if dense opacities are present. With late surgery, good outcomes are achieved in the eyes in which opacity is only partial or is low in density. The importance of consistent visual rehabilitation and occlusion therapy of the involved eye for the treatment of amblyopia is emphasised.

### **Key words**

Amblyopia, Aphakia, Congenital cataract, Stereopsis

### **INTRODUCTION**

Infantile cataract not only blurs the retinal image but also disrupts the development of visual pathways. Although cataract is one of the best curable causes of visual impairment during infancy, it is rather difficult to obtain a good visual function following congenital cataract surgery. A good postoperative visual function requires the proper selection and performance of a surgical method, early and proper correction of refractive errors, as well as persistent visual rehabilitation. With a contribution of new surgical techniques, intraocular lens designs and materials, cataract extraction with correction of aphakia in children continues to evolve. The purpose of this report is to evaluate the results of cataract extraction and postoperative visual function in a series of patients who received either contact lenses or posterior chamber intraocular lens (IOL) implantation.

## MATERIALS AND METHODS

### PATIENTS

A total of 108 children (163 eyes), 61 boys and 47 girls, with cataracts were operated on and rehabilitated at the Department of Paediatric Ophthalmology, Paediatric Teaching Hospital, Faculty of Medicine, Masaryk University in Brno between 1985 and 1998. Bilateral cataract surgery was performed in 55 and unilateral in 53 patients. In 47 eyes, surgery involved the implantation of intraocular lenses; of these, 35 were fixed intracapsularly and 12 were placed in the ciliary sulcus. In relation to uni- or bilateral cataracts, IOLs were implanted bilaterally in 10 children (20 eyes) and unilaterally in 27 children (27 eyes). A total of 63 eyes (in 50 children) postoperatively received soft contact lenses (CL) for correction of aphakia, the rest were corrected by a combination of contact lenses and spectacles.

The mean age ( $\pm$  SD) at the time of surgery was  $23.3 \pm 31.9$  months (range 1 to 76 months). The mean follow-up period was  $73.6 \pm 56.4$  months (range, 36 to 172 months). The mean age at which the last visual acuity measurement was carried out was  $8.7 \pm 4.6$  and  $7.4 \pm 3.5$  years for the bilateral and unilateral cataract children, respectively.

### METHODS

When visual acuity assessment was possible, visual function and the prognosis of infantile cataract were evaluated. All patients were examined for systemic diseases and dysmorphic features by a paediatrician. A routine ocular examination was then performed, if possible, including an assessment of visual acuity by preferential looking, pupillary responses, ocular motilities, biomicroscopy and funduscopy and, in indicated cases, B-scan ultrasonography. Intraocular lens (IOL) implantation was performed in 47 eyes after a routine, planned extracapsular extraction. IOL power calculations were done using keratometry and ultrasonic biometry.

Cataract surgery involved a clear corneal or sclerocorneal incision, viscoelastic agent in the anterior chamber, manual anterior capsulorhexis, irrigation and aspiration of lens material, posterior capsulorhexis in all eyes and anterior vitrectomy in 60% of the eyes. Polymethyl methacrylate, single-piece IOLs or foldable acrylic IOL implants, with powers calculated by the Sanders-Retzlaff-Kraff formula, were used. Undercorrection was preferred by choosing intraocular lenses with powers ranging between 21 and 28 D (mean  $\pm$  SD,  $24 \pm 3.95$  D). Twelve children with unilateral congenital cataract and without other ocular or systemic abnormalities had in-the-bag implantation of an acrylic IOL within the first 6 months of birth. The patients were prescribed dexamethazone and tobramycin or ofloxacin eyedrops to be taken for 1 month, and mydriatics-like tropicamide or homatropin eyedrops for 2 or to 3 weeks after the surgery. When posterior capsular opacification occurred after surgery, it was managed by yttrium-aluminum-garnet (YAG) laser capsulotomy in children older than 5 years of age. Children too young for YAG laser capsulotomy procedures were treated by secondary capsulectomy and aspiration of Elschnig pearls under general anaesthesia. All patients received visual rehabilitation on the third day after surgery; preferential or Snellen visual acuities were assessed on each following visit.

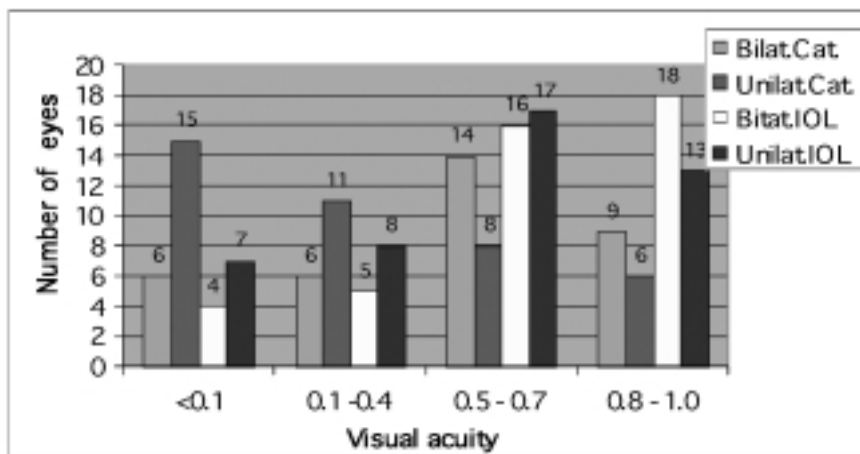
The postoperative therapy of aphakic patients without IOL involved the use of soft contact lenses applied by the parents trained before surgery. Additional correction by spectacles was prescribed to correct a residual refractive error in individual cases. In children fitted with trial lenses, the proper base curve and size were assessed by checking fluorescein patterns and lens motility. Lens power was determined by careful retinoscopy or hand-held automatic refractokeratometry. In infants, contact lenses were adjusted for near vision and, in school children, lenses designed for distant vision were preferred. The eye patching tailored to each patient was started immediately after surgery to manage amblyopia. The quality of binocular vision—fusion, stereopsis and orthoptic status, tolerance of contact lenses and compliance with occlusion treatment were also recorded on each examination. The follow-up period ranged from 36 to 172 months (mean  $\pm$  SD,  $73.6 \pm 56.4$  months).

Compliance was regarded as „good“ when the patient fulfilled more than 80% of the criteria for visual rehabilitation, as determined by the attending physician.

The results were statistically analysed using Student's *t* test, and *P* values less than 0.05 were regarded as significant.

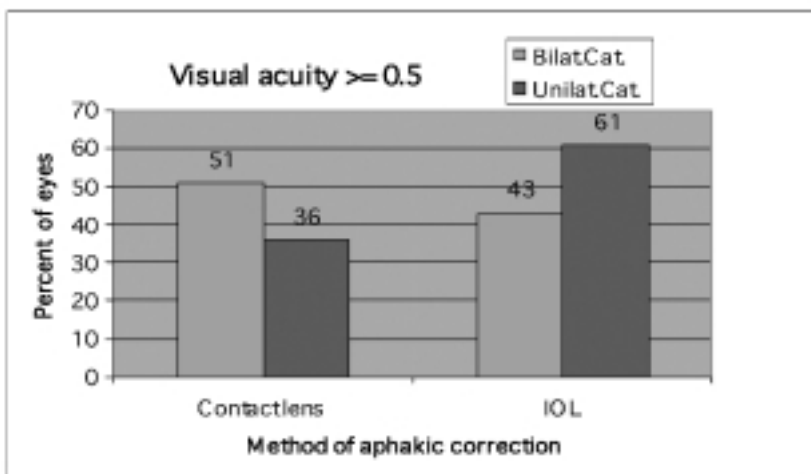
## RESULTS

Systemic disorders associated with cataract were diagnosed in 33 patients. Five patients had microphthalmia, three patients had an anterior type of persistent hyperplastic primary vitreous and two patients had optic nerve hypoplasia. The visual acuity results following surgery are presented in *Fig. 1*. In patients with bilateral cataract (55), a Snellen visual acuity of 0.5 or better was achieved in 51 % (20 of 38) of the eyes with CL and in 43% (8 of 20) of the eyes with IOL ( $P= 0.31$ ); in unilateral cataracts (53) it was 36 % (9 of 25) and 61% (16 of 27), respectively (*Fig. 2*). The difference between aphakic correction by contact lenses and that by IOLs in unilateral cataracts was statistically significant (36% versus 61%;  $P= 0.043$ ). When the postoperative visual acuity was related to patients' age at surgery for both the contact lens and IOL implant patients, better results were achieved by early surgery only in the patients with unilateral cataract. In the 55 patients with bilateral cataract, 28 of 60 eyes that were operated on before the children were 2 years of age and 23 of 44 eyes operated on before 6 months of age, only 47 % and 52 %, respectively, had a visual acuity  $\geq 0.5$ .



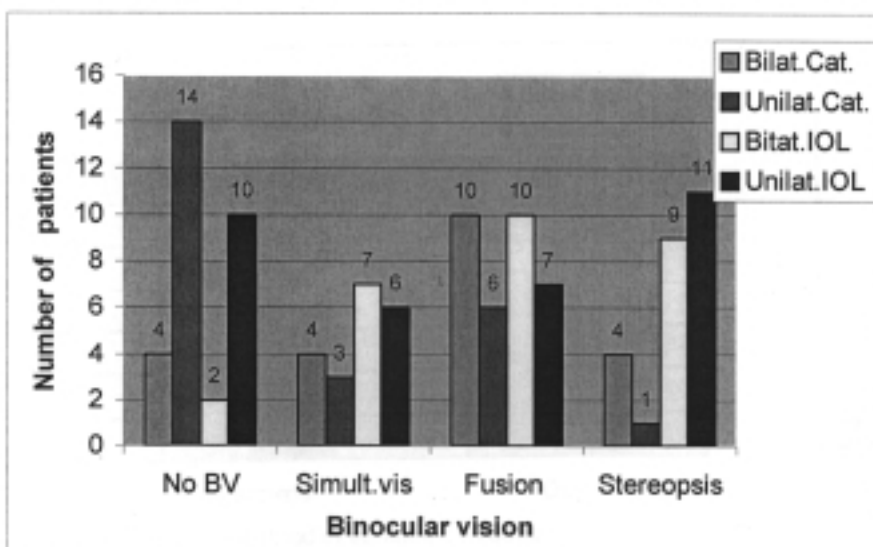
*Fig.1*

Visual acuity outcome. Bilat., bilateral; Unilat., unilateral, Cat., cataract; IOL, intraocular lens.



*Fig. 2*

Comparison of the visual acuity outcomes in relation to the method of correction (contact lens vs. intraocular lens). Only eyes with the value  $\geq 0.5$  are included. Bilat. Cat., bilateral cataract; Unilat. Cat., unilateral cataract; IOL, intraocular lens.



*Fig. 3*

Surgery outcomes assessed by the quality of binocular vision. Bilat., bilateral; Unilat., unilateral, Cat., cataract; IOL, intraocular lens; BV, binocular vision.

The results of binocular vision in the total of 108 patients are shown in *Fig. 3*. There was no binocular vision in 30 (27%) patients, 20 (19%) had simultaneous vision, 33 (31%) had fusion and 25 (23%) children attained stereopsis. Seven patients with unilateral aphakia and 14 patients with bilateral aphakia who received contact lenses achieved both fusion and stereopsis. Four patients with bilateral and one patient with unilateral cataract who wore contact lenses after surgery attained stereopsis. Of the 17 patients with unilateral cataract who received IOLs before 6 months of age, 11 achieved stereopsis.

Compliance with postoperative visual rehabilitation was assessed as „good“ in 78 patients. From the 53 patients with bilateral cataract only seven could not tolerate contact lenses and had to switch to spectacle use. From the 55 patients with unilateral cataract, 21 adjusted well to contact lenses and 34 had to start wearing spectacles.

The occurrence of strabismus after cataract surgery was higher in the patients with unilateral than with bilateral cataract (52% vs. 44%). Forty-eight patients were orthophoric, 21 had exotropia, 34 had esotropia and five were diagnosed as having a vertical deviation. Esotropia was more common in bilateral cataracts. Eventually, 42 children had to undergo surgery for strabismus. Preoperative nystagmus was present in 29 patients and, in 22, it persisted even after cataract surgery. Nystagmus was more common in bilateral cataracts; 19 patients with bilateral aphakia and two patients with bilateral IOLs had persistent nystagmus.

Posterior capsular opacification was frequent in the eyes of children younger than 5 years in whom the posterior capsule remained without capsulectomy and anterior vitrectomy. Nine eyes were treated by YAG laser posterior capsulotomy and 16 underwent secondary operative capsulectomy and the aspiration of proliferated epithelial cells, i.e., Elschnig pearls. A secondary glaucoma was diagnosed in seven eyes (4.3%). In five eyes, long-term intraocular pressure control was maintained with antiglaucoma medication. Five eyes (3.8%) showed pupillary deviation. No retinal detachment was observed in this study.

## DISCUSSION

Aphakic optical correction has traditionally been achieved by spectacles and/or contact lenses. Spectacles are associated with optical aberrations and are often less favoured for cosmetic reasons. The wear of contact lenses requires good cooperation of both the patient and the parents who, in addition, may be involved in postoperative amblyopia therapy. Epikeratophakia may offer another form of optical correction for an older aphakic child but, at present, it is not widely used. Although IOL implantation avoids many of these disadvantages, it may still be associated with some complications (1–14). The implantation of a posterior-chamber IOL is, according to long-term postoperative functional results, a suitable alternative of aphakic correction in children (6).

The visual outcome of surgery for paediatric cataract is dependent on many factors, including age at which the cataract develops, cataract density, age at which optical correction is initiated and a degree to which the fellow eye is occluded (1,2,5). Visual prognosis is generally better for bilateral cataracts (5,15,16).

Primary or secondary posterior chamber IOL implantation was found to better contribute to a binocular vision outcome of surgery for congenital cataract than other types of aphakic corrections. In childhood cataract, amblyopia plays a major role in the visual outcome of surgery. The timing of surgery, i.e., early cataract removal, has been more important than the method of aphakic optical correction, especially in unilateral congenital cataract (5).

In our study, the visual acuity outcomes after surgery for both unilateral and bilateral cataracts were similar to other studies (17–20). A considerable proportion of our patients with light partial lenticular opacities achieved a visual acuity of 0.5 or higher. Most of the intraocular lens implantations were carried out in children aged 12 months or older.

Several reports state that the earlier the age at surgery the better the visual prognosis (21,22). A recent report by *Elston and Timms* suggests that the first 6 weeks of life represent a sensitive period for binocular development (23). In the early period of life, visual prognosis is related to the degree of visual deprivation caused by cataract density. Seventeen of our patients with unilateral congenital cataract who underwent surgery before 1 year of age achieved a favourable visual outcome.

In our study, seven patients with unilateral aphakia corrected by contact lenses following surgery and 14 patients with bilateral aphakia achieved fusion and stereopsis. Four patients with bilateral and one patient with unilateral cataract, all with contact lenses, attained stereopsis. Of the 17 patients with unilateral cataract who had primary intraocular lens implantation by 6 months of age, 11 attained stereopsis. This implies that the one-stage correction of an aphakic refractive error by IOL may result in a good visual outcome when it is associated with consistent occlusion therapy. This finding is in agreement with the results reported elsewhere (24).

We found strabismus to be more common in both unilateral and bilateral cataracts than it was reported in other studies (25). The patients with strabismus in whom we failed to achieve good visual results probably developed amblyopia despite successful surgery and rehabilitation efforts.

Another factor that affects visual outcome is nystagmus. Nystagmus was observed in our patients with bilateral cataract in whom treatment was delayed or who showed poor compliance with postoperative visual rehabilitation. We think that early surgery associated with immediate optical correction can eliminate this problem.

We did not find any major postoperative complications in our patients. The incidence of glaucoma was low, similar to that described by *Chrousos* (26). The surgical and medication therapy used in our patients controlled the intraocular pressure effectively.

We agree with many other authors that, in children with congenital cataract, very early surgery and optical correction in the sensitive period of binocular visual development should be carried out. This is true especially in the presence of dense opacities which are likely to be associated with severe deprivation amblyopia. We conclude that early cataract extraction combined with posterior capsulectomy, anterior vitrectomy and foldable intraocular lens implantation is a safe and effective method that results in excellent postoperative visual outcomes in eyes with not only bilateral but also unilateral congenital cataract.

*Ondráček O., Lokaj M.*

#### VÝSLEDKY ZRAKOVÝCH FUNKCÍ PO OPERACI VROZENÉ KATARAKTY. DLOUHODOBÁ KLINICKÁ STUDIE

#### S o u h r n

Autoři hodnotí výsledky operací vrozené katarakty zejména výslednou pooperační zrakovou ostrost a binokulární vidění u 108 dětí, u kterých byla provedena operace v letech 1985–1998. 51% dětí s bilaterální afakií a 47% dětí s bilaterální pseudofakií mělo zrakovou ostrost 6/12 a lepší při poslední kontrole. Zrakovou ostrost 6/12 a lepší mělo 36% dětí s jednostrannou afakií a 61% dětí s jednostrannou pseudofakií. 29% dětí s oboustrannou afakií a 18 % dětí s jednostrannou afakií korigovaných kontaktní čočkou získalo fúzi nebo stereopsi při testování binokulárního vidění. Jedenáct ze 17 dětí s jednostrannou kataraktou, u kterých byla provedena extrakce s primární implantací umělé nitrooční čočky v prvních 6 měsících věku života, mělo výsledné binokulární funkce kvality stereopse. Výsledky studie hovoří pro velmi časnou extrakci katarakty a optickou korekci afakie během senzitivní periody vývoje binokulárního vidění, zvláště v případech denzních zákalů. Dobré pooperační výsledky zrakových funkcí lze dosáhnout pozdější operací pouze v případech jemných nebo parciálních zákalů. Velmi zásadní je důsledná pooperační zraková rehabilitace a léčba amblyopie s okluzí dominantního oka.

#### REFERENCES

1. *Markham RHC, Bloom PA, Chandna A, Newcomb EH.* Results of intraocular lens implantation paediatric aphakia. *Eye* 1991; 6: 493–498.
2. *Brady KM, Atkinson S, Kilty L, Hiles DA.* Cataract surgery and intraocular lens implantation in children. *Am J Ophthalmol* 1995; 120: 1–9.
3. *Rosenbaum AL, Masket S.* Intraocular lens implantation in children. *Am J Ophthalmol* 1995; 120:105–107.
4. *Sinsky RM, Stoppel JO, Amin P.* Long term results of intraocular lens implantation in pediatric patients. *J Cataract Refract Surg* 1993; 19: 405–408.
5. *Autrata R, Řehůřek J, Unčovská J et al.* Binokulární funkce po operaci katarakty u dětí [Binocular vision after cataract surgery in children]. *Cesk a Slov Oftalm.* 2001; 57: 92–98.
6. *Autrata R, Řehůřek J.* Implantace nitroočních čoček u dětí [Intraocular lens implantation in children]. *Cesk a Slov Oftalm.* 2000, 56: 303–310.
7. *Vasavada A, Chauhan H.* Intraocular lens implantation in infants with congenital cataracts. *J Cataract Refract Surg* 1994; 20: 592–598.

8. Kora Y, Shimizu K, Inatomi M, Fukado Y, Ozawa T. Eye growth after cataract extraction and intraocular lens implantation in children. *Ophthalmol Surg* 1993; 24: 467–475.
9. Sinskey R, Amin P, Lingua R. Cataract extraction and intraocular lens implantation in an infant with a monocular congenital cataract. *J Cataract Refract Surg* 1994; 20: 647–651.
10. Kora Y, Shimizu K, Inatomi M, Fukado Y, Marumori M, Yaguchi S. Long term study of children with implanted intraocular lenses. *J Cataract Refract Surg* 1992; 18: 485–488.
11. Lorenz B, Worle J. Visual results in congenital cataract with the use of contact lens. *Graefes Arch Ophthalmol* 1991; 229: 123–132.
12. Moore BD. Pediatric aphakic contact lens wear: Rates of successful wear. *J Pediatr Ophthalmol Strabismus*. 1993; 30: 253–258.
13. Amos CF, Lambert SR, Ward MA. Rigid gas permeable contact lens correction of aphakia following congenital cataract removal during infancy. *J Pediatr Ophthalmol Strabismus* 1992; 29: 243–245.
14. Parks MM, Johnson DA, Reed GW. Long term visual results and complications in children with aphakia. *Ophthalmol* 1993; 100: 827–841.
15. Bradford GM, Keech RV, Scott WE. Factors affecting visual outcome after surgery for bilateral congenital cataracts. *Am J Ophthalmol* 1994; 117: 58–64.
16. Kugelberg U. Visual acuity following treatment of bilateral congenital cataracts. *Documenta Ophthalmol* 1992; 82: 211–215.
17. Birch EE, Stager DR. Prevalence of good visual acuity following surgery for congenital unilateral cataract. *Arch Ophthalmol* 1988; 106: 40–43.
18. Cheng KP, Hiles DA, Biglan AW, Pettapiece MC. Visual results after early surgical treatment of unilateral congenital cataracts. *Ophthalmol* 1991; 98: 903–910.
19. Catalano A, Simon JW, Jenkins PL, Kandel GL. Preferential looking as a guide for amblyopia therapy in monocular infantile cataracts. *J Pediatr Ophthalmol Strabismus* 1987; 24: 56–63.
20. Lewis TL, Maurer D, Brent HP. Development of grating acuity in children treated for unilateral or bilateral congenital cataract. *Invest. Ophthalmol Vis Sci* 1995; 36: 2080–2095.
21. Birch EE, Swanson WH, Stager DR, Woody M, Everett M. Outcome after very early treatment of dense congenital unilateral cataract. *Invest Ophthalmol Vis Sci* 1993; 34: 3687–3699.
22. Birch EE, Stager DR, Wright WW. Grating acuity development after early surgery for congenital unilateral cataract. *Arch Ophthalmol* 1986; 104: 1783–1787.
23. Elston JS, Timms C. Clinical evidence for the onset of the sensitive period in infancy. *Br J Ophthalmol* 1992; 76: 327–328.
24. Tytla ME, Lewis TL, Brent HP. Stereopsis after congenital cataract. *Invest Ophthalmol Vis Sci* 1993; 34: 1767–1773.
25. Hiles DA, Sheridan SJ. Strabismus associated with infantile cataracts. *Int Ophthalmol Clin* 1977; 17: 193–202.
26. Chrousos GA, Parks MM, O'Neil JFI. Incidence of chronic glaucoma, retinal detachment and secondary membrane surgery in pediatric aphakic patients. *Ophthalmol* 1984; 91: 1238–1241.