

INVESTIGATION OF THE MICROSCOPIC STRUCTURE OF RABBIT COMPACT BONE TISSUE

MARTINIAKOVÁ M.¹, VONDRÁKOVÁ M.¹, FABIŠ M.²

¹Department of Zoology and Anthropology, Constantine the Philosopher University, Nitra,
Slovak Republic

²Department of Animal Physiology, Slovak Agricultural University, Nitra, Slovak Republic

Abstract

The detailed microscopic structure (qualitative and quantitative characteristics) of 10 rabbit thigh bones was investigated. Femur diaphysis from each individual was sectioned at its smallest breadth. The final thickness of the sections was approximately 100 microns. The average areas, perimeters, minimal and maximal diameters of 200 vascular canals of primary osteons, 40 haversian canals of secondary osteons, and 40 secondary osteons were measured on digital images. According to our study the investigated bone tissue is in general composed of primary longitudinal bone tissue. Some areas of dense haversian remodelling occur mainly in the posteromedial and posterolateral sides. Haversian canals of the secondary osteons (like the vascular canals of the primary osteons) are short.

Key words

Microstructure, Femur diaphysis, Rabbit, Histomorphometry

INTRODUCTION

The long bone diaphysis of juvenile and adult mammals is composed of compact bone tissue which builds the wall of the shaft. The important elements of its structural organisation are primary and secondary (haversian) osteons. Histological research of the compact bone tissue microstructure can be carried out in two ways: qualitatively and quantitatively. Qualitative characteristics describe the type of the bone tissue from the medullary cavity towards the periosteal surface. The qualitative approach counts and measures (e.g., area, perimeter, minimal and maximal diameter of osteons or haversian canals).

The aim of our work was to analyse the microstructure of rabbit femur diaphysis. Microscopic structure of the compact bone was evaluated from the point of view of qualitative and quantitative characteristics.

MATERIAL AND METHODS

Our research focused on 10 femurs of five 5–7 months old female rabbits of New Zealand White albino breed. Each of the bones was sectioned at the smallest breadth (SB) of its diaphysis where

the compact bone is thick and provides a large area for the study of the bone tissue microstructure. In total, 10 transversal sections of the femur diaphysis were cut. The obtained segments were macerated and degreased. Later the samples were glued (Eukitt) onto a matted slide and cut using a diamond disk. Afterwards the bone fragments were ground by a laboratory grinder (Montasupal). The final thickness of the sections was approximately 100 microns. For the examination, an optical microscope Jenaval (Carl Zeiss Jena) with a digital CCD camera (Mintrow) at a magnification of 200x were used. Photographic documentation of the slides was made using computer programs Ati Player 5.2 (Ati Technol. Inc.) and Adobe Photoshop 5.0. Altogether 40 digital images were obtained. The qualitative characteristics were determined according to the generally known and internationally accepted classifications by *Enlow and Brown* (1956), *Rämsch and Zerndt* (1963), and *Gladuhsew* (1964). The quantitative characteristics were found out using the computer software Scion Image (Scion Corporation). The following parameters were measured: area, perimeter, minimal and maximal diameters of 200 primary vascular canals of primary osteons, of 40 haversian canals of secondary osteons, and of 40 secondary osteons. The basic statistical characteristics of the position and variability for each of the particular parameters were counted using the Excel 2000 software package.

RESULTS

The femurs of all the analysed animals had the following microstructure in common. The arrangement and distribution of different bone tissue types is given from the medullary cavity towards the periosteal surface:

- the inner layer surrounding the medullary cavity is formed by a zone of lamellar bone tissue which contains longitudinally arranged primary vascular canals. The areas between the neighbouring primary osteons are often very large and thus give an avascular appearance to the lamellar tissue mainly in the anteromedial sides.

- then there follows the layer of irregular haversian bone tissue. This is characterised by scattered, isolated and relatively scarce haversian systems. Some areas of dense haversian remodelling occur mainly in the posteromedial and posterolateral sides (*Fig. 1*).

- further towards the periosteal surface, the haversian tissue is gradually replaced by primary vascular radial (*Fig. 2*), but predominantly longitudinal bone tissue.

- finally, primary vascular longitudinal bone tissue appears on the dorsal parts of all the investigated bones. The vascular canals run in a direction essentially parallel to the long axis of the bone (*Fig. 3*).

All in all, 200 primary vascular canals of primary osteons, 40 haversian canals of secondary osteons, and 40 secondary osteons were measured. The results are shown in *Table 1*.

DISCUSSION

The results given in *Table 1* showed that the mean diameter of primary vascular canal of primary osteon (counted as arithmetic mean of minimal and maximal diameter of 200 primary vascular canals of 200 primary osteons) is 12.49 μm .

Table 1

Basic statistical characteristics of osteons and haversian canals

Measured values	n	Parameters	x	s	v	m
Vascular canal of primary osteons	200	area (μm^2)	189.66	73.75	19.44	5.32
	200	perimeter (μm)	38.37	8.26	10.77	0.60
	200	max. diameter (μm)	18.52	5.14	13.87	0.37
	200	min. diameter (μm)	6.45	1.56	12.08	0.11
Haversian canal of secondary osteons	40	area (μm^2)	367.48	229.79	31.27	35.04
	40	perimeter (μm)	53.96	20.23	18.75	3.09
	40	max. diameter (μm)	26.31	12.09	22.98	1.84
	40	min. diameter (μm)	8.66	2.95	17.04	0.45
Secondary osteons	40	area (μm^2)	8339.98	3255.10	19.52	485.24
	40	perimeter (μm)	261.96	50.68	9.67	7.56
	40	max. diameter (μm)	129.05	29.74	11.52	4.43
	40	min. diameter (μm)	41.05	12.34	15.03	1.84

x – average, s – standard deviation, v – coefficient of variance, m – standard error of the mean

We can note that rabbit femur diaphysis of New Zealand White albino breed has relatively short primary vascular canals of the osteons. The mean diameter of 40 haversian canals of secondary osteons is 17.49 μm . The value is clearly higher than that according to *Muller and Demarez* (12.6 μm ; 1934). Using classification of haversian canals (2, 4) we can note that secondary osteons contain (similar to primary osteons) short vascular (haversian) canals, although the mean diameter of the haversian canals of secondary osteons is higher compared with the primary osteons. The mean diameter of 40 secondary osteons of the analysed rabbit femurs is 85.05 μm . In the available literature we failed to find a comparable value. The remaining parameters could not be compared because of their absence in the literature.

Our observations seem to provide the first evidence of the qualitative and quantitative characteristics of primary and secondary osteons identified in the

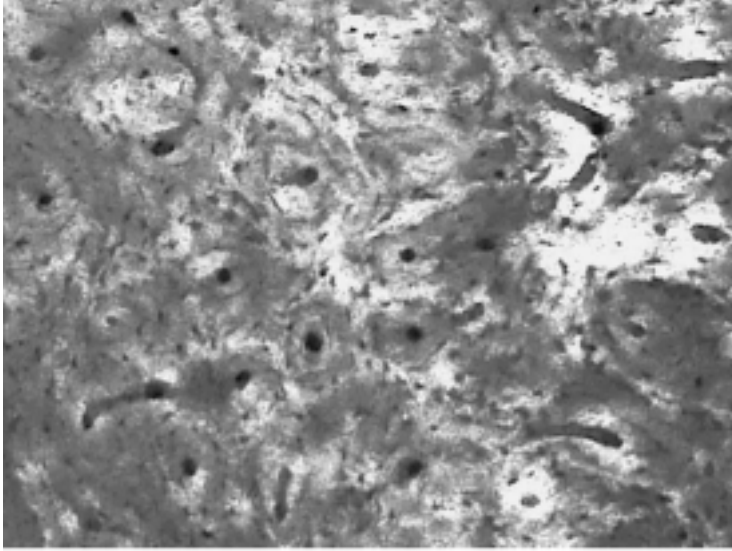


Fig. 1
Dense Haversian bone tissue (magnification 200x)




Fig. 2
Primary vascular radial bone tissue (magnification 200 x)




Fig. 3
Primary vascular longitudinal bone tissue (magnification 200x)

rabbit femur diaphysis of New Zealand White albino breed. The results could be applied in archaeozoology for the identification of species from bone fragments.

CONCLUSION

We investigated qualitative and quantitative characteristics of the rabbit femur diaphysis microstructure. Our results revealed that the investigated bone tissue is in general composed of primary longitudinal bone tissue. In posteromedial and posterolateral sides there are areas of dense haversian bone tissue. The secondary osteons like the primary osteons contain short vascular canals as documented in *Table 1*.

Acknowledgement

We thank Ing. Peter Chrenek, PhD. (Research Institute of Animal Production, Nitra) for providing the rabbit skeletal material, and RNDr. Ján Spišiak, CSc. (Institute of Geology, Slovak Acad. Sci., Banská Bystrica) for assistance with thin section grinding. We acknowledge the kind assistance of RNDr. Roman Kuna, PhD. and RNDr. Radoslav Omelka (Department of Botany and Genetics, Constantine the Philosopher University, Nitra) with photographic documentation.

This study was supported by the UKF grant: GAM 21/2002/FPV

VÝSKUM MIKROSKOPICKEJ STAVBY KOMPAKTNÉHO KOSTNÉHO TKANIVA
KRÁLIKA DOMÁCEHO

S ú h r n

Skúmali sme kvalitatívne i kvantitatívne charakteristiky mikroštruktúry diafýz 10 femurov králika domáceho, plemena Novozélandský biely králik. Základné rezy boli robené naprieč diafýzou v mieste najmenej šírky stehnovej kosti. Konečná hrúbka výbrusov bola približne 100 mikrometrov. Merali sme nasledovné parametre: plochu, obvod, minimálny a maximálny priemer 200 cievných kanálikov primárnych osteónov, 40 Haversových kanálikov sekundárnych osteónov a 40 sekundárnych osteónov. Zistili sme, že mikroskopická stavba analyzovaného kostného tkaniva pozostáva zväčša z primárne cievnatého longitudinálneho kostného tkaniva. Pre posteromediálne a posterolaterálne oblasti je charakteristický výskyt hustého Haversového kostného tkaniva. Haversove kanáliky sekundárnych osteónov, podobne ako cieвне kanáliky primárnych osteónov, sú úzke, o čom svedčia namerané hodnoty uvádzané v tabuľke, resp. hodnoty od nich odvodené a charakterizované v texte.

REFERENCES

1. *Enlow DH, Brown SO.* A comparative histological study of fossil and recent bone tissues. Part I, *The Texas Journal of Science* 1956; 4: 405–412.
2. *Gladuhsew JM.* Problems of the histological investigation of the bone in forensic medicine. *Sudebno Med Exp* 1964; 7: 23–26.
3. *Muller M, Demarez R.* Le diagnostic différentiel de l'os de singe et de l'os humain [Differential diagnostics of monkey and human bones]. *Med Leg* 1934; 14: 498–560.
4. *Rämsch R, Zerndt B.* Vergleichende Untersuchungen der Haversschen Kanäle zwischen Menschen und Haustieren [Comparative studies of haversian canals in humans and domestic animals]. *Arch Kriminol* 1963; 131: 74–87.