

AUTOLOGOUS CHONDROCYTE TRANSPLANTATION FOR THE TREATMENT OF ARTICULAR DEFECTS OF THE KNEE

VIŠŇA P.¹, ADLER J.², PAŠA L.¹, KOČIŠ J.¹, CIŽMAŘ I.¹, HORKÝ D.³

¹ Department of Traumatology, Traumatological Hospital, Faculty of Medicine, Masaryk University, Brno

² Tissue Bank, Bohunice Teaching Hospital, Faculty of Medicine, Masaryk University, Brno

³ Department of Histology, Faculty of Medicine, Masaryk University, Brno

A b s t r a c t

Full-thickness cartilage defects are common and serious problems in today knee surgery. The limited ability of the cartilage to repair the injured surface is generally known. Clinical symptoms in cases with full thickness defects are severe and lead to premature development of osteoarthritis. Numerous techniques to treat chondral defects (abrasion, drilling, autografts, allografts and cell transplantation) have been developed. One of the new cartilage repair techniques is the autologous chondrocyte transplantation combined with tissue glue Tissucol (Baxter, Austria). This technique was developed in Traumatological Hospital Brno. The first patient was operated in 1998 and 25 patients underwent such procedure until December 2002. Group of 14 patients was prospectively evaluated after 1 year of follow-up. This technique provides stable short-term outcomes with high percentage of good to excellent results – 71 % of patients (according to the Lysholm knee score). Average Lysholm score in the studied group was 76.5 points 5 months after transplantation and 81.0 points 12 months after transplantation. Second-look arthroscopy in 4 patients certified good healing of defects. Cartilage surface was evaluated according to ICRS cartilage score with average value 8.0 points. Control biopsy documented formation of reparative tissue with hyaline-like cartilage and presence of typical chondrocytes and collagenous filaments.

Key words

Autologous chondrocyte transplantation, Chondrograft, Full-thickness chondral defect, Tissucol, Lysholm knee score

Abbreviations used

ICRS, International cartilage repair society; DNA, deoxyribonucleic acid; ACT, autologous chondrocyte transplantation

INTRODUCTION

The limited chondrocytes ability to repair the articular surface defect is generally known. The aim of different investigators was to find a method how to produce cartilage in the places of chondral and osteochondral defects. It was

demonstrated that chondrocytes and undifferentiated mesenchymal stem cells after placing to the defect survive and produce the cartilaginous matrix (1).

A lot of various ways of cells fixation to the defect exist. *Wakinati* (2) demonstrated new formation of hyaline-like cartilage in rabbits after filling the defect by allogeneous chondrocytes in collagenic gel. One of the most important studies on this field was published by *Brittberg* (1). The cartilage was harvested from non weight-bearing area of the knee joint at patients with diagnosed deep chondral defect on the femoral condyle or patella. Chondrocytes were cultivated in vitro for 14 to 21 days, later injected to the defect and covered by periosteal flap. In 14 patients from the number of 16 with documented condylar defect and in 2 patients from 7 with patellar defect good or excellent results were achieved after transplantation. The biopsy from the former defect's place demonstrated formation of new cartilage with hyaline-like structure in 2/3 of patients.

MATERIALS AND METHODS

This topic is intensively studied also at our hospital (3,4,5,6). We use the method of chondrocyte retrieval and in vitro cultivation similar to that one described by Brittberg and Peterson (1,7,8,9,10). The transplantation phase using periosteal flap is according to our opinion not optimal due to the fixation of periost with stitches to the cartilage, which is not always ideal in strengthness even waterproofness. For this reason modifications of above techniques are tested in many hospitals. The goal is to find a suitable three-dimensional carrier for chondrocyte culture.

After serial laboratory tests we decided to use the tissue fibrin glue Tissucol (Baxter, Austria) as a chondrocyte carrier. Very good cell viability and capability of cell migration and outgrow in Tissucol were documented.

Our tests on cadavers and pigs demonstrated good healing effects after chondrocyte transplantation. The histological examinations described hyaline-like cartilage.

Described technique is indicated for deep chondral defects type III.a. and III.b. according to Noyes – Stabler classification (11). Best results can be reached in isolated cartilage defects above 2 cm² on the weight-bearing area of femoral condyle. Age of patients should be under 50 years, but always is necessary to consider the biological status of knee joint and the degree of osteoarthritis development.

Our technique consists of following phases:

Arthroscopic diagnostic of defect.

Arthroscopic sampling of cartilage for in vitro cultivation.

Transport of samples to tissue bank.

Enzymatic isolation, in vitro cultivation of chondrocytes.

Graft formation (combination of fibrin glue with chondrocytes), quality control.

Transplantation (chondrograft agglutination into defect).

Suitable defect was diagnosed during arthroscopy, we have to assess the size of lesion and obtain cartilage samples for cultivation in amount of 300–500 mg (from margin of medial femoral condyle). Cartilage was transported in cold salt solution with antibiotics. Samples of cartilage were cleaned and cut into small pieces under laminar airflow hood conditions and digested enzymatically using trypsin and collagenase. Chondrocytes suspension was inoculated into flasks and cultured in incubator at 37°C in CO₂ atmosphere. Culture medium exchange was provided every 48 hours. Proliferation of chondrocytes was monitored using inverted microscopy. Successful primocultivation resulted in cell monolayer (Fig.1). Demanded number of cells (5–10 million of cells per ml) was obtained via several subcultivations.

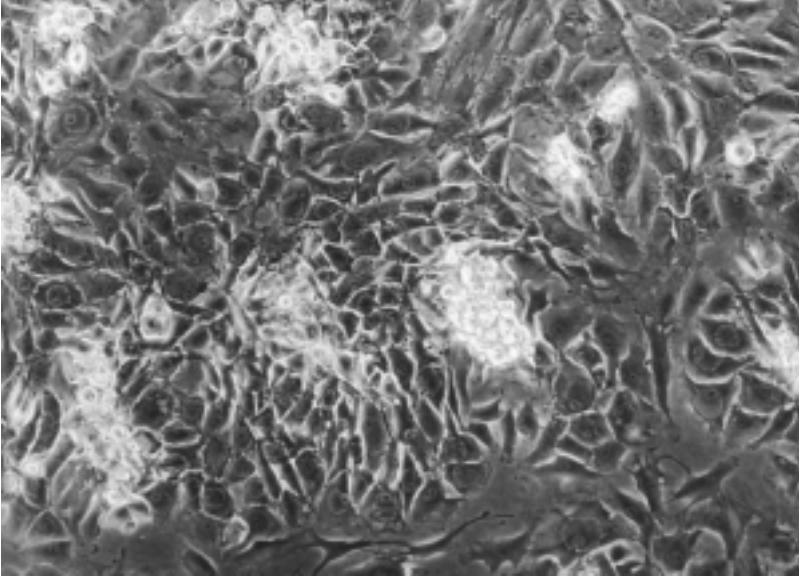


Fig. 1
Cellular primocultivation

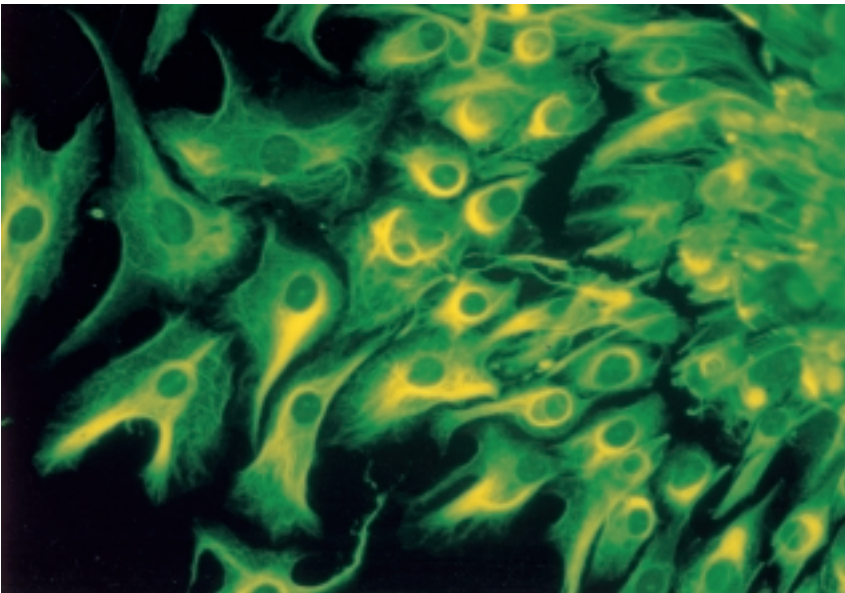


Fig. 2
Immuno-fluorescence microscopy – monoclonal antibodies against vimentin

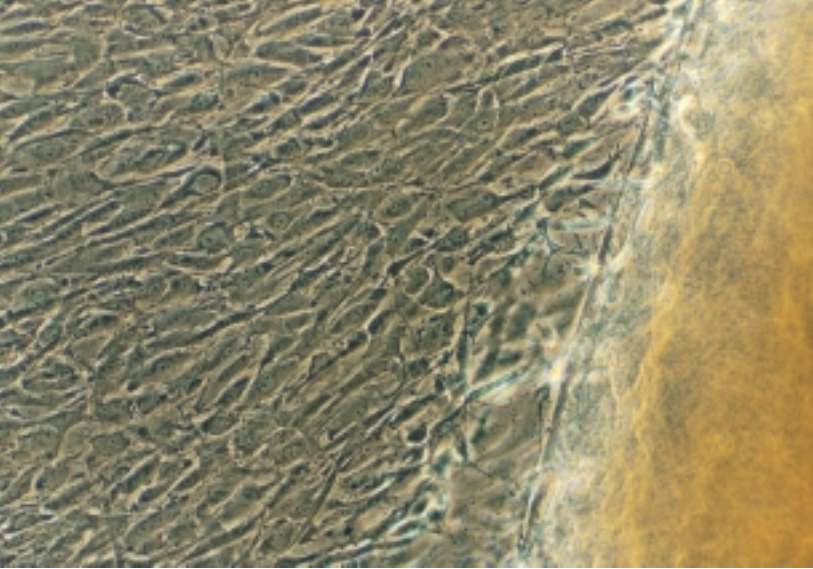


Fig. 3

Light microscopy – migration and outgrowth of chondrocytes from chondrograft

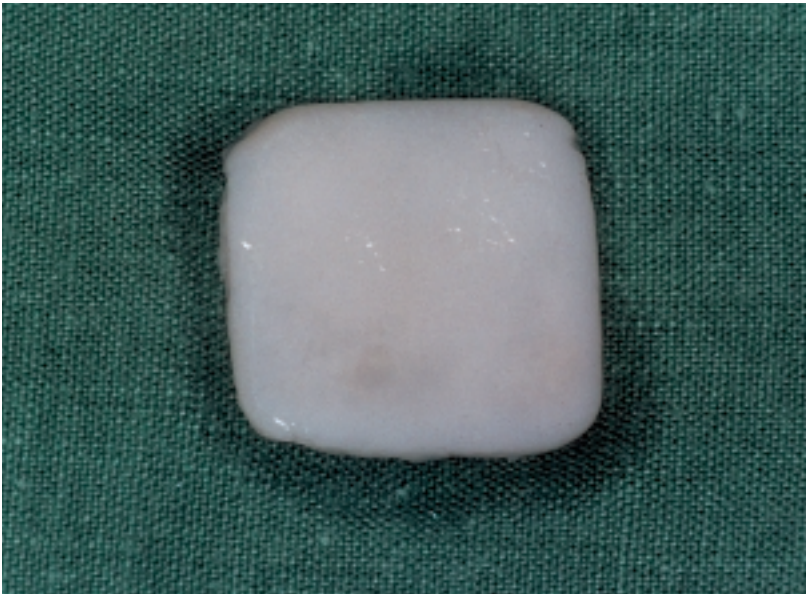

Fig. 4

Chondrograft before application

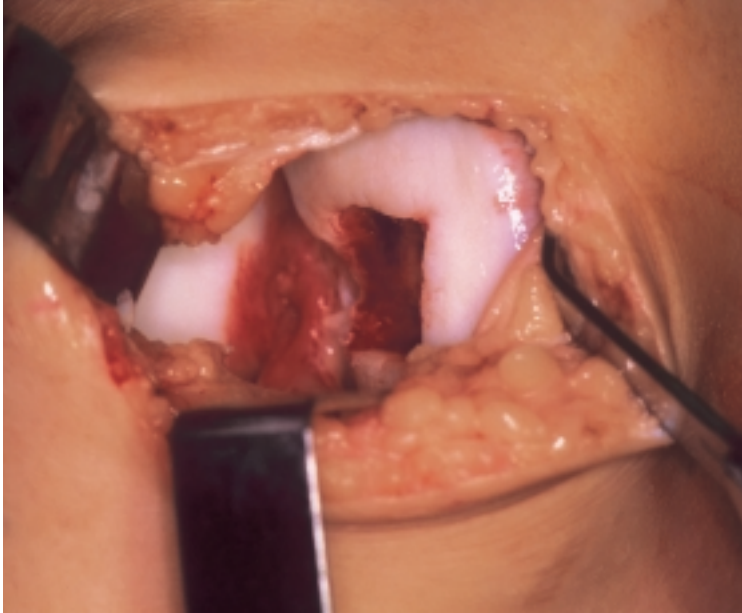


Fig. 5
Peroperative picture of defect

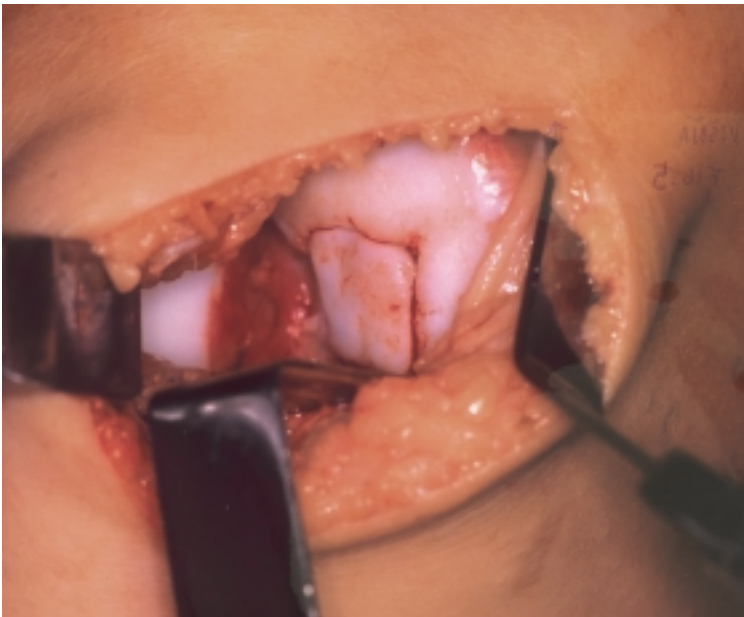

Fig. 6
Applied chondrograft

Following methods for quality control were used:

Determination of cells number.

Determination of cell viability by trypan blue staining. Viability between 90–95 % was demonstrated.

Determination of proliferative activity was tested using growth quality control. The small part of chondrograft was placed into Petri dish and incubated in culture medium. Migration and outgrowth of chondrocytes was documented.

The morphological characteristics were studied by:

Light microscopy (haematoxylin-eosin staining).

Electron microscopy (transmission and scanning). A good stage of cellular organelles and production of extracellular matrix with protocollagenic fibrils were found in all cases.

Immuno-fluorescence microscopy (using monoclonal antibodies against vimentin) (*Fig. 2*).

We did not provide the cell DNA authentication or isoenzymatic analysis.

We use the fibrin tissue glue Tissucol (Baxter, Austria) as a three dimensional carrier for chondrocyte culture because of excellent viability of chondrocytes and their migration ability to Tissucol surface. (*Fig. 3*).

Before surgery the chondrocyte suspension was mixed with fibrin glue and applied into special form (*Fig. 4*). The advantage of this procedure is the ability to adapt the size and thickness of graft according to cavity size and deepness. Prepared chondrograft was transported to operating room, reshaped and transplanted into defect. Fixation was realised via agglutination with fibrin glue (*Figs. 5, 6*).

RESULTS

Our study included 14 patients treated with technique of cultivated chondrocytes in Tissucol. (10 males, 4 females). Average age in the study group was 35.0 years (range 19–50 years). The injury was caused by trauma in 12 cases (acute – 4 cases, chronic – 8 cases) and 2 cases were diagnosed as osteochondritis dissecans. Duration of clinical symptoms before surgery was 0–650 days. Average size of cartilage defect was 2.7 cm², reaching from 1.7–4.5 cm². Chondral defect was localised on the weight-bearing area of medial femoral condyle in 10 cases, on the weight-bearing area of the lateral condyle in 4 cases.

We observed concomitant injuries of the soft knee:

rupture of anterior crucial ligament in 9 patients,

lesion of medial meniscus in 4 patients,

lesion of lateral meniscus in 3 patients,

patellar chondromalacia up to degree II.a. in 4 patients.

Monotrauma of cartilage on the weigh-bearing area was observed in 4 cases. In remaining 10 cases was combination of chondral defect with above listed injuries. Chondrografts application was provided from open approach.

We have not observed any serious clinical complications during the postoperative period. The reactive synovitis with exudation was documented in 4 cases (28 %). Clinical symptoms disappeared after application of nonsteroid antiflogistics in 4 weeks. We have eliminated any mechanical loading for 8 weeks and full weight-bearing was allowed after 12–16 weeks. Intensive rehabilitation was an obligatory part of postoperative care.

Follow up of patients was provided 5 and 12 months after surgery (*Table 1*).

Table 1

Defects treated with autologous chondrograft, Lysholm score before surgery, 5 and 12 months after surgery

Number of patients N	14
Lysholm score before surgery	49.3
Lysholm score 5 months after surgery	76.5
Lysholm score 12 months after surgery	81.0

The preoperative value of Lysholm knee score was 49.3 points, 5 months after surgery 76.5 points and 12 months after surgery 81.0 points. Good and excellent results were reached in 10 patients.

Second look arthroscopy was provided in four patients 3–5 months after chondrograft transplantation. In two patients very good, complete healing of graft was documented. Two cases of partial chondrograft degeneration (30 % of graft area) were documented. Graft surface was evaluated according to cartilage repair assessment system (ICRS – cartilage score). Average ICRS cartilage's score was 8.0 points (almost normal graft surface). During second-look arthroscopy samples for conventional light and electron microscopy were obtained. Microscopic controls documented presence of hyaline-like cartilage in the healing defect (presence of typical spherical chondrocytes, extracellular collagenous filaments, formation of typical isogenetic cellular groups) (*Figs. 7, 8, 9*). In cases of graft degeneration (fissuration) found during second look arthroscopy we documented neovascularisation of reparative tissue with presence of fibroblast-like cells.

DISCUSSION

Clinical good and excellent results (according to Lysholm's score) in patients treated by autologous chondrocyte transplantation in Tissucol have been 71 % in the first 14 patients who were treated by authors. Improvement of clinical status were documented in all 14 patients, none patient was worsened. In comparison, the marrow stimulation techniques studies reached good and excellent results in 50–75 % of cases (*12*).

Currently, our technique of autologous chondrocyte transplantation involves an open procedure with inherent disadvantages of adhesions and a more prolonged recovery. However, these disadvantages must be weighed against the procedure's ability to produce a tissue with greater durability (hyaline-like

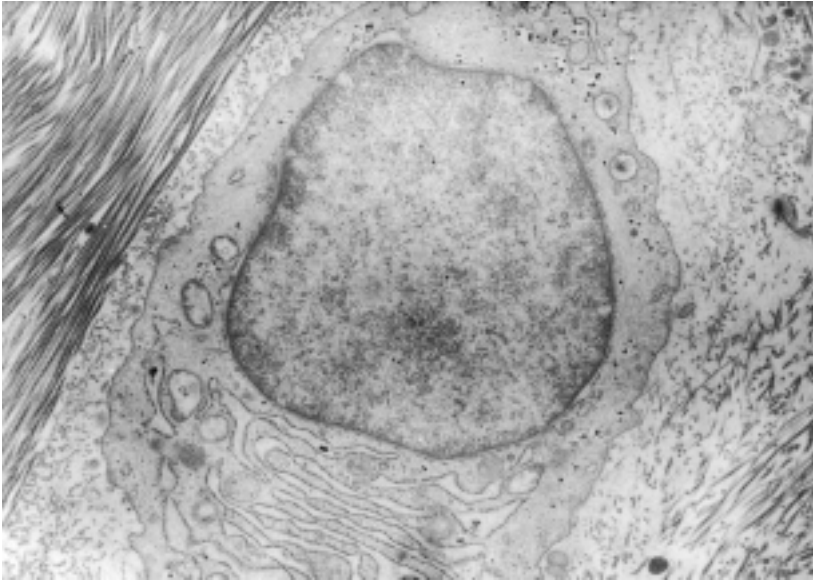


Fig. 7

Presence of typical spherical chondrocytes – samples obtained by second look arthroscopy

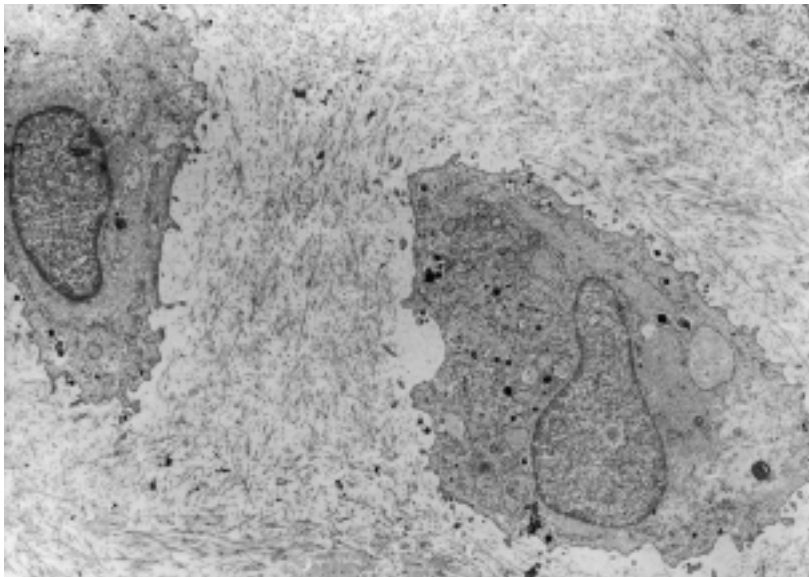


Fig. 8

Formation of typical isogenetic cellular groups – samples obtained by second look arthroscopy

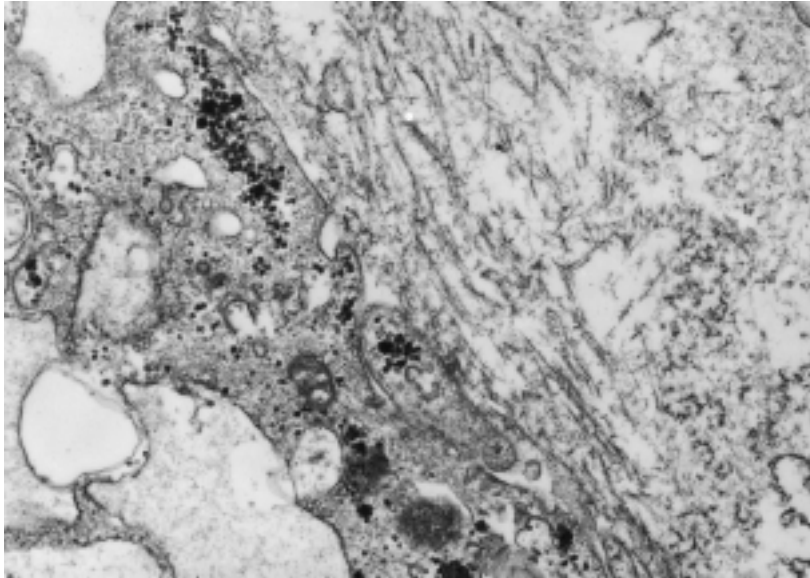


Fig. 9

Presence of extracellular collagenous filaments – samples obtained by second look arthroscopy

cartilage) than repairs after traditional marrow-stimulation techniques (fibrocartilage). Described technique should be reserved for first-line treatment of patients with large lesions (above 2 cm²) who have high physical demands and as revision therapy in patients with large lesions, who have not responded to alternative marrow stimulation techniques and who remain symptomatic.

CONCLUSIONS

Based on the successful clinical outcomes observed in this study, the authors conclude that for large full thickness chondral and osteochondral lesions located on the weight-bearing surfaces of the femur, autologous chondrocyte transplantation in Tissucol offers an important treatment option. ACT offers the opportunity for symptomatic relief and return of joint function needed for active lifestyle.

Acknowledgement

Supported by Grant IGA MZ ČR No. 5972–3.

LÉČBA KLOUBNÍCH DEFEKTŮ KOLENE POMOCÍ AUTOLOGNÍ TRANSPLANTACE CHONDROCYTŮ

S o u h r n

Defekty chrupavky v plné tloušťce představují běžný, ale velmi závažný problém chirurgie kolene. Limitovaná schopnost reparace chrupavky je dnes všeobecně známou skutečností. Klinické potíže pacientů s defektem chrupavky v plné tloušťce jsou výrazné a vedou k předčasnému rozvoji kloubní artrózy. Bylo vyvinuto mnoho technik k léčení těchto defektů (abrase, návrty, autograft, allograft, transplantace buněk). Jednou z možností terapie je využití techniky kultivace chondrocytů v kombinaci s Tissucolem (Baxter, Austria). Tato technika byla vyvinuta v Úrazové nemocnici v Brně. První pacient byl operován v roce 1998 a do konce roku 2002 jsme odoperovali 25 pacientů. Prospektivně jsme vyhodnotili skupinu 14 pacientů jeden rok od operace. Dosáhli jsme uspokojivé časné výsledky, 71% pacientů mělo dobré nebo výborné hodnocení (hodnoceno podle Lysholmova skóre). Průměrné dosažené Lysholmovo skóre ve sledované skupině bylo 76.5 bodu 5 měsíců po operaci a 81.0 bodů 12 měsíců od operace. U čtyř pacientů jsme provedli second-look artroskopii s nálezem dobrého přehojení defektu. Povrch nové chrupavky byl zhodnocen podle ICRS skóre s průměrnou hodnotou 8.0 bodu. Kontrolní biopsie prokázala novotvorbu reparační tkáně charakteru hyaline-like chrupavky. Byl prokázán výskyt typických chondrocytů a kolagenních fibril.

REFERENCES

1. *Brittberg M, Lindahl A, Nilsson A, Ohlsson C, Isaksson O.* Treatment of deep cartilage defects in the knee with autologous chondrocyte transplantation. *The New England Journal of Medicine* 1994 14: 889–895.
2. *Wakinati S, Goto T, Pineda SJ, Young GR, Mansour JM.* Mesenchymal cell-based repair of large, full-thickness defects of articular cartilage. *J Bone Joint Surg* 1994 4: 579–592.
3. *Hart R.* Rengenologická analýza osového postavení dolní končetiny před a po vysoké tibiální obloukové osteotomii. *Acta Chir Orthop Traum Czech* 1996 63: 88–90.
4. *Hart R.* Význam arthrografie kolenního kloubu v době rozvoje artroskopické techniky. *Acta Chir Orthop Traum Czech* 1997 64: 25–28.
5. *Janeček M, Dufek P.* Generalizovaná haemangiomatosis ve vztahu k synovialis. *Acta Chir Orthop Traum Czech* 1986 52: 212–218.
6. *Janeček M.* Chondroma patellae proliferans. *Acta Chir Orthop Traum Czech* 1985 52: 432–435.
7. *Peterson L, Minas T, Brittberg M, Nilsson A, Sjogren-Jahnsson E, Lindahl A.* Two- to 9-Year Outcome After Autologous Chondrocyte Transplantation of the Knee. *Clin Orthop* 2000 374: 212–234.
8. *Višňa P, Adler J, Nestrojil P, Pokorný V.* Současné možnosti řešení chondrálních a osteochondrálních defektů kolene. *Rozhledy v chirurgii* 1999 6: 259–264.
9. *Višňa P, Paša L, Hart R, Folvarský J, Adler J, Horký D.* Treatment of deep cartilage defects in the knee by mosaicplasty combined with autologous cultivated chondrocytes in Tissucol (Abstract). *Europ J of Trauma* 2002, 28 (Suppl 1): 43.
10. *Adler J, Komarková J, Horký D, Višňa P.* Cultured autologous chondrografts for the treatment of cartilage defects. *Proc. 26th Annual Meeting American Association of Tissue Bank* 2002, Boston, Massachusetts, p.83.
11. *Noyes FR, Stabler CL.* A system for grading articular cartilage lesions at arthroscopy. *Am J Sports Med* 1989 17: 505–513.
12. *Ewing JW.* Arthroscopic treatment of degenerative meniscal lesions and early degenerative arthritis of the knee. In: *Ewing J.W., eds. Basic Science and Arthroscopy*, Raven Press, New York, 1990: 137–145.