

# ABDOMINAL HEMANGIOSARCOMA - AN UNUSUAL CASE OF ACUTE ABDOMEN.

## CASE REPORT

STAŠEK T.<sup>1</sup>, GORBUNOV E. A.<sup>1</sup>, KLUSÁKOVÁ J.<sup>2</sup>

<sup>1</sup>First Department of Surgery, St. Anne's Faculty Hospital, Faculty of Medicine,  
Masaryk University, Brno

<sup>2</sup>First Department of Pathology, St. Anne's Faculty Hospital, Faculty of Medicine,  
Masaryk University, Brno

*Received after revision April 2004*

### Abstract

In our case report and literature review we report on a rare case of acute abdomen - bleeding angiosarcoma of the stomach. Our patient was a 26-year-old woman. We present the current classification of tumours of the gastrointestinal tract, including peroperative and histological evidence.

In the discussion we present two-year results after the surgery. Conclusions: Malignant vascular tumours are an infrequent disease, but are very aggressive if occurred. Complete curative removal can be feasible in patients with localized lesions.

### Key words

Acute abdomen, Angiosarcoma, Hemangiosarcoma

### INTRODUCTION

In our case report, we present one of the very infrequent but possible causes of acute abdomen - abdominal hemangiosarcoma. The patient presented is a young woman who underwent surgery in our department.

We would like to skip the general and well-known causes of acute abdomen and their classification in the present publication.

We present a classification of the gastrointestinal tumours, mainly because in the current time it is absent in the Czech literature (1, 3).

## GASTROINTESTINAL TUMOURS – CURRENT CLASSIFICATION (1)

### **Robbins, 1999:**

#### A: benign polyps

- hyperplastic polyps
- hamartoma polyps (juvenile - Peutz-Jeghers)
- inflammatory polyps
- lymphoid polyps

#### B: tumorous epithelioid lesions

- benign: adenoma
- malignant: adenocarcinoma, carcinoid (can be semimalignant)

#### C: mesenchymal tumorous lesions

- gastrointestinal stromal tumours (benign and malignant)
- next: lipoma, **angioma**, Kaposi's sarcoma

#### D: lymphomas (more frequent than carcinomas)

### Classification of vascular tumours of soft tissue (Enzinger (1))

#### I. Benign vascular tumours

##### A: Localized hemangioma

- capillary hemangioma (including juvenile type)
- cavernous hemangioma
- venous hemangioma
- arteriovenous hemangioma (racemose hemangioma)
- epithelioid hemangioma (angiolymphoid hyperplasia, Kimura's disease)
- hemangioma of granulation tissue type (pyogenic granuloma)
- miscellaneous hemangiomas of deep soft tissue (synovial, intramuscular, neural)

##### B: Angiomatosis (diffuse hemangioma)

#### II. Vascular tumours of intermediate malignancy (hemangioendothelioma)

##### A: Epithelioid hemangioendothelioma

##### B: Spindle cell hemangioendothelioma

##### C: Malignant endovascular papillary angioendothelioma

#### III. Malignant vascular tumours

##### A: Angiosarcoma (including lymphangiosarcoma)

##### B: Kaposi's sarcoma

## HEMANGIOSARCOMA

Hemangiosarcoma is a malignant mesenchymal tumour that has its origin in blood vessels. It develops lymphogenous and hematogenous metastases. In most cases it is localized to the liver, then (in descending order) spleen, breast, lungs, thyroid gland, and skeletal muscles. The incidence can, at least partially, be influenced by the environment – for example, liver hemangiosarcoma is a professional disease of those who work in PVC (polyvinyl chloride) production. From the point of epidemiology, it is rather a rare tumour (5,6,7,11,15) (Fig.1).

### CASE

The patient presented was a 26-year-old woman, previously completely healthy. Clinical history included light abdominal pain, which worsened two days before the admission. Clinical presentation at admission was diffuse abdominal pain, without peritoneal signs or peritonism (9); large painful resistance in the left mesogastrium and hypogastrium was palpable. Other physical findings on the abdomen were negative. Blood pressure and pulse frequency were normal. Pathological laboratory findings included: hemoglobin 98 g/l, leucocytes  $13.6 \times 10^9/l$ , bilirubin 37.4 mmol/l. Other laboratory parameters were normal.

Ultrasonography verified solid mass in the epigastrium, more on the left side, and ascites. CT findings: non-homogenous mass 12x10x18 cm in the left mesogastrium and epigastrium, during the post-contrast phase some parts of the stroma changed density from 30 to 100 HU. Relations to the surrounding tissues are unclear. Gynaecology examination was negative.

Because of progressing symptomatology few hours after admission the surgery was indicated (23.10.2002). The abdominal cavity was opened via middle laparotomy. A hemoperitoneum (700 ml) was found, along with a tumour of 10x12x20 cm in size, with many blood vessels on its surface, invading the posterior wall of the stomach (Fig. 2, Fig. 3).

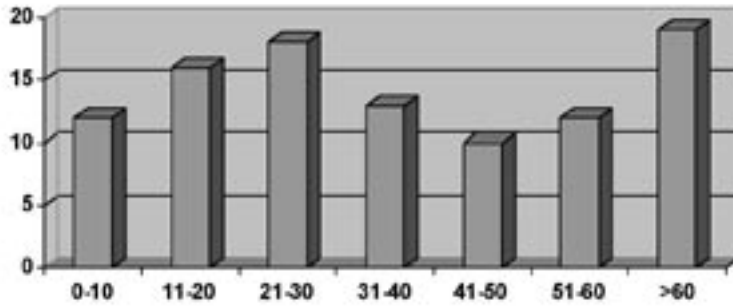
Due to these findings the tumour was excised completely (after dissection of the greater omentum); (Fig. 4) excision of the posterior wall of the stomach with biopsy of the resection margin (peroperative cryo-cut histology was negative, definitive histology was also negative); (Fig. 5) complete revision of abdominal cavity, drainage.

To prevent thrombembolia, low-molecular heparin (LWMH) was given (higher risk of thrombembolia vs. risk of bleeding (20)). After surgery, the patient was afebrile, vegetatively stabilized, the wound was healed without any complications, per primam intentionem.

Definitive histology showed that it was a “low-grade” angiosarcoma of the abdominal cavity (M - 9120/31), invading gastric wall through serosa to the smooth muscle layer (Fig. 6, Fig. 7).

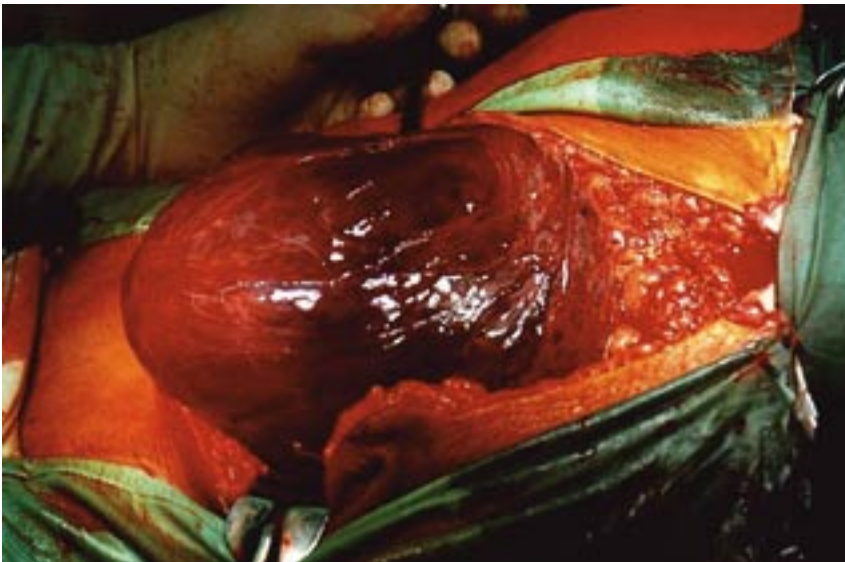
There were some doubts about this diagnosis due to the partly controversial immunohistochemistry results (negative factor VIII, CD34 and thrombomodulin); therefore differential diagnostics should also include the possibility of epithelioid leiomyosarcoma or gastrointestinal stromal tumour (Fig. 8).

Post-operational adjuvant therapy included four series of chemotherapy (Adriamycin + Isofosfamid + Mesna) with good tolerance. So far (by 30.5.2004), the patient is completely without any subjective problems and without signs of generalization or relapse – ultrasonography of the abdominal cavity is negative, CT scans of lungs, mediastinum, abdomen and pelvis minor are also negative, oncological markers (NSE) are negative, vaginal ultrasonography is negative, gastrofibroscopy and gastric endosonography are negative; she has no weight loss, either.



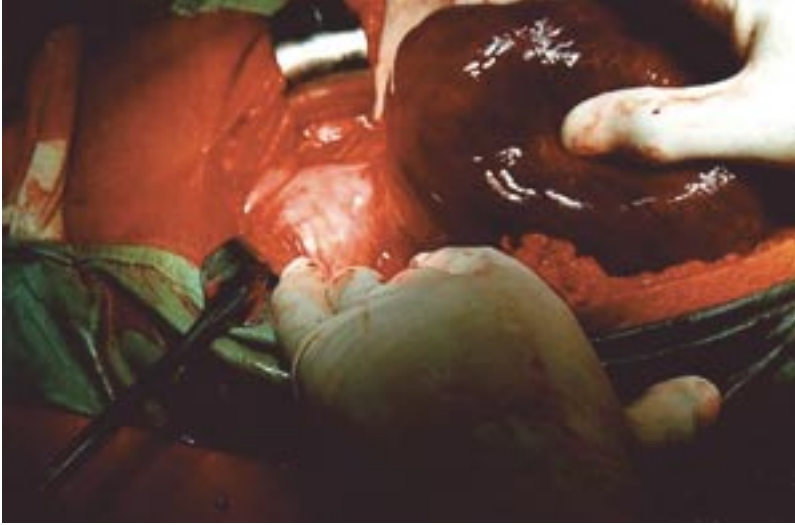
*Fig. 1*

Age distribution of patients with sarcomas of soft tissues (AFIP, 1966-1976) (89 cases) (11)

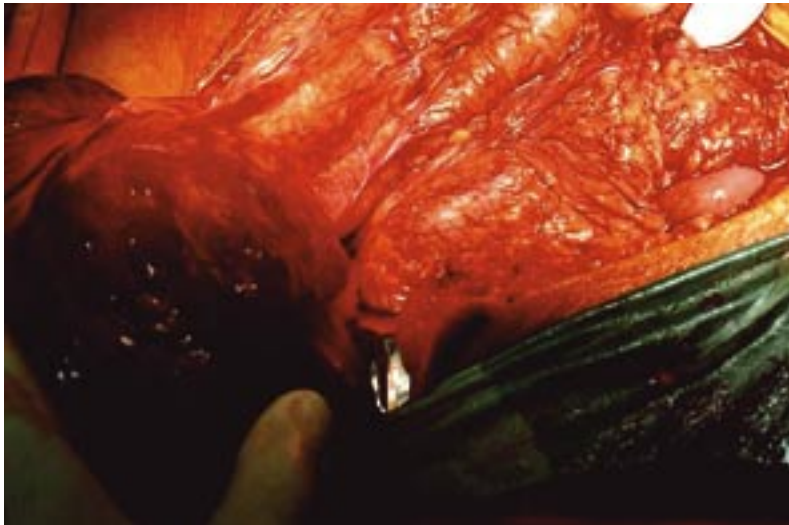


*Fig. 2*

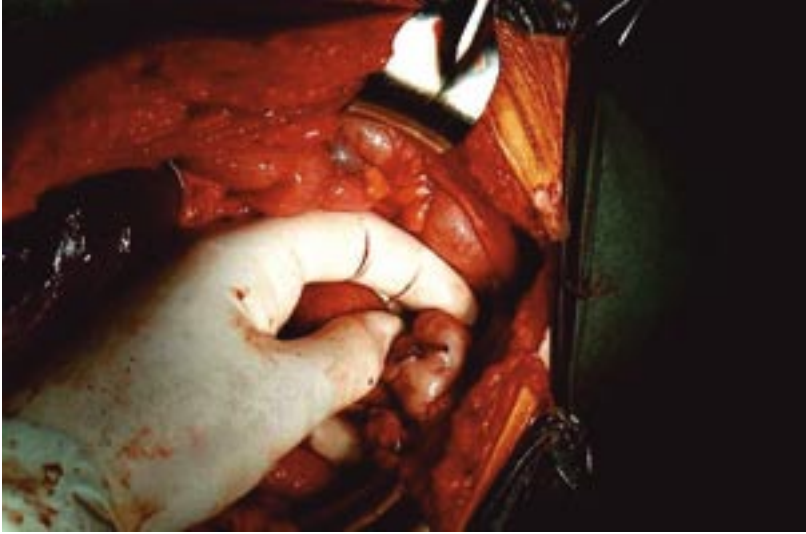Abdominal angiosarcoma - exclusion of the tumour after middle laparotomy



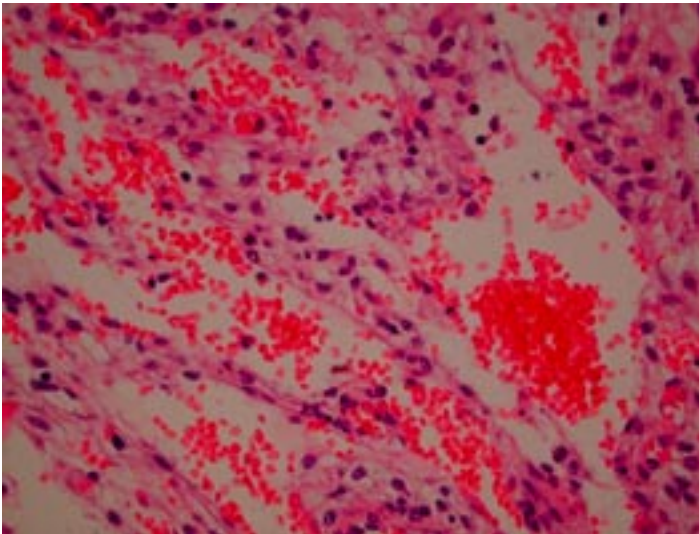
*Fig. 3*  
Visible blood vessels on the tumour surface  
and the direction of invasion (into the posterior gastric wall)



*Fig. 4*  
Tumour excision after the greater omentum was dissected;  
signs of malignant angiogenesis are visible.

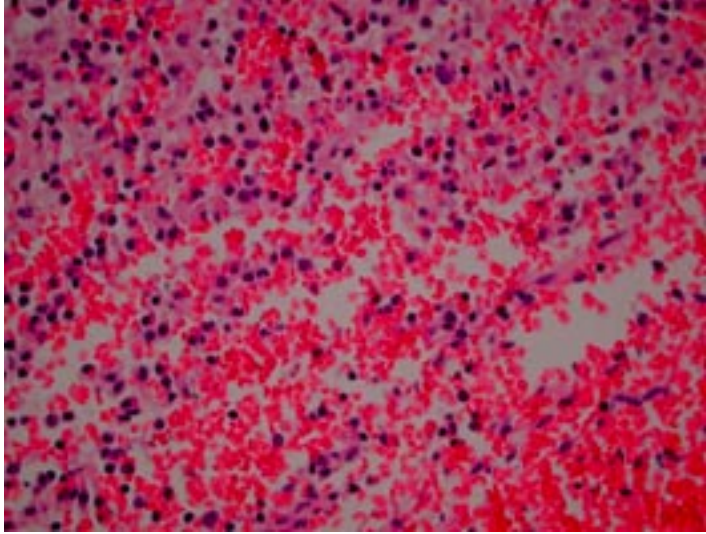


*Fig. 5*  
Detail of the site where the tumour invaded into the posterior gastric wall  
(after resection and suture)

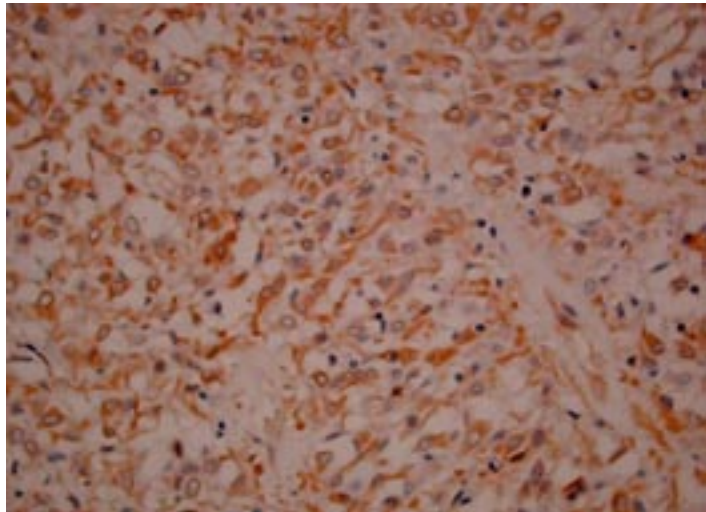


*Fig. 6*  
Cavernous vessel spaces are filled with groups of erythrocytes.  
Between them there are tumour cells with a pink cytoplasm and purple nuclei.





*Fig. 7*  
Tumour tissue with a big amount of blood vessels



*Fig. 8*  
Immunohistochemistry for the positivity of vimentin,  
which is a component that proves the mesenchymal origin of the tumour.  
The brownish areas of the cytoplasm mean positiveness.

## DISCUSSION

Hemangiosarcoma is a malignant mesenchymal tumour that has its origin in blood vessels. It develops lymphogenous and hematogenous metastases. In most cases it is localized to the liver, then (in descending order) to the spleen, breast, lungs, thyroid gland, and skeletal muscles. Liver hemangiosarcoma is also a professional disease of those who work in PVC production. From the point of epidemiology, it is rather a rare tumour. Even less frequently, hemangiosarcoma is a cause of intraabdominal bleeding (12). In some very rare cases, malignant mesenchymal tumours of the retroperitoneum (4) or pelvis minor (22) are found, which spontaneously perforate, causing bleeding into the abdominal cavity.

Analysis of the current literature shows that many surgical departments had similar experience with angiosarcomas (mostly in the abdominal cavity) (12, 15-19, 21). What is important is that the conclusions were also similar – angiosarcomas and vascular malignant tumours as a whole are very rare but, if occurred, have also a very aggressive growth pattern and symptomatology, including the tendency to bleeding (12, 15, 17, 19). A positive fact is that if the tumour is localized, its complete resection is often curable (16, 18). Our case supports this practice (though we should note that our patient had a “low-grade” angiosarcoma).

## CONCLUSIONS

Therapy of hemangiosarcomas is very difficult, as reported in the literature (8, 11, 13). A multidisciplinary approach should be always used, as the therapy is multimodal: surgery + adjuvant chemotherapy + radiotherapy (in some exceptional cases). Exact diagnosis (especially immunohistochemistry) is very important (13, 14).

*Stašek T., Gorbunov E. A., Klusáková J.*

## HEMANGIOSARKOM DUTINY BŘÍŠNÍ - VZÁCNÁ PŘÍČINA NÁHLÉ PŘÍHODY BŘÍŠNÍ

### S o u h r n

Ve stručném „case report“ předkládáme kazuistiku vzácné příčiny náhlé příhody břišní u mladé pacientky (26 let). Jednalo se o krvácející angiosarkom, prorůstající do zadní stěny žaludku. Uvádíme přehledné dělení nádorů gastrointestinálního traktu, peroperativní a histologickou fotodokumentaci. V diskusi ukazujeme stav pacientky po dvou letech od operace a srovnáváme zkušenosti jiných pracovišť.

Závěrem konstatujeme, že maligní vaskulární tumory jsou vzácnou příčinou náhlé příhody břišní. Pokud se však objeví, jsou velmi agresivní v růstu a symptomatologii, ale mohou být kurativně resektabilní.



## REFERENCES

1. *Enzinger FM, Weiss SW*. Soft tissue tumours. 2nd ed. St. Louis: Mosby, 1988.
2. *Bednár B et al*. Základy klasifikace nádorů a jejich léčení [Fundamentals of the classification of tumours and their treatment]. Praha: Avicenum, 1987.
3. *Rosai J*. Ackerman's Surgical Pathology. 8th ed. Saint Louis: Mosby, 1996.
4. *Wechsler J, Čapov I, Jedlička V, Žák J*. Abdominal neuroblastoma of the retroperitoneum. Bratisl Lek Listy 2000; 101(12): 660-661.
5. *Evans HL*. Smooth muscle tumours of the gastrointestinal tract. Cancer 1985; 56: 2242.
6. *Ranchod M, Kempson RL*. Smooth muscle tumours of the gastrointestinal tract and retroperitoneum. Cancer 1997; 39: 255.
7. *Deck KB, Silberman H*. Leiomyosarcomas of the small intestine. Cancer 1979; 44: 323.
8. *Weidner N, Zekan P*. Carcinosarcoma of the colon. Cancer 1986; 58: 1126.
9. *Kalač J, Veřková L*. Peritonismus [Peritonism]. Rozhl Chir. 1999; 78 (1): 6-8.
10. *Cornog JL*. Gastric leiomyoblastoma - clinical study. Cancer 1979; 34:711.
11. *Lezama dell P et al*. (Memorial Sloan-Kettering Cancer Center). Malignant vascular tumours in young patients. Cancer 1993; 83:1634.
12. *Slovacek R, Miculka P*. Angiosarcoma of the liver as a cause of massive hemoperitoneum. Rozhl Chir. 1999; 78:99-101.
13. *Usuda H, Naito M*. Multicentric angiosarcoma of the gastrointestinal tract. Path Int 1997; 47:553.
14. *Appleton MA, Attanoos RL, Jasani B*. Thrombomodulin as a marker of vascular and lymphatic tumours. Histopathology 1996; 29:153-157.
15. *Marc RJ, Poen JC, Tran LM, Fu LM, Lulliard G F*. Angiosarcoma - report of 67 patients and a review of the literature. Cancer 1996; 77: 2400.
16. *Naka N, Ohsawa M, Tomita Y, Kanno H*. Prognostic factors in angiosarcoma: a multivariate analysis of 55 cases. Surg. Oncol 1996; 61: 170-176.
17. *Rozario A, Ravis HR*. Angiosarcoma of coecum: unusual presentation with intususpection. Indian J Gastroenterol 1995; 14: 31.
18. *Chami TN, Ratner LE, Henneberry J, Smith DP*. Angiosarcoma of the small intestine. Am J Gastroenterol 1994; 89: 797-800.
19. *Maziak DE, Peterson R, Perkins*. Angiosarcoma of chest wall. Ann Thorac Surg 1999; 67: 839.
20. *Čapov I, Wechsler J, Penka M, Vlček P, Vraspír V*. Naše zkušenosti s použitím nízkomolekulárního heparinu v prevenci trombembolické nemoci [Our experience with the use of low-molecular heparin in the prevention of thromboembolic disease]. Plzeňský lék. sborník 1990; suppl. 61: 25-27.
21. *Čapov I, Wechsler J, Vokurka J, Mach P, Jedlička V, Žák J*. Život ohrožující krvácení v oblasti hrudníku [Life-threatening haemorrhage in the thoracic region]. Bratisl Lek Listy 1998; 12: 668-669.
22. *Čapov I, Wechsler J, Hušek K*. Agresivní angiomyxom pelveoperitoneální oblasti [An aggressive angiomyxoma of the pelvioperitoneal region]. Rozhl Chir.1997; 76 (12): 613-615.

