

PUNCTURE INJURY OF THE THORAX IN A PATIENT WITH HAEMOPHILIA A. CASE REPORT

BIBROVÁ Š., TŮMA J., GÁL P.

Department of Paediatric Surgery, Orthopaedics and Traumatology, Faculty Hospital, Faculty of Medicine, Masaryk University, Brno

Received after revision September 2004

Abstract

Thoracic injuries rank among serious injuries. These injuries are often complicated by major blood loss, haemothorax or pneumothorax endangering the patient's life. The injuries are often associated with injuries of intra-abdominal organs, the diaphragm, injuries to the neck and spine.

The congenital deficit of factor VIII – haemophilia A – is one of the serious haemorrhagic disorders. Even a minor injury may lead to massive bleeding, which may endanger the patient's life unless adequate treatment is provided.

The present case report describes a case of a 17-year-old patient with a puncture wound in the left thorax. The patient suffered from a severe form of haemophilia A.

Key words

Puncture wound, Thorax, Haemophilia A

INTRODUCTION

Thoracic trauma ranks among serious injuries. Besides the thoracic wall, the respiratory and mediastinal organs may be injured. These injuries are sometimes complicated by massive intrathoracic bleeding from the main blood vessels and the heart, tamponade, the occurrence of haemothorax or pneumothorax, unstable thoracic wall, obstruction of the airways endangering the patient's life. Thoracic trauma is often associated with injuries of the intra-abdominal organs, the diaphragm, injuries to the neck and spine.

Haemophilia A is one of the most frequent coagulopathies. It is caused by a congenital deficit of factor VIII. The occurrence in the population is approximately 1:15 000–20 000. It is bound by chromosome X. It predominantly manifests itself in men. A total of 3 forms are distinguished on the basis of the values of factor VIII: a severe form with the factor VIII values below 1 %, a moderate form with values of 1–5 %, and a mild form of haemophilia with the factor VIII values between 5–40 % (1). Even a minor injury in a patient with the severe form of haemophilia may result in massive bleeding which, without adequate treatment, may endanger the patient's

life through various forms of bleeding – CNS, soft tissues, joints, etc. A surgical operation itself may result in massive bleeding.

Patients with haemophilia A need a specific replacement therapy for the bleeding consisting mainly in the transfusion of the factor VIII concentrates. The biological half-time of the transfused factor VIII is 8–12 hours, unless its consumption increases *in vivo*.

The required volume of the factor VIII concentrate is calculated on the basis of the following formula: I.U. F.VIII = patient's weight (kg) x required increase of F.VIII (%) x 0.6. In case of massive bleeding we make an effort to increase the factor VIII value to 100 %, minimally at 70 %.

In urgent cases a dose of 50 units of factor VIII/kg of the patient's weight is administered before a surgical operation even without previous determination of the factor VIII level in blood. The dose is then corrected according to the values (2, 3).

The system therapy of bleeding in the case of a patient with haemophilia A may be assisted by antifibrinolytics, mainly for the mild forms. These are contraindicated in haematuria.

CASE REPORT

In 2002, a 17-year-old patient with severe haemophilia A was admitted to the Department of Paediatric Surgery, Orthopaedics, and Traumatology in Brno. He was on prophylaxis with factor VIII replacement 3 times a week. He was found in the street with a puncture wound in the chest. He was transported by ambulance to the catchment hospital, where an urgent CT of the thorax showed an extensive left haemothorax and a smaller pneumothorax, overpressure of median line structures on the right; presence of blood in the pericardium was not indicated (*Fig. 1*). Due to the finding and the clinical condition of the patient, suffering from a pre-shock, he was transported to the life-support ward of the Faculty Paediatric Hospital in Brno.

On admission, the patient suffered from a pre-shock, was afebrile, blood pressure 100/60 mm H₂O, pulse rate 120/min, tachypnoea. Laboratory examination detected the level of Hb 65g/l, htc 0,20, leukocytes 22.5.10⁹/l, in coagulation Quick 1,6 R, antithrombin III 63 %, and the level of factor VIII was 0.6 %.

Immediately after admission, intubation of the patient using a two-way cannula was made, thoracic drainage was introduced, and 2.500 units of factor VIII (Immunate) were transfused. The patient was connected to mechanical ventilation and monitored, whereupon insertion of the thoracic drainage (diameter 1cm) was stopped until the operation due to massive bloody aspiration.

Once the haemocoagulation improved and factor VIII was 100 % replaced, acute revision of the thorax was performed. This started 8 hours after admission. First, diagnostic thoracoscopy was performed, which concluded that the puncture wound led from the 4th left intercostal space and hit the 5th and 7th segment of the left lung; the puncture canal was 1.5 cm on average. The pericardium and the heart were without lesion.

Suture of the afflicted lung segments was performed with assistance from minor thoracotomy (*Figs. 2–5*). Bleeding from the thoracotomy was stopped using argon coagulation. No serious complications occurred during the operation. One left-sided thoracic drainage was retained. After the operation, it was still necessary to replace factor VIII each 6 hours. On the second day after the operation, the condition got complicated by a right-sided pneumothorax, and therefore also a right-sided thoracic drainage was introduced. A check ultrasound examination of the abdomen detected a slight subcapsular haematoma of the spleen, which required a surgical solution and was treated conserva-

tively. The patient's condition gradually stabilised and improved; on the sixth day after the operation he was disconnected from the mechanical ventilation and extubated. Likewise, the thoracic drainage was removed from both sides. On the 10th day after the operation, the patient was transported to a standard ward where the level of factor VIII kept being monitored - 30 %. On the 16th day (*Fig. 6*), he was dismissed from hospital for home care. Later, during an outpatient examination, no complications were discovered.

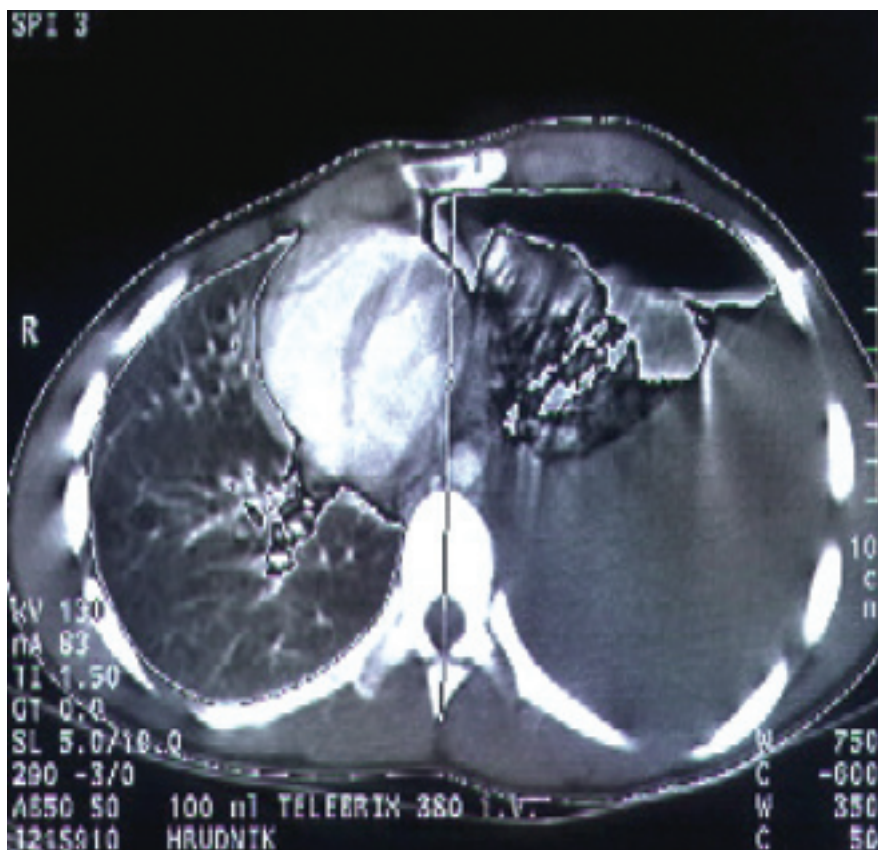

Fig. 1
Urgent CT scan of the thorax

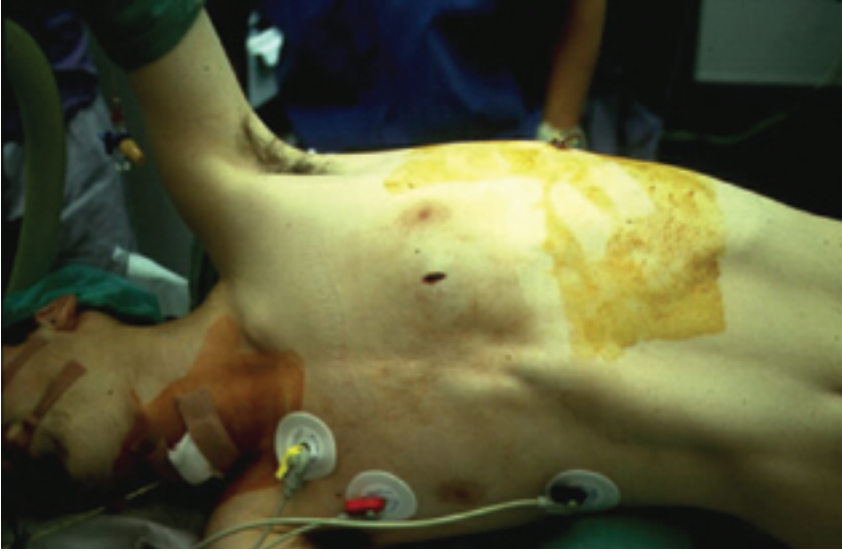

Fig. 2
Operation - thoracotomia (position of the patient)

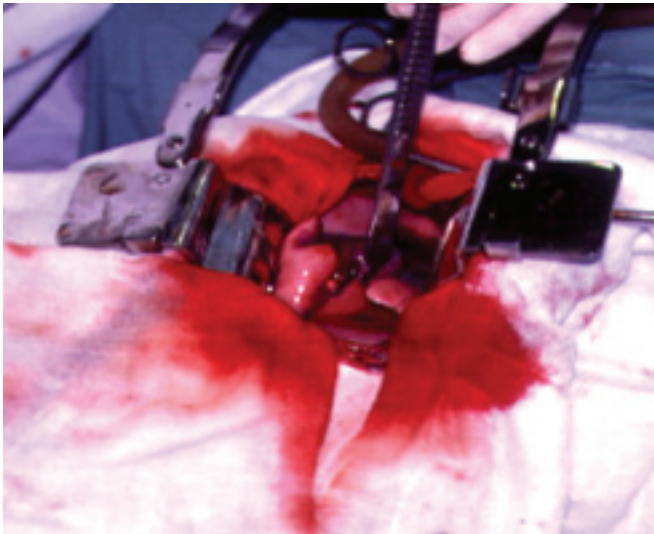


Fig. 3
Operation - thoracotomia 1

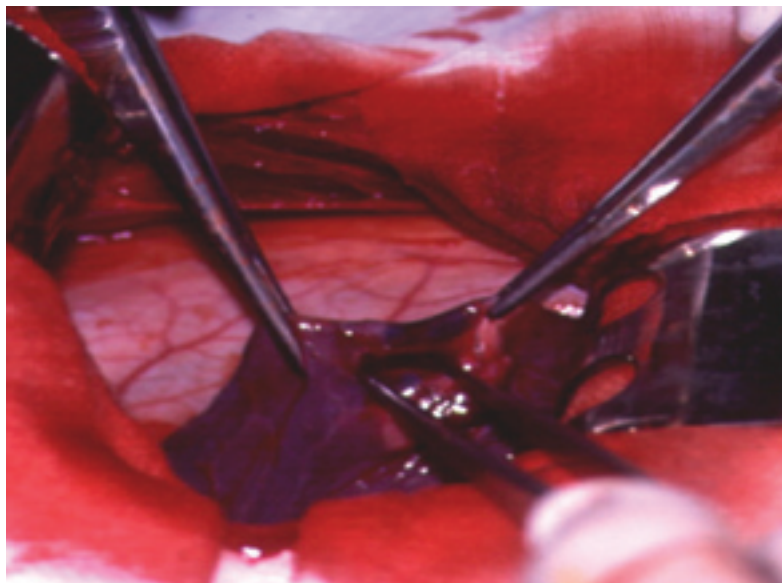


Fig. 4
Operation - thoracotomia 2

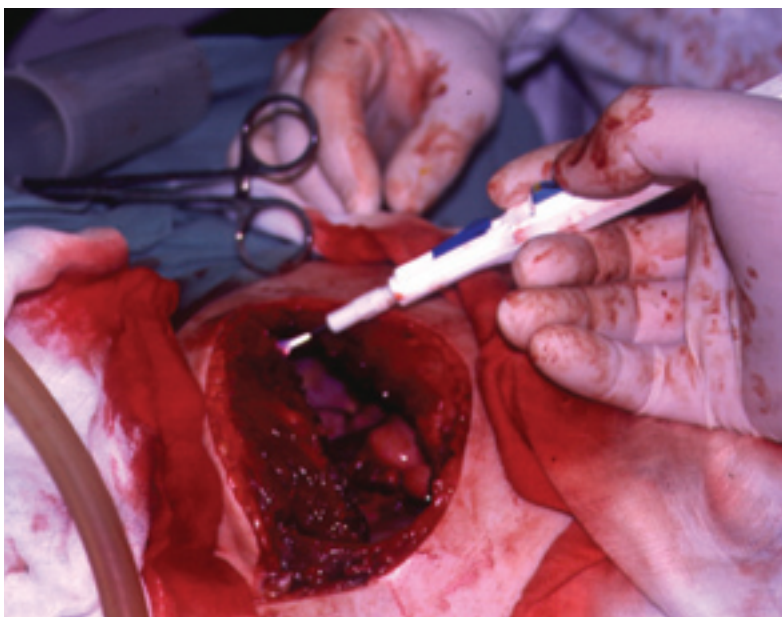


Fig. 5
Operation - thoracotomia (the argon coagulation)

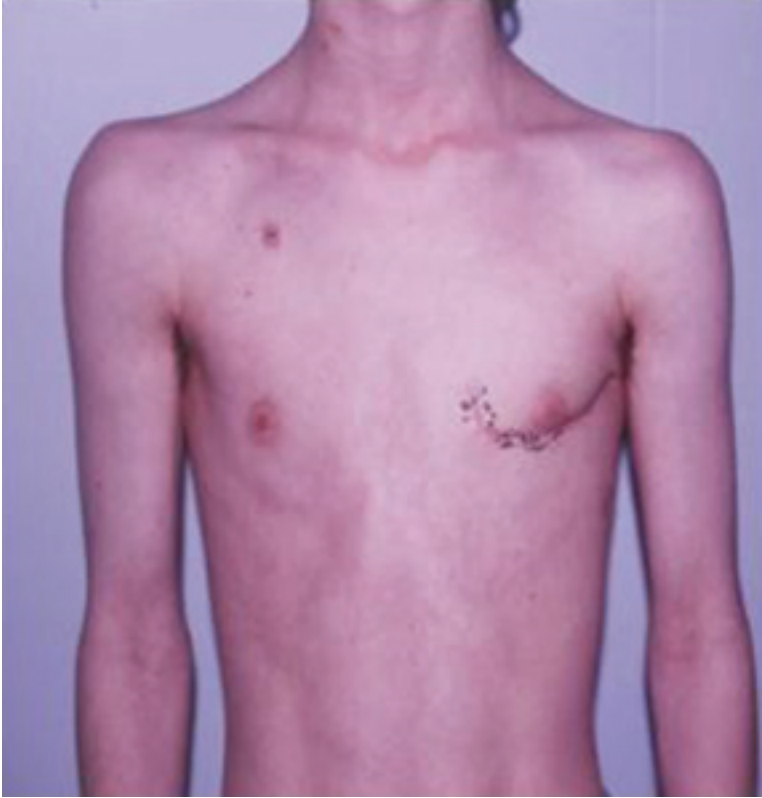

Fig. 6
The patient 's condition on the 16th postoperative day

DISCUSSION

The surgical operation itself may result in massive bleeding in patients with haemophilia A. Before each operation it is necessary to replace factor VIII. The biological half-time of the transfused factor VIII is 8–12 hours, unless its consumption increases in vivo.

In urgent cases a dose of 50 units of factor VIII/kg of the patient's weight is administered before a surgical operation even without a previous determination of the factor VIII level in the blood. The dose is then corrected according to the values (2, 3).

Thoracic trauma is a serious injury, most often it concerns blunt injuries (4) with the main causes being traffic accidents in children (5, 6). Over a 17-year period, Ceran recorded 1.653 patients with thoracic trauma, of which 225 were children, prevalingly boys (88.44%). The most frequent were blunt injuries (60%), puncture wounds represented 29.77%, and gunshot wounds 9.77%. A total of 217 children

were treated conservatively, operation was necessary in 8 cases, none of the patients died. Crankson presents 91 patients over a 6-year period up to the age of 12 suffering from thoracic trauma. In 87 cases these were blunt injuries and in 4 cases penetrating wounds (1 puncture wound and 3 gunshot wounds). The most frequent were lung contusion (70), pneumothorax (32), and broken ribs (20). The injuries were often part of combined injuries (head 45, abdomen 41, skeleton 26). Thoracic trauma was treated conservatively or with drainage in most cases, thoracotomy was only needed in one child (6). Over 34 months, Peclet studied 2.086 children under the age of 15 with blunt or penetrating injuries. Of the total number of thoracic traumas, this was suffered by 104 children (4.4%/ and in 82% of the children it was part of multiple injuries. The most frequent cause of the injury was a traffic accident. In 48 % it concerned lung contusion, in 39 % pneumo/haemothorax or both, and in 32 % broken ribs. The total mortality rate was 26 % and the highest mortality rate was observed in children with heart and major blood vessel injuries (75 %), haemothorax (53 %), lung laceration (43 %), and broken ribs (42 %). As regards the isolated thoracic trauma, the mortality rate was 5 %, in the case of thoracic trauma and abdomen injury the rate was 20 %, with head injury and thoracic trauma 35 %, and with head injury, thoracic trauma and abdominal injury it was 39 % (7).

CONCLUSION

Even such a serious injury as thoracic trauma can be treated in patients with coagulation disorders with success. These patients must be brought to a specialised ward in time - a traumatological centre, where a comprehensive multidiscipline treatment including a surgeon, an anaesthesiologist, and a haematologist is provided upon admission.

Bibrová Š., Tůma J., Gál P.

BODNÉ PORANĚNÍ HRUDNÍKU U PACIENTA S HEMOFILÍÍ A - KAZUISTIKA

Souhrn

Poranění hrudníku je závažné zranění. Tato zranění bývají komplikována velkými krevními ztrátami, hemothoraxem či pneumothoraxem, které dále ohrožují život pacienta. Poranění bývají často sdružena s poraněním nitrobřišních orgánů, bránice, poraněním krku i páteře.

Dědičný deficit faktoru VIII - hemofilie A - patří mezi závažná hematologická onemocnění. I při drobném poranění může dojít k masivnímu krvácení, které bez adekvátní léčby může ohrozit život pacienta.

V předvedené kasuistice uvádíme případ 17letého pacienta s bodnou ránou v levém hrudníku. Pacient trpěl těžkou formou hemofilie A.

REFERENCES

1. Braunwald E, Isselbacher KJ, Petersdorf RG, Wilson JD, Martin JB, Fauci AS. Harrison's Principles of Internal Medicine. New York: McGraw-Hill, 1987: 1477-8.
2. Schettler G, Usadel KH, Deppermann D, Friedmann B et al. Repetitorium praktického lékaře [A Physician's Manual]. Galén, 1995: 892-3.
3. Marek J et al. Farmakoterapie vnitřních nemocí [Pharmacotherapy of Internal Diseases]. Grada Publishing, 1995: 205-207.
4. Way LW et al. Současná chirurgická diagnostika a léčba, I. díl [Current Surgical Diagnostics and Therapy, Pt. I]. Grada Publishing, 1998: 298-303.
5. Ceran S, Sunam GS, Aribas OK, Gormus N, Solak H. Chest trauma in children. Eur J Cardiothorac Surg 2002; 21 /1/: 57-9.
6. Crankson SJ, Fischer JD, Al-Rabeeah AA, Al-Jaddan SA. Pediatric thoracic trauma. Saudi Med J 2001; 22(2):117-20.
7. Pecket MH, Newman KD, Eichelberger MR, Gotschall CS, Garcia VF, Bowman LM. Thoracic trauma in children: an indicator of increased mortality. J Pediatr Surg 1990; 25 /9/: 961-5, discussion 965-6.