

## SUTURE OF MENISCUS

PAŠA L.<sup>1,2</sup>, VIŠŇA P.<sup>3</sup>

<sup>1</sup>Traumatological Hospital, Brno

<sup>2</sup>Department of Traumatology, Faculty of Medicine, Masaryk University, Brno

<sup>3</sup>Department of Traumatology, Clinic of Surgery, Second Medical Faculty, Charles University, Prague

*Received after revision August 2005*

### Abstract

Meniscus rupture is one of the most frequent injuries of the knee joint. Treatment usually involves removal of the injured part of meniscus, or meniscectomy. Postoperatively, however, overloading and degeneration of the knee compartment often occur, followed by signs of arthritic changes. As a consequence of this process, the morbidity of patients significantly increases, resulting in increased consumption of medications. Ultimately this disorder requires Total Endoprosthesis Implantation.

With the advent of arthroscopy in the 1980s, meniscectomy was more carefully performed to preserve the uninjured portion of the meniscus. Overloading in the particular compartment is therefore lower, and more cartilage is preserved.

As arthroscopy developed, especially regarding overview of the joint, and with new knowledge of the biomechanics of the knee joint, recent measures aim to preserve the meniscus. This study focuses on techniques of suturing injured menisci via arthroscopy.

Several factors are vital in assessing preservation of the meniscus: the type of rupture, injury site (red-red, red-white zone), the time elapsed after injury, joint stability, and overall biomechanical degeneration of the joint. Three basic techniques of meniscal suture are described: outside-in, inside-out, and all-inside. PDS stitches of 0- and 1-gauge were used. The stitches were applied arthroscopically. In the case of knee joint instability, it is appropriate to repair the ligaments and/or cartilage simultaneously. Postoperatively, joint fixation via a rigid splint is used, with early rehabilitation under limited motion and loading. Ambulation is recommended from the 7th week after surgery, while light sports or jogging are postponed until 3 months after operation.

Between 1994 and 2001, the authors performed a total of 242 sutures of the meniscus; 192 of the medial meniscus; 50 lateral; and in 7 patients, sutures of both menisci were done simultaneously. The range of the patients' age was 14 to 72 years. Concomitant plastic surgery of the ACL was done in 48 patients; reinsertion of the ACL in 12 patients; mosaicoplasty in 6 cases; and early plastic surgery of the ACL (within 3 months of meniscal suture) was done on 16 patients.

Re-rupture of the meniscus was observed in 8 patients. These exclusively involved the medial meniscus, each time via renewed injury. The treatment was performed by meniscectomy in 6 patients, and by resuture in 2. Lysholm score in 1 year: excellent and good results were 96 %.

Preservation of the injured meniscus is paramount, especially for its biomechanical properties. Concurrent or early treatment of the joint instability via ligament repair is fully indicated. This is the only way to ensure and renew correct biomechanics of the knee joint. Mid-term results show either good or very good outcomes after these conservative procedures.

Arthroscopically assisted early suturing of the injured menisci in the well-perfused zone (red-red, red-white) assures beneficial possibilities for tissue healing and enables restoration of the correct biomechanics of the knee joint.

## Key words

Meniscus, Suture, Arthroscopy

## INTRODUCTION

Injury of the meniscus accounts for one of the most frequent traumatic afflictions of the knee joint. Treatment regimens (including the one that we used) have already been described early in the 19th century. William Hey described trauma of the meniscus as an “internal derangement of the knee”. Thomas Annandale’s work “Excision of Semilunar Cartilage Resulting in Perfect Restoration of Joint Movement” (1885) acclaimed the good to excellent results after removal of injured meniscus via arthrotomy (5,10).

Many years later the long-term results following removal of the meniscus were demonstrated. Presently, the consequences after meniscectomy (subtotal to total) are known. These include overloading the relevant compartment with consequent early degeneration of the cartilage. The resulting discomfort may torment the patient in their professional or social capacities. Morbidity increases, as does consumption of medications, and ultimately the need for total knee replacement.

The first published meniscus suture was done by *Thomas Annandale*, who sutured the anterior horn of the medial meniscus on November 16, 1883. His patient reportedly returned to work with a fully functional knee 10 weeks postoperatively (5).

The first arthroscopically assisted meniscus suture was done by *Hiroshi Ikeuchi* in 1969. *DeHaven* tried suture of the menisci via a posteromedial or posterolateral arthrotomy in the following year. General application of this method began after 1980, when *Henning* developed the instrumentarium and step-by-step instruction for the inside-out technique (5, 7).

With the advent of arthroscopic techniques in the 80s in the Czech Republic, treatment of the injured meniscus has undergone a radical transformation. The subtotal or total meniscectomy previously performed via arthrotomy was replaced via the more delicate partial meniscectomy. This spared joint capsule damage and preserved the healthy portion of the meniscus. The outcome is that overloading of the particular compartment is lower and thus the cartilage is preserved (8).

Most recently, we have also tried to preserve the damaged tissue, and if possible, reattach (via suture and meniscopexy) the injured meniscus (6).

This paper describes the possibility of meniscus suture using absorbable stitches, and presents the mid-term results.

## MATERIALS AND METHODS:

Menisci are fibrochondral semilunar pads on the internal and external surfaces of the knee joint. On split section, they have a triangular shape which perfectly fills the space from the centre to the periphery of the load-bearing component of the joint, so that pressure on the joint is optimally distributed to the greatest surface area. This form concurrently helps stabilise movement within the joint and

dampens transmitted forces. This is also due to its flexibility. Menisci also enable even lubrication of the synovial fluid, thereby helping with nutrition of the cartilage.

The shape of the femoral condyles is not spherical. Rather, the curvature of the joint surface is accentuated dorsally. Loading in that particular area changes, too, depending on movement of the joint. Biomechanical studies have demonstrated that more than 50% of vertical loading is transferred by the menisci when the knee is in full extension, while under 90° flexion, over 85% is transferred. It is therefore clear that after removal of meniscus, the particular compartment is overloaded. Removal of one third of the meniscus (25–35%) results in an increase of contact pressure to the cartilage by up to 350% of the original value (10).

Patients who have had their meniscus removed following trauma often have no significant difficulties within the first months or years. Severity depends on the percentage of meniscus removed; on the patient's weight; on work or sports loading; on the state of cartilage at the time of injury; on the joint axis; on joint stability, and many other factors. After a longer period of time (5 or more years, but earlier in some cases) pain and swelling of the operated joint can occur during loading (or after longer ambulation). These are the first signs of overloading. The consequent radiodiagnostic changes, natural with increasing age, are only secondary, irreversible signs.

A very frequent consequence after total or subtotal meniscectomy on the loading compartment is chondromalacia and subsequent gonarthrosis.

The goal of surgery is to preserve physiological conditions of the joint so as to prevent its degeneration.

Injury of the meniscus, rupture, disintegration or abruption are very variable. Preservation of the meniscus is dependent upon several important factors –type of rupture, localisation of injury, time elapsed after injury, joint stability, and overall biological age of the joint.

#### TYPES OF RUPTURE

The majority of loading of the meniscus occurs during knee flexion in the posterior half of the meniscus. Under the influence of many factors (rotation, extension or flexion mechanism of force, knee instability, strength of muscle groups, chondromalacia of the particular compartment, etc.), joint structures are overloaded, and rupture or abruption of the overloaded meniscus occurs. Obviously, the resulting size of the fissure can be a consequence of both one single sudden trauma or several recurring smaller traumas. The fissure can be vertically longitudinal, oblique, radial, or horizontal. There may be degenerative fibrosis and its combinations.

With respect to meniscus nutrition and healing, the position of the fissure is important. The fibrochondral tissue of the meniscus is nourished by two sources. Elemental nutrition is brought by vessels that are located only at the base of the meniscus. Distally, this vascular nutrition wanes on the internal margin of the interior and exterior surface of the meniscus. It is possible to divide the meniscus transversally into three parts based upon its vascular supply: (i) very well nourished, or the so-called red zone, which incorporates approximately 1/3 of the meniscus; (ii) the middle area, a relatively narrow red-white zone with only sporadic vessels; and (iii), the so-called white zone with no vascular nutrition. The tissue of the meniscus is also nourished by the intra-articular fluid. The extent of this nutrition is, however, low.

It is generally known that only nourished tissue can heal. This is why the location of a fissure and the time elapsed after injury are crucial to healing.

Acute fissures (up to one week after injury) at the base of meniscus (i.e. the red zone) are most amenable to suturing. Here the tissue quality is good and the bleeding fissure is easily seen. When an injury is inveterate and the quality of the meniscus is good, it is also possible to suture it. It is, however, necessary to perform curettage to the base of the meniscus, and in this way create conditions salubrious for tissue healing.

SUTURE TECHNIQUES

Many techniques of meniscopexy (suture and reinsertion of the meniscus) have been described. Absorbable or nonabsorbable stitches may be used, along with special absorbable implants of various types and makes. The strength of these various sutures differs. The strength of a well inserted double vertical PDS stitch No. 1 is 130 newtons; that of a simple vertical stitch, 80 N; while a horizontal mattress stitch holds 56 N. The strength of absorbable implants for suturing the meniscus is between 27–57 N. Typically, insertion of these implants in the posterior corner of the meniscus is easier than suturing. The strength of this fixation and the cost of the applied material differ extensively. (Tables 1, 2).

Here the authors present the basic techniques of suturing the meniscus using absorbable PDS stitches.

In essence, there are three basic techniques of suture of the meniscus:

The *outside-in* technique (insertion of the fibre from outside the joint inwards) using pink injection needles (12 x 40). It is possible to thread PDS monofilament fibre of maximal size 1, into the needle.

The simplest method is fixation of such threaded fibres by a knot inside the meniscus. The fibre is inserted through the working portal out of the joint, a knot is created at the end of the fibre, and the stitch is moved back (Mulberry stitch). After approximating the edges of the fissure, the two fibres are always knotted together outside of the joint capsule.

Knitting together two such threaded fibres on the intra-articular side is a little more difficult. Two needles with PDS stitches are threaded in by approximately 3 mm, both ends are threaded simultaneously through the working portal, the knot is tied and pushed into the joint again. Simultaneous threading is essential to prevent entrapment of synovial or other tissue between the particular fibres of the suture. This would impede cinching up the stitch to the meniscus. Fixation outside the joint capsule is done using the aforementioned technique.

Table 1

	MM alone	ML alone	+ primary LCA-plasty	+ early LCA-plasty	+ LCA reinsertion	total
MM suture	131		39	12	10	192
ML suture		35	9	4	2	50
rupture	7	0	0	0	1	8

Table 2

Lysholm score	Excellent	Good	Fair	Poor
Separate meniscus repair	88	8	4	0
Meniscus repair + LCA reconstruction	84	12	4	0

Other variants may be used to ensure the knot is on the meniscal rather than the intra-articular side:

3a) Threading a knot between two fibres is difficult, and the threaded fibre can furthermore break. In this case, a dilating knot on the threaded fibre can be used. This knot dilates the hole for the 2-fibre knot, and so its chance of breaking is smaller.

3b) The *threaded needle* technique is optimal, although a little more difficult than the above-mentioned methods. Two pink injection needles are used, threaded with PDS fibres of calibres No. 1 or 0. One of them goes past the tip of the needle, so that it can be circled around (approx. 10–15 cm), and thereby a noose for the fibre in the second needle is created. The end of the fibre in the second needle

is inserted into this noose so that it is completely hidden. The needle is passed into the noose in the required place and a noose is created in the joint. The second needle enters the noose for a distance of 3–4 mm. The noose is tightened, and this removes the fibre from the joint. It is suitable to thread several centimetres of the fibre (it can be performed also out of the joint with the aid of the working portal, but this is not necessary). In this manner, a “U” stitch is created without the intra-articular knot. Fixation is performed again by tying outside of the joint capsule. Of course, it is possible to change the direction of needle-threading, but the principle is the same. By this method, a fissure on the anterior three quarters of the meniscus can be sutured.

The *inside-out* technique (stitch placed on the meniscus directed outwards from the joint) Special instruments are needed for this technique. Double-lumen cannula suturing instruments of various forms and angulations enable optimal placing of sutures. It is however essential that there is no space between the two barrels (channels for both needles and stitches), but the space for threading the fibre loose (8-shaped on the cut). The needle for this type of suture is longer than the positioning cannula, with a sharp point, and with an eyehole at its end (a PDS stitch No. 1 can be used without problems). It most closely resembles needles ordinarily used for sewing. It is moreover flexible, so it can be threaded into angulated cannulas. Fixation of these stitches is also made by knotting outside the joint capsule. This technique is both simple and quick. It is applicable for the central two quarters of the meniscus, but the necessary instrumentation is required.

The *all-inside* technique (everything – including the insertion and knotting is inside the joint)

This technique is the most difficult. It is used for the posterior 1/4 to 1/3 of the meniscus. Again, special instruments and special working portals are necessary.

In the area of the posterior corner of the medial meniscus:

The fiberscope is inserted via an anterolateral (AL) portal through the intercondylar fossa along the cruciate ligaments. A posteromedial (PM) portal should be used as a working port. A threaded cannula with obturator, which is otherwise commonly used in shoulder joint surgery, is inserted through this portal. Placement of the stitch through a fissure in the posterior corner is done using two methods. When special instruments for suturing soft tissue with various shapes are available (Deschamps,...), the sewing instrument is inserted with the stitch in the joint. The stitch over the fissure of the meniscus is inserted and then the end is threaded through the cannula outwards, and the knot tightened up to the meniscus.

Should these instruments not be available, the needle for lumbar puncture can be used, as can puncture needles of greater calibre of a length of 15–20 cm. These needles are more robust than the usual injection needle. It is necessary to slightly bend the tip of the needle (the last 1 cm). This needle is inserted through an anteromedial (AM) portal under visual control, and the point of the needle passes through the fissure. With this method, there is a risk of accidentally inserting the needle into the popliteal area and thus neurovascular structure injury. For these reasons, the depth of insertion should be controlled both optically and mechanically. A firm instrument is inserted through the cannula which displaces the synovial membrane. In this way a space is formed so the needle can be pierced out of the meniscus safely. In this way, a channel is formed for freely moving the inserted needle. A suture is threaded through both the needle and the cannula outwards, and the needle is slowly removed from the joint. It is necessary to extract both ends of the inserted stitch out simultaneously through one working port, where good knotting of the stitch should be possible. No other tissue should be trapped between the fibres (i.e. synovial epithelium or subcutaneous tissue) that could hinder firm cinching of the knot. The stitch is then knotted using a stitcher.

In the posterior corner of the lateral meniscus:

The method is the same as on the medial side. In some cases it is possible to place the suture via AL access without introducing a posterolateral (PL) portal, especially when the knee is in the proper position (over 90° flexed, externally rotated, and in varus deviation). If this configuration is ineffective, the PL access is elected (similar to technique IIIa). Here, one must be careful to choose the right position of the portal to prevent possible injury of the fibular nerve.

The posterior corner of the lateral meniscus is more mobile from a physiological point of view, and so insertion of sutures is easier. It is necessary to heed the position of the popliteal muscle. Stitches

for an all-inside technique are inserted behind this ligament. In order to suture the popliteal muscle ligament, an outside-in or inside-out technique may be applied.

*Orientation of inserted stitches* is an important part of the meniscal suture as well. It is known that the structure of the meniscus is formed mostly by horizontally oriented fibrous tissue. Many scientific studies have proved that the best strength is achieved using stitches placed vertically. We believe that an oblique stitch is best, in that they are strong and they closely approximate the upper and lower margins of the meniscus to the joint capsule, thereby enabling favourable conditions for tissue healing.

The first stitch is usually inserted on the border of the third and the fourth quarter of the meniscus. In this way the meniscus is kept taut. After testing the required approximation by tightening the suture fibres, they are knotted outside the joint capsule in a step-by-step fashion. The subcutis should be well dissected to prevent injury to the sensory branch of the saphenous nerve, or suturing the subcutis to the joint capsule. Both eventualities cause postoperative complications (pains).

The postoperative regimen depends on the extent of injured and repaired meniscus, and also on the performed repair of other structures (ligaments, cartilage).

Generally, we recommend the following regimen after a well-performed suture: fixation by a rigid knee splint for 4 to 6 weeks. Passive movement (Continuous Passive Motion – motor splint) of the knee joint to a maximum of S 0–0–70° is performed on the second postoperative day. After regression of pain (between days 3 and 5), we enable patients with good compliance to walk in a rigid splint with instructions of pressing the body weight on the knee joint fixed in the splint only without rotation or flexion motions during load-bearing. Due in part to the shape of the joint surface and shape of the meniscus, compression occurs in the area of the rupture, but this has no negative impact on fissure healing. After 4–6 weeks motion to a range of S 0–0–100° is possible, and rehabilitation is accelerated via:

- stationary bicycle without loading; co-ordinated slow motion;
- swimming – only gentle motion in the sagittal axis; breaststroke and abrupt kicking are avoided;
- training of proper gait without splints, but with the help of crutches.

Six weeks postoperatively, after finishing rehabilitation, normal ambulation is possible. Continued rehabilitation should fortify the femoral muscles and train proprioception of motion.

The meniscal suture is regarded as completely healed after 3 months. The patients may return to their previous level of active lifestyle. Only genuflexion is limited for a further 3 months to allow remodelling of the scar tissue and strengthening and re-coordination of the femoral muscles.

## MATERIALS

Between 1994 and 2001 we performed 242 sutures of the meniscus following acute trauma. 192 were of the medial meniscus; 50 sutures on the lateral meniscus. Suture of both menisci was done in 7 patients. Patient's age ranged from 14–72 years, with the most frequent age interval being 18–32 years. The average age was 27 years. Right-sided injury was slightly more frequent (R 56%: L 44%).

Simultaneous ACL plastic surgery was performed in 48 patients; ACL reinsertion in 12; mosaicoplasty in 6. Early ACL plastic surgery (within 3 months of meniscal suture) was performed on 16 patients. The delay was due to a significant proliferation reaction in the joint perioperatively following irritation of the posttraumatic haemarthros and the related risk of postoperative arthrofibrosis.

## RESULTS

All patients healed without infectious complications. Twelve patients had symptoms of arthrofibrosis from 2nd to 5th weeks postoperatively and slower rehabilitation. Bicycle training was possible from 4th to 6th week in all patients. We did not observe clinically symptoms of rerupture or unhealed meniscus until 6 months postoperatively.

The range of motion was full in 92 % of patients with separate meniscus suture in 6 months postoperatively. In 8 % of the patients the range of motion was S 0-0-130, no stretch or flexion limitation. In patients with other contemporary operations the full range of motion was in 84 %, and S 0-0-130 in 16 %.

We could see healed tissue of sutured meniscus in patients with early LCA plastic surgery 3-4 months after meniscus suture.

All patients were observed only clinically, no MRI or sonography investigation, return to the previous style of living was in 88 % of patients with separate meniscus repair and in 82 % with contemporary LCA repair.

Rerupture of the meniscus occurred in 8 cases (only the medial meniscus was involved), with symptoms of haemarthros. This always followed a new injury, and was resolved by meniscectomy in 6 cases and resuture in 2. The first symptoms of rerupture were in 9 months postoperatively, with new injury in running. Reruptures were in 6 cases with separate meniscus suture and in 2 with LCA plastic surgery.

Lysholm score was little different in patients with separate meniscus suture and in patients with other contemporary operations 1 year post operation. Excellent and good results were in 96 % in both groups, but the excellent ones were higher in separate meniscus suture, so it could be an influence of LCA plastic surgery for different results.

## DISCUSSION

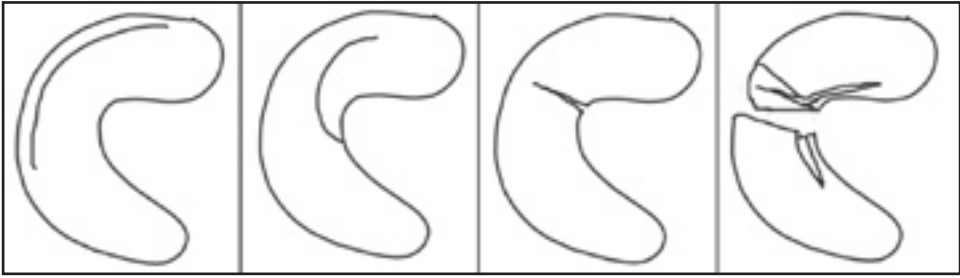
Preservation of the meniscus via its suturing is essential for knee joint function. It allows continued optimal movement of the joint after injury and a return to the original, pre-traumatic state. Not every injury of the meniscus can be repaired, and not every sutured meniscus will heal (the factors involved are vascular nutrition, postoperative regimen, knee joint stability, technique of suture performed, etc.) (3, 9, 13, 14).

Postoperative rehabilitation after meniscal repair certainly takes longer than after meniscectomy. Some patients may disagree with this reality, and for various reasons (work, sports) may prefer removal of the damaged tissue with the prospect of a quicker return to their usual work and sport activities (2).

The results of meniscus sutures show, however, that the percentage of healed tears in patients is high. Short-term and mid-term results are promising. Patients are able to fully bear down on the knee joints and, in some cases, they are problem-free. Some of our patients were professional athletes and all returned to their original level of activity.

Pain in the area of PDS stitching of the subcutaneous tissue was present in some of the patients. This pain mostly regressed within 3 months postoperatively. We speculate that this regression occurs with suture absorption. We were compelled to remove a small fibroma in the subcutaneous tissue in only one patient. This was done under local anaesthesia and was caused by the knotting of the PDS stitch.





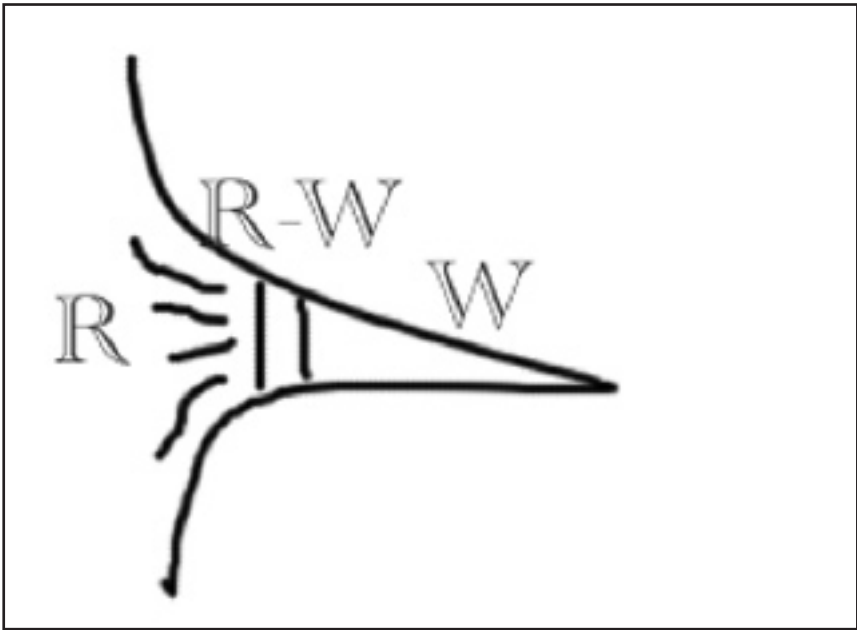
Longitudinal  
vertical

oblique

radial

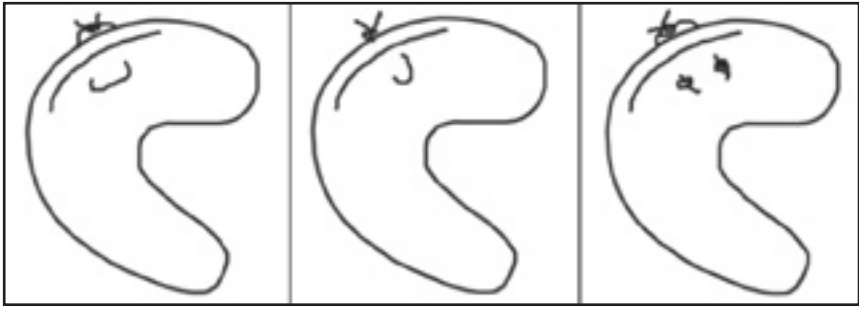
horizontal

*Fig. 1*  
Basic types of meniscus rupture



*Fig. 2*  
Meniscus zone according to blood supply (red, red-white, white)





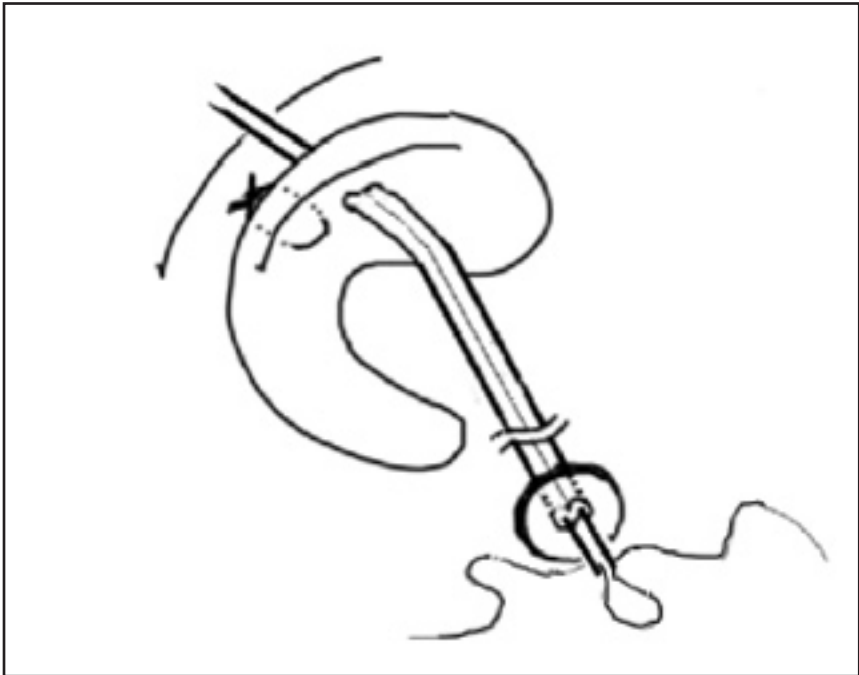
a)

b)

c)

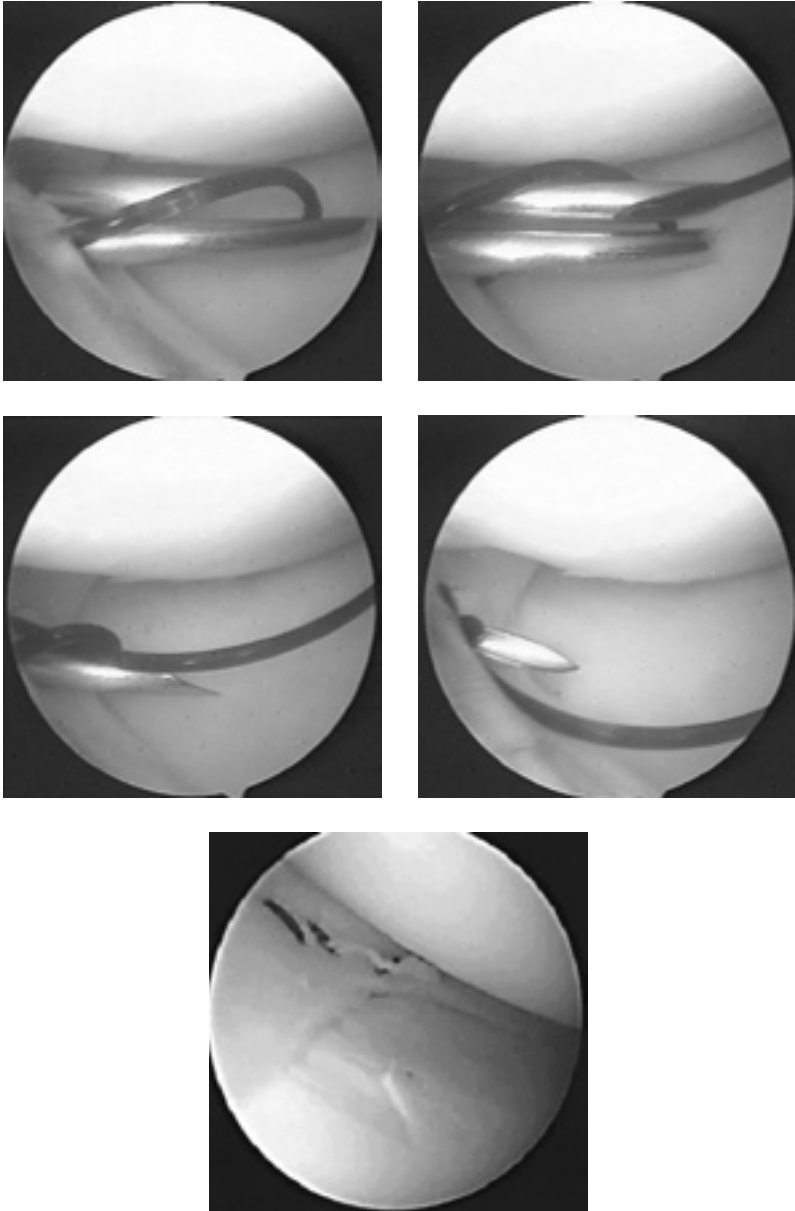
*Fig. 3*

Possibilities of stitch applications in outside-in and inside-out techniques  
 a - horizontal stitch, b - vertical stitch, c - mulberry stitch (knots in the joint)

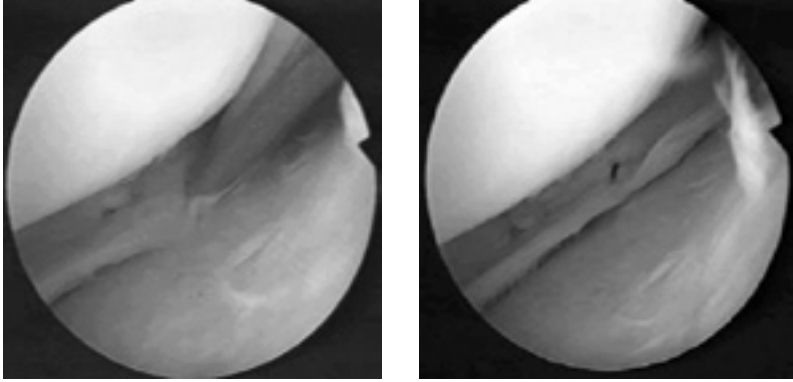


*Fig. 4*

Technique of application of INSIDE-OUT stitches with special double-hole instrumentarium

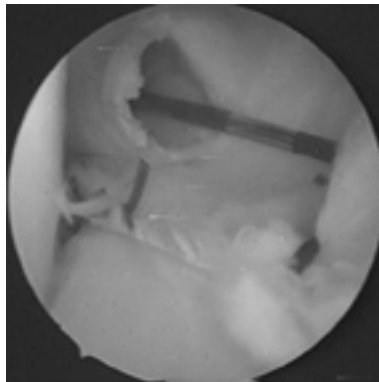


*Fig. 5*  
Meniscus suture technique OUTSIDE-IN, with 2 syringe needle  
1,2 x 40 (pink needle) and PDS stitches No. 1 or 0.



*Fig. 6*

Arthroscopis view on aplication stitches with INSIDE-OUT technique



*Fig. 7*

PDS stitches in posterior horn of medial meniscus with ALL-INSIDE technique,  
across posteromedial port

It is impossible to verify the quality of healed sutures in all patients. The only indication is the clinical state of the patient. Arthroscopy was performed only in patients with delayed ACL plastic surgery. Three months after suturing, the tissue appeared well-healed by fibrous tissue, and only exceptionally was it possible to insert probes into the original fissure (in some cases the fissure was conspicuous as an unevenness on the superior facet of the meniscus). The meniscus was, however, stable when tested by gentle tagging. Published literature accords a significantly better healing of the meniscus after its reinsertion with simultaneous ACL plastic surgery (92–94 % healing with ACL plastic surgery versus 67 % healing in cases with an ACL-deficient joint) (3,9). Follow-up MRI was not performed. In previous studies, MRI demonstrated complete healing in 45 % of cases after the outside-in technique; partial healing in 31 %; and only poor or no healing in the posterior corner in 24 % (12). Clinical assessment revealed healing in 87 % of patients over 40 years (4). Placing the stitches along the entire length of the rupture significantly lowers the percentage of failure than by inserting some approximating stitches. Based on our experience, sutures are best when placed at a maximum distance of 8 mm between each other. When the tissues are in contact along the entire length of the fissure, conditions for tissue healing are optimal.

The authors describe a technique for suturing the injured meniscus using absorbable PDS stitches. Fixation via absorbable implants is not presented in the study. The authors prefer the aforementioned suture techniques principally for a better stability of the suture, and also for economical reasons. It is certainly advantageous to use a combination of stitches in the anterior 3/4 of the meniscus, and absorbable implants in its posterior 1/4, especially for the relatively difficult application of the all-inside technique (*Tabs. 1a, 2b*).

The percentage of re-rupture of the meniscus was very low in our patients (3.3 %). This assessment was made based only on subjective complaints and clinical examinations. In total, information on about 67 % of patients has been collected. Our short-term and mid-term results are encouraging. We are unable, however, to evaluate the long-term results from both a clinical and radiodiagnostic point of view.

#### CONCLUSION

It is hoped that by improving the biomechanics of the knee joint one can eliminate or at least delay possible degeneration of the knee joint and enable a fuller post-traumatic quality of life in our patients for longer time than after meniscectomy. For these reasons we will follow-up our patients to compare the results of meniscal sutures and of meniscectomies after a longer time period.

Table 1a

Suture strength: Vertical mattress suture	2-0 Ethibond	89.3 ± 23.8 N
	0-PDS	115.9 ± 28.5 N
	1-PDS	146.3 ± 17.1 N
Horizontal mattress suture	2-0 Ethibond	59.7 ± 20.4 N
	0-PDS	66.1 ± 28.7 N
	1-PDS	73.8 ± 31.3 N
Mulberry suture	0-PDS	68.6 ± 13.7 N
	1-PDS	69.3 ± 11.4 N

According to: Post W.P, Avers S.R., Kish V.: Load to failure of common meniscal repair techniques: effects of suture technique and suture material. *Arthroscopy: The Journal of Arthroscopic and Related Surgery*, 13; 6., pp. 731-736, 1997

Table 2b

Biomet staple	26.97 ± 8.28
Mitek meniscal repair system	30.09 ± 7.91
SDsorb 10 mm staple	31.43 ± 13.7
Clearfix screw	32.52 ± 10.94
Meniscus arrow (hand insertion)	33.41 ± 8.37
Meniscus arrow (crossbow)	33.64 ± 12.89
T-fix	50.38 ± 15.45
Horizontal mattress suture	55.87 ± 18.80
BioStinger	56.60 ± 28.0
Simple vertical stitch	80.43 ± 8.49

According to: Barber F.A., Herbert M.A.: Meniscal repair device. *Arthroscopy: The Journal of Arthroscopic and Related Surgery*, 16; 6: pp. 613-618, 2000

## SUTURA MENISKU

### S o u h r n

Autoři předkládají své zkušenosti s arthroscopicky prováděnou suturou poraněných menisků.

Poranění menisků je jedno z nejčastějších úrazových postižení kolenních kloubů, řešené většinou odstraněním poraněné části menisku – meniskektomií. Po těchto operacích však dochází v průběhu času k přetížení a opotřeбенí příslušného kompartmentu, s následnými příznaky artrotických změn. V důsledku tohoto procesu se výrazně zvyšuje nemocnost pacientů, přes zvýšenou spotřebu léků, až po implantaci totální endoprotézy.

S nástupem arthroscopické techniky v 80. letech se začaly provádět meniskektomie šetrněji, se snahou zachovat neporaněnou část menisku. Přetížení v příslušném kompartmentu je pak menší a chrupavka je více chráněná.

S vývojem arthroscopie, především přehlednosti v kloubu, a s novými znalostmi biomechaniky kolenních kloubů se objevily snahy o zachování menisků. Autoři popisují možnosti arthroscopicky prováděné sutury poraněných menisků.

Pro zachování menisku je důležitých několik faktorů. Typ ruptury, lokalizace poranění (red-red, red-white zóna), doba od poranění, stabilita kloubu a celkové biomechanické stáří kloubu. Autoři popisují 3 základní techniky sutury menisků: outside-in, inside-out a all-inside. Používají PDS stehy č. 0 a 1. Stehy jsou aplikovány pod arthroscopickou kontrolou. V případě nestability kolenního kloubu je vhodné provést současnou reparaci vazů, popřípadě chrupavky. V pooperačním režimu používají fixaci rigidní ortezou, s časnou rehabilitací v limitovaném pohybu i zátěži. Normální chůzi doporučují od 7. týdne po operaci, postupné sportovní zatížení (vyklusávání) po 3 měsících od operace.

V letech 1994–2001 provedli autoři celkem 242 sutury menisku, 192 mediální, 50 laterální, 7x současně oba menisky u 1 kolene, ve věku pacienta 14–72 let. Reruptura menisku byla pozorována v 8 případech (jen mediální meniskus), vždy novým úrazem, řešena byla 6x meniskektomií, 2x resuturou. Současná plastika LCA byla ve 48 případech, reinzerce LCA 12x, mozaiková plastika 6x, Časná plastika LCA (do 3 měsíců od sutury menisku) byla 16x.

Zachování poraněného menisku je velmi důležité převážně z důvodů jeho biomechanických vlastností. Současné, popřípadě následně časné ošetření nestability kloubu reparací vazů je plně indikováno. Jen tak lze obnovit správnou biomechaniku kolenního kloubu. Střednědobé výsledky ukazují na dobré a velmi dobré výsledky těchto zachovných operací.

Arthroscopicky prováděné sutury čerstvě poraněných menisků v prokrvené zóně (red-red, red-white) vykazují dobré možnosti vhojení tkáně a umožní obnovení správné biomechaniky kloubu.

### REFERENCES

1. *Arnoczky SP.* Gross and vascular anatomy of the meniscus and its role in meniscal healing, regeneration and remodelling. In: MOW V.C., ARNO CZKY S.P., JACKSON DW: Knee meniscus: basic science and clinical foundation, New York: Raven Press, 1992, 177–190.
2. *Barber FA, Click SD.* Meniscus repair rehabilitation with current anterior cruciate reconstruction. Arthroscopy: The Journal of Arthroscopic and Related Surgery, 13: 1997, 433–437.
3. *Barber FA, Herbert MA.* Meniscal repair device. Arthroscopy: The Journal of Arthroscopic and Related Surgery, 16: 6: 2000, 613–618.
4. *Barret GR, Field MH, Treacy SH, Tiff CG.* Clinical results of meniscus repair in patients 40 years and older. Arthroscopy: The Journal of Arthroscopic and Related Surgery; 14: 1998, 824–829.
5. *Cannon WD.* Arthroscopic meniscal repair. In: MCGINTY JB: Operative arthroscopy, 3rd edition, Lippincott Williams Wilkins; 2002, 233–250.
6. *Drápal V.* Arthroscopická meniskopexie [Arthroscopic meniscopexy]. Acta Chir.orthop. Traum. Česosl.; 60: 1993, 96–99.
7. *Henning CE.* Arthroscopic repair of meniscus tears. Orthopedics; 6: 1983, 1130–1132.

8. *Jones HP, Lemos MJ, Wilk RM, Smiley PM et al.* Two-year follow-up of meniscal repair using a bioabsorbable arrow. *Arthroscopy: The Journal of Arthroscopic and Related Surgery*; 18: 2002, 64-69.
9. *Klimkiewicz JJ, Shaffer B.* Meniscal surgery 2002 update: indications and techniques for resection, repair, regeneration and replacement. *Arthroscopy. The Journal of Arthroscopic and Related Surgery*; 18: 2002, 14-25.
10. *Lo Ian KV, Thornton G, Miniaci A et al.* Basic science. Meniscus. In: MCGINTY JB: *Operative arthroscopy*, 3rd edition, Lippincott Williams Wilkins; 2002, 94-102.
11. *Notes FR, Barber-Westin SD.* Arthroscopic repair of meniscus tears extending into the avascular zone with or without anterior ligament reconstruction in patients 40 years of age older. *Arthroscopy: The Journal of Arthroscopic and Related Surgery*; 16: 2000, 822-829.
12. *Post WP, Avers SR., Kish V.* Load to failure of common meniscal repair techniques: Effects of suture technique and suture material. *Arthroscopy: The Journal of Arthroscopic and Related Surgery*; 13: 1997, 731-736.
13. *Rockborn P, Gillquist J.* Results of open meniscus repair. *J. Bone Jt. Surg.*; 82-B: 2000, 494-498.
14. *Rodeo SA.* Arthroscopic meniscal repair with use of the outside-in technique. *J. Bone Jt. Surg.*; 82-A.; 2000, 127-141.
15. *Seil R, Rupp S, Kohn DM.* Cyclic testing of meniscal sutures. *Arthroscopy: The Journal of Arthroscopic and Related Surgery*; 16: 505-510, 2000.
16. *Van Trommel MF, Simonian PT, Potter HG, Wickiewicz TL.* Arthroscopic meniscal repair with fibrin clot of complete radial tears of the lateral meniscus in the avascular zone. *Arthroscopy: The Journal of Arthroscopic and Related Surgery*; 14: 360-365, 1998.



