

## ANALYSIS OF THE CAUSES OF FAILURE OF THE SURGICAL - ORTHODONTIC TREATMENT OF IMPACTED PERMANENT UPPER CANINES - CT STUDY

ČERNOCHOVÁ P.<sup>1</sup>, KRUPA P.<sup>2</sup>

<sup>1</sup>Department of Stomatology and <sup>2</sup>Department of Radiodiagnostic Imaging, St. Anne's Teaching Hospital, Faculty of Medicine, Masaryk University, Brno

*Received after revision July 2005*

### Abstract

The surgical-orthodontic treatment of impacted canines is one of the options of their treatment. The objective of this way of treatment is repositioning of the impacted canine after its surgical exposure to its place in the dental arch by the orthodontic traction. It is demanding for the interdisciplinary cooperation of the orthodontist and the dentoalveolar surgeon and cooperation of the patient. An important role in the whole process plays the diagnostics of the position and the morphology of the impacted canine. In some cases there are complications in the course of the orthodontic traction of the impacted canine into the dental arch. This article describes 9 cases, in which complications occurred. These 9 patients underwent CT (computed tomography) scanning, based on which changes were made in the subsequent treatment. The causes of failure of the otherwise reliable surgical-orthodontic treatment of impacted permanent upper canines are still being analyzed.

### Key words

Impacted canine, Computed tomography, Surgical-orthodontic treatment

### INTRODUCTION

One of the options of treatment of an impacted permanent canine is the surgical-orthodontic procedure. The procedure has the following stages:

Orthodontic pre-surgical stage - placement molar bands and the palatal arch to modify the position of the upper molars (if necessary), and particularly for anchorage. A part of this stage can be (but not necessarily) applying the complete fixed orthodontic appliance in the upper dental arch, alignment and opening a space for traction of the canine.

Surgical stage - exposure of the crown of the impacted canine so that attachment could be bonded to it (orthodontic bracket, eyelet, etc.) that will enable application of the active orthodontic force moving the affected canine to its place in the dental arch.

Orthodontic post-surgical stage – repositioning the canine by the active orthodontic force to the dental arch. In this stage at the latest, orthodontic brackets have to be attached to the teeth in the upper dental arch and opened sufficient space for traction of the canine.

Problems with traction of the canine occur during the third – orthodontic stage. The problems are that the canine does not move in the direction of the applied orthodontic force. The objective of the presented study is to analyze, using the CT scanning, the real causes of failure of the surgical-orthodontic treatment of impacted permanent canines.

#### MATERIALS AND METHODS

Nine patients, 2 males and 7 females aged 15 to 35 years with impacted permanent upper canine came to the Department of Orthodontics of the Department of Stomatology, Faculty of Medicine and the St. Anne's Teaching Hospital in Brno to consult further treatment. Patients were treated by the fixed orthodontic appliance by various orthodontists. They had exposed impacted permanent upper canine and applied orthodontic force moving the canine to the dental arch. Yet, the canines did not respond to the force by the required movement for more than 5 months. The patients underwent CT scanning at the Department of Radiodiagnostic Imaging. The CT scanning was made by the spiral CT scanner Marconi Mx8000 with the matrix size of 768x768. Other scan parameters were: pitch 0.875, 120 kV, 100 mAs. The bone algorithm was applied for high resolution and window setting was approximately 2000 Hounsfield units (HU) with the central value of 400 HU. Contiguous axial CT scans of the alveolar bone of maxilla were taken in a plane parallel to the level of occlusion or to the palate with the slice thickness of 1.3 mm and increment of 0.6 mm. At the satellite console we analyzed individual axial scans and using three-dimensional rendering software we created multiplanar (MPR) and 3D reconstructions (shaded surface display – SSD and volume rendering).

#### RESULTS

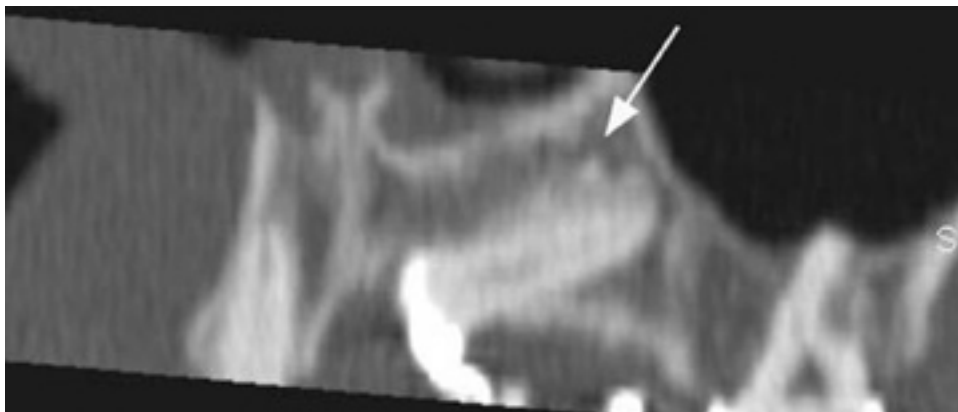
In 9 patients of the analyzed group, the following causes of failure of the surgical-orthodontic treatment of impacted permanent upper canines were indicated using the CT scanning.

First patient – male, 24 years

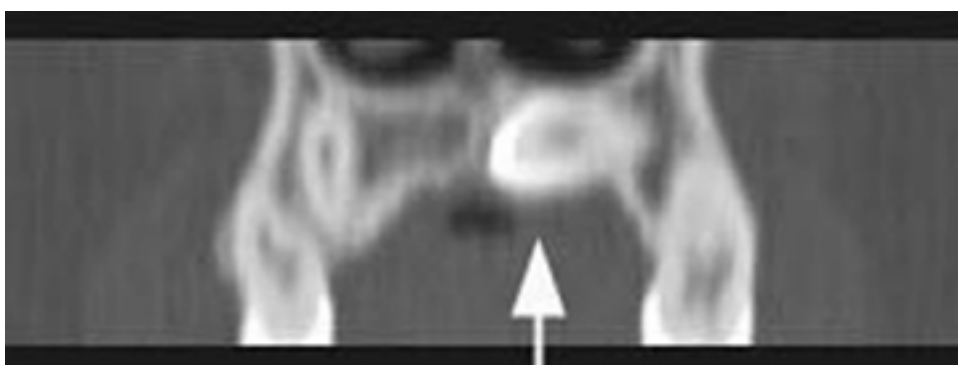
The cause of the failure was the ankylosis of the root of the impacted canine. *Fig. 1* shows the multiplanar reconstruction (MPR) in the plane going through the long axis of the impacted canine. At the surface of the canine in the cranial direction towards the nasal sinus there is a structure in the central and apical third, whose density is close to the density of the compact bone and which can be considered as ankylosis. The affected canine had to be extracted. The presence of ankylosis and its location were confirmed during surgical extraction.

Second patient – female, 33 years

The cause of failure of the orthodontic movement of the impacted canine was its unsuitable position. It was located horizontally in the palatal process of maxilla where it was surrounded only by compact bone and no spongiosis. Therefore it did not have sufficient space to move in (*Fig. 2*). The canine was extracted. Surgical



*Fig. 1*  
Multiplanar reconstruction (MPR) in the plane going through the long axis of the impacted canine (arrow shows location of ankylosis)

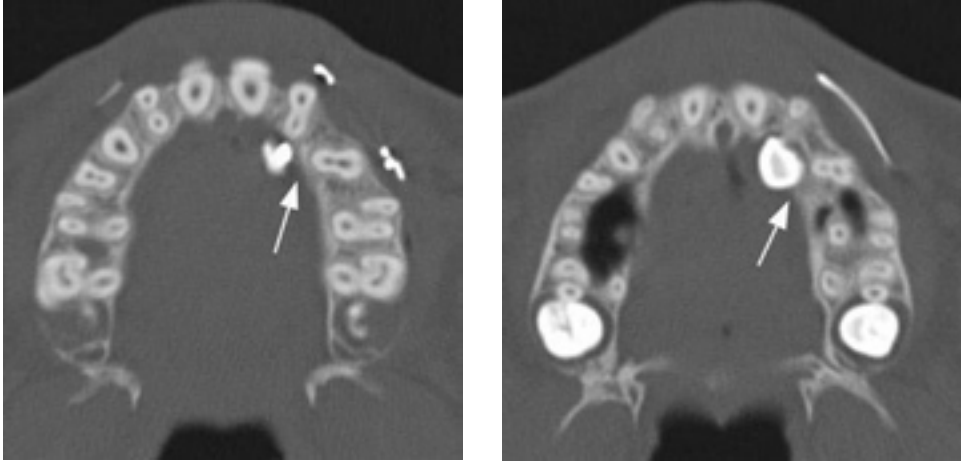


*Fig. 2*  
Multiplanar reconstruction (MPR) in the transversal plane - the impacted canine is located horizontally in the palatal process of the maxilla (arrow)

findings excluded ankylosis and confirmed blocking of the canine in the palatal process of maxilla.

Third patient - female, 18 years

CT scans showed collision of the crown by the orthodontically moved canine and roots of the adjacent premolars. At *Fig. 3a* and *3b* it is obvious that during opening of the space for the left impacted transposed canine, both premolars were rotated. The first premolar rotated mesially and the second premolar distally, by which the place necessary for alignment of the canine into the arch was closed. After removal



*Figs. 3a, 3b*

Axial CT scans of maxilla - the crown of the impacted canine is in collision with roots of rotated premolars (arrow)

of the collision by uprighting of roots and de-rotation of the adjacent premolars, the canine was successfully moved to the arch.

Fourth patient - male, 17 years

By CT scanning, collision of the crown of the impacted canine with roots of the adjacent teeth was diagnosed. Again, fixed orthodontic appliance was applied to the patient and the canine moved to its place in the arch.

Fifth patient - female, 32 years

CT scanning revealed periapical granuloma around the root of the exposed canine communicating with the nasal sinus. Also a bone defect was found in the direction of the required movement of the canine and extensive external resorption of the canine (*Fig. 4a to 4d*). The affected canine was extracted. During extraction, presence of the periapical granuloma was confirmed as well as the granulation tissue which was filling the bone defect and obstructed the orthodontic movement of the tooth.

Sixth patient - female, 21 years

At *Fig. 5a to 5c* it is apparent that the crown of the impacted canine is in collision with a shortened palatal root of the first premolar. The cause of failure was the unsuitable palatal access for exposure of the crown and unsuitable direction of the orthodontic force moving the canine (disto-occlusal direction of the force towards the palatal arch). We recommended the following change in the treatment - interruption of moving the canine to the palatal arch, placement fixed orthodontic appliance to the upper dental arch, opening space for the impacted canine together with de-rotation of the first premolar, extraction of the temporary canine, vestibular exposure

of the crown of the impacted canine, occlusal orthodontic force to the canine. After making the changes, movement of the canine was successfully completed.

Seventh patient - female, 35 years

The reason of the failure was the horizontal position of the canine between the walls of the palatal process of maxilla. The canine had to be extracted. (Similar situation as in the case of the second patient)

Eighth patient - female, 15 years

Based on the CT scanning, insufficient space for movement of the canine was diagnosed in connection with distal rotation of the first premolar. After opening sufficient space, the canine was aligned.

Ninth patient - female, 34 years

CT scanning showed malformation of the root of the lateral incisor which was the obstacle in the movement of the canine (*Fig. 6a* and *6b*). Extraction of the lateral incisor enabled moving the canine to the arch.

The analysis of causes of failure of the orthodontic movement of impacted canines with regards to further treatment:

In 4 patients the problems were caused by reasons leading to extraction of a canine. These reasons included:

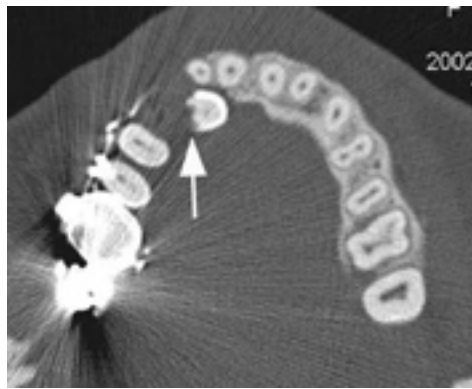
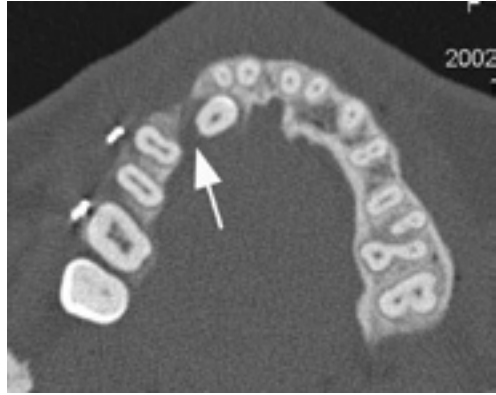
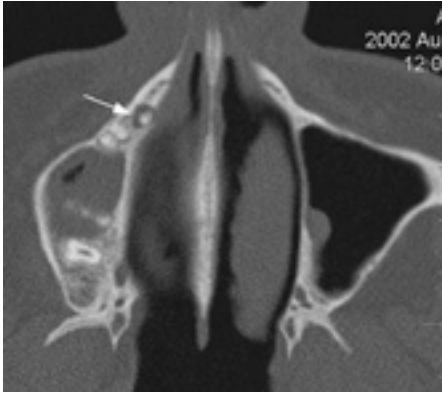
- ankylosis
- unsuitable position of an impacted canine in the palatal process of maxilla (in two cases)
- inflammation with the granulation tissue and with external resorption of the crown of the canine and presence of periapical granuloma.

In 5 patients the reason were conditions that could be influenced by further treatment, the impacted canine did not have to be extracted:

- collision of the crown of the impacted canine with roots of the adjacent teeth, or insufficient space for orthodontic movement of the canine (in three cases)
- unsuitable procedure of the surgical exposure and unsuitable direction of the applied orthodontic force moving the canine
- malformation of the shape of the root of the lateral incisor as an obstacle

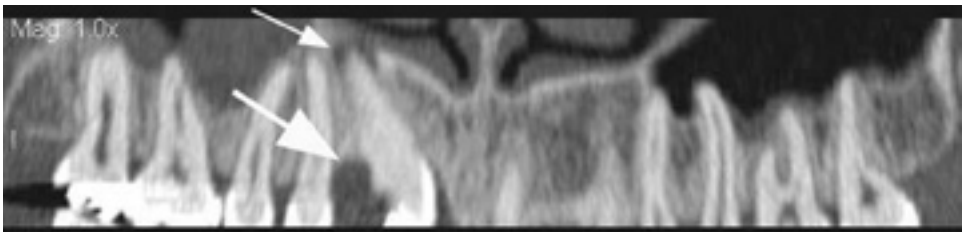
## DISCUSSION

Surgical-orthodontic treatment of impacted permanent upper canines is not without risks. One of the risks is failure to complete treatment, i.e. non-alignment of the impacted canine in the dental arch (*1*). As the most common reason is the unsuitable position of the impacted canine. McSherry (*2*) states that the more apically, horizontally and distally the canine is located, the worse is the prognosis of its moving to the right position. The unsuitable position was the cause of failure in two patients from our group whose cuspid was located horizontally in the palatal process of maxilla. As the other factor leading to failure of the orthodontic treatment is ankylosis of the root of the impacted canine (*1, 3, 4, 5, 6, 7*). In our study there was



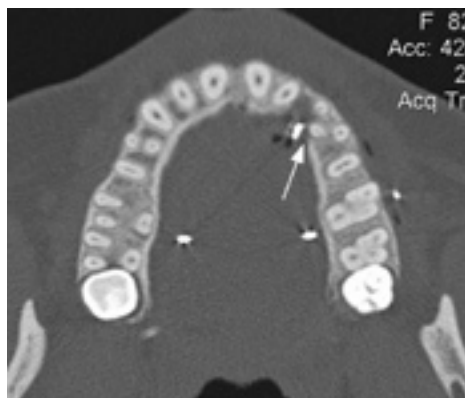*Figs. 4a to 4c*

Axial CT scans of maxilla - periapical granuloma of the impacted canine (thin arrow), bone defect in the surroundings and external resorption of the impacted canine (thick arrow)



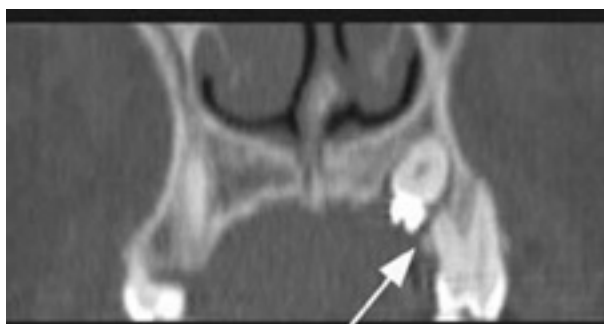*Fig. 4d*

Multiplanar reconstruction (MPR) - right impacted canine with periapical granuloma communicating with the nasal sinus (thin arrow), and with the bone defect and resorption of enamel and dentin of the cervical part of the canine (thick arrow)



*Fig. 5a*

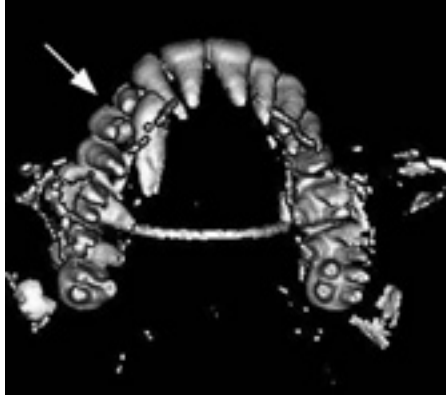Axial CT scans of maxilla - the crown of the impacted canine is in collision with the palatal root of the first premolar (arrow)



*Fig. 5b*

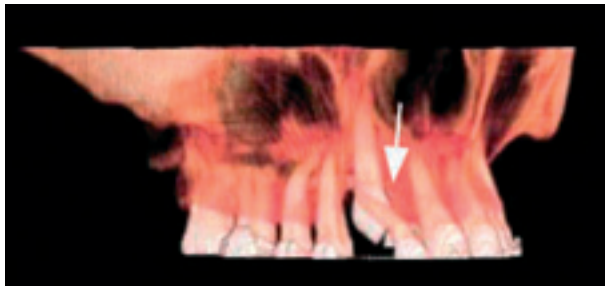
Multiplanar reconstruction (MPR) in the transversal plane - the crown of the impacted canine is in collision with the shortened palatal root of the first premolar (arrow)

one patient with ankylosis. Another factor which caused extraction of the impacted canine of one patient was inflammation with creation of the granulation tissue and with external resorption of the crown of the canine and presence of the periapical granuloma. In the literature known to us we have not come across any similar complication in treatment of the impacted permanent upper canines. The cause of inflammation and the external resorption which were not present at the X-ray image before initiation of treatment is not clear. We can only guess that inflammation could be caused by indelicate surgical intervention and subsequent complicated healing, or that the periapical granuloma is of the nasal origin. In 5 patients the causes of problems with repositioning of the impacted canines were the conditions



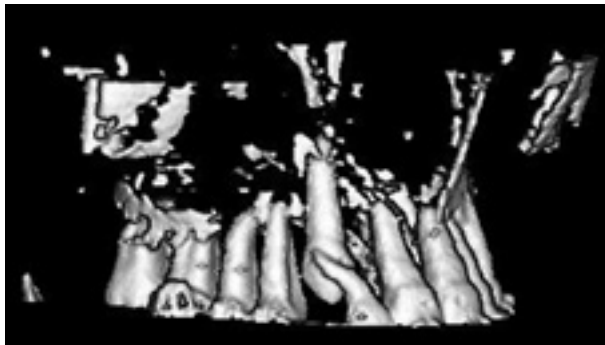
*Fig. 5c*

3D reconstruction (shaded surface display) - craniocaudal view (arrow shows the relationship between the impacted canine, temporary canine, and first premolar)



*Fig. 6a*

3D reconstruction (volume rendering) - lateral view



*Fig. 6b*

3D reconstruction (shaded surface display) - lateral view - the crown of the impacted canine is in collision with the deviated root of the lateral incisor (arrow)



that could be influenced an adequate change in further treatment. In three patients the cause was collision of the crown of the impacted canine with roots of the adjacent teeth, or insufficient space for orthodontic movement of the canine. In one case, unsuitable procedure of the surgical exposure was applied as well as unsuitable direction of the orthodontic force moving the canine which was caused by insufficient diagnostics of the position of the impacted canine. Malformation of roots of teeth surrounding the impacted canine can cause problems in its orthodontic movement. In literature (8), deviations of the palatal root of the first premolar are described. In one patient from our group there was deviation of the root of a lateral incisor. In order to complete orthodontic repositioning of the impacted canine, the affected lateral incisor had to be extracted regarding the extent of deviation.

The cases when problems occur during the orthodontic movement of the impacted canine into the dental arch, i.e. the canine does not react to the applied force and does not move to any direction, often embarrass the attending orthodontist. The orthodontists wonder where there was a mistake in their treatment which is most often successful. Then they come to some conclusions which as a result lead to some change in the treatment (e.g. a change of the direction or the intensity of the applied force, reinforcing of the anchorage segment, opening bigger space for movement of the canine, etc.) If such a change has a positive effect, it depends on the fact whether the change eliminates the real cause of the problem. For this it is necessary to recognize the real cause. For its diagnostics, mere clinical examination and X-ray documentation made before treatment is seldom sufficient. In many cases it is necessary to make another X-ray image. For this purpose, a method should be selected with the most beneficial diagnostic effect. The method should provide the possibility of exclusion or confirmation of the presence of ankylosis or other obstacles hindering the orthodontic movement of the canine. These requirements are fulfilled by the computed tomography (CT) (9) which displays maxilla in the cross section and thus enables to see its internal structure. Moreover, CT provides the possibility of creating the three-dimensional reconstruction. These are very useful in diagnostics of the problematic conditions because they make it possible to think in space about direction of a canine during its orthodontic movement.

Making a supplementary diagnostics and effective changes in the treatment should not be prolonged. Otherwise the treatment becomes too long and expensive. If the impacted canine does not respond to the applied orthodontic force for 3 months, supplementary diagnostics should be made.

#### CONCLUSIONS

Failure of the surgical-orthodontic treatment of impacted permanent upper canines can be caused by a range of factors. The computed tomography (CT) and particularly the three-dimensional computed tomography have been found to be a very effective method for diagnostics of causes of these failures. Our study shows

that not in all cases extraction of an impacted canine is necessary even if it does not respond in demand way to the orthodontic traction.

*Černochová P., Krupa P.*

## ANALÝZA PŘÍČIN NEÚSPĚCHU CHIRURGICKO - ORTODONTICKÉ LÉČBY RETINOVANÝCH HORNÍCH STÁLÝCH ŠPIČÁKŮ - CT STUDIE

### S o u h r n

Chirurgicko-ortodontická léčba retinovaných horních stálých špičáků je jednou z možností jejich léčby. Cílem tohoto způsobu léčby je zařazení retinovaného špičáku po jeho chirurgické expozici na své místo v zubním oblouku ortodontickou trakcí. Je náročná na interdisciplinární spolupráci ortodontisty a dentoalveolárního chirurga a na spolupráci pacienta. Důležitou úlohu v celém postupu má diagnostika polohy a morfologie retinovaného špičáku. V některých případech dochází ke komplikacím v průběhu ortodontického zařazování retinovaného špičáku do zubního oblouku. Tento článek popisuje 9 případů, u kterých se tyto komplikace vyskytly. Těchto 9 pacientů podstoupilo CT vyšetření, na základě kterého byly provedeny změny v dalším léčebném postupu. Příčiny selhání jinak spolehlivé chirurgicko-ortodontické léčby retinovaných horních stálých špičáků jsou analyzovány.

### REFERENCES

1. *McSherry PF*. The Ectopic Maxillary Canine: A Review. *Br J Orthod*. 1998; 25:209-216.
2. *McSherry PF*. The assessment of and treatment options for the buried maxillary canine. *Dent Update* 1996; 23: 7-10.
3. *Becker A*. The Orthodontic Treatment of Impacted Teeth. London: Martin Dunitz Ltd, 1998: 29, 35pp.
4. *Kurol J, Ericson S, Andreasen JO*. The impacted maxillary canine. In: *Andreasen JO, Petersen JK, Laskin DM*, eds. Textbook and Color Atlas of Tooth Impactions. 1st ed Copenhagen: Munksgaard, 1997: 150.
5. *Bishara SE*. Clinical Management of Impacted Maxillary Canines. *Semin Orthod*. 1998; 4:87-98.
6. *Proffit WR, Fields HW*. Contemporary Orthodontics. 3rd ed. St Louis: Mosby; 1999: 541pp.
7. *Vanarsdall RL*. Periodontal/Orthodontic interrelationships. In: *Graber TM, Vanarsdall RL*, eds: Orthodontics: Current Principles and Techniques. 3rd ed. St Louis: Mosby; 2000: 829-836.
8. *Chate RAC*. Maxillary canine displacement; further twists in the tale. *Eur J Orthod*. 2003; 25:43-47.
9. *Elefteriadis JN, Athanasiou AE*. Evaluation of impacted canines by means of computerized tomography. *Int J Adult Orthod Orthognath Surg*. 1996; 11:257-264.